



Treatment of temporomandibular joint luxation: a systematic literature review

Helene Abrahamsson¹ · Lars Eriksson² · Peter Abrahamsson³ · Birgitta Häggman-Henrikson^{1,4} 

Received: 20 November 2018 / Accepted: 16 October 2019 / Published online: 15 November 2019
© The Author(s) 2019

Abstract

Objectives To evaluate the effectiveness of surgical and nonsurgical treatment of temporomandibular joint (TMJ) luxation.

Materials and methods This systematic literature review searched PubMed, the Cochrane Library, and Web of Science databases to identify randomized controlled trials on TMJ luxation treatment published between the inception of each database and 26 March 2018.

Results Two authors assessed 113 unique abstracts according to the inclusion criteria and read nine articles in full text. Eight articles comprising 338 patients met the inclusion criteria, but none of these evaluated surgical techniques. Three studies including 185 patients concerned acute treatment with manual reduction of luxation while five studies including 153 patients evaluated minimally invasive methods with injection of autologous blood or dextrose prolotherapy for recurrent TMJ luxation. These studies reported that mouth opening after treatment was reduced and that independent of type of injection, recurrences of TMJ luxation were rare in most patients.

Conclusions In the absence of randomized studies on surgical techniques, autologous blood injection in the superior joint space and pericapsular tissues with intermaxillary fixation seems to be the treatment for recurrent TMJ luxation that at present has the best scientific support. Well-designed studies on surgical techniques with sufficient numbers of patients, long-term follow-ups, and patient experience assessment are needed for selection of the optimal surgical treatment methods.

Clinical relevance Autologous blood injection combined with intermaxillary fixation can be recommended for patients with recurrence of TMJ luxation.

Keywords Hypermobility · Luxation · Prolotherapy · TMJ dislocation · TMJ reduction

Introduction

Temporomandibular joint (TMJ) luxation (dislocation) is rare, but when it occurs, it has a high impact on the individual and usually requires urgent medical attention. In the acute stage, TMJ luxation severely affects oral health due to the severity of the pain or discomfort and the reduced ability to speak, chew,

and eat [1]. Furthermore, psychological and social impact are high and TMJ luxation can therefore be regarded as one of the most severe conditions in dentistry [2].

TMJ hypermobility can be classified as a subluxation or a luxation. TMJ subluxation is a condition where the condyle translates anteriorly of the articular eminence during jaw opening and briefly catches in an open position before returning to the fossa spontaneously [3] or with manual self-manipulation by the patient. The Research Diagnostic Criteria for Temporomandibular Disorders (RDC/TMD) classification scheme [4] was expanded in 2014 to include less common, but clinically important disorders. According to these, the Diagnostic Criteria for Temporomandibular Disorders (DC/TMD), subluxation should have a positive history that the jaw has been caught in a wide open position and the patient had to do a self-maneuver to be able to close the jaw [5]. During TMJ luxation, the patient is unable to self return to the fossa without the help of a clinician to maneuver the jaw

✉ Birgitta Häggman-Henrikson
Birgitta.haggman.henrikson@mau.se

¹ Department of Orofacial Pain and Jaw Function, Malmö University, 205 06 Malmö, Sweden

² Department of Oral Surgery and Oral Medicine, Malmö University, Malmö, Sweden

³ The Maxillofacial Unit, Halmstad Hospital, Halmstad, Sweden

⁴ Department of Odontology/Clinical Oral Physiology, Umeå University, Umeå, Sweden

back into a normal position. Thus, relocation of the condyle to its normal position occurs through self-manipulation in cases of subluxation, but not in luxation [1]. Clinically, the patient will present with the jaw wide open, or protruded, or in lateral position to the nonaffected side (in the case of a unilateral luxation) [5].

Incidence

Although a retrospective study by Agbara et al. at a university hospital in Nigeria reported that TMJ luxation was associated with yawning, higher age, and male gender, in general, the TMJ joints are more flexible in women and therefore more likely to luxate [6]. However, the incidence of TMJ luxation is low; two medical emergency departments, with 100,000 annual visits combined, reported an average of 5.3 cases annually of TMJ luxation over a period of 7 years [7]. Bilateral luxation of the TMJ is most common with the mandible in a straight open position [8], whereas with a single-sided luxation, the mandible is deviated to the opposite side, with a partially open mouth. Luxation of the TMJ represents 3% of all cases of reported dislocated joints in the body [9].

TMJ luxation can be acute or chronic [10]. Acute TMJ luxation may occur as a result of external trauma, sudden wide mouth opening while yawning, taking a large bite, or laughing. In the clinical situation, TMJ luxation may occur after excessive mouth opening during dental treatment or other oro-pharyngeal procedures [11]. A patient with a history of a TMJ luxation is more likely to have a recurrence [12]. It has been proposed that abnormalities in the stabilizing structures of the TMJ may be associated with luxation. The main factors for joint stability are the ligaments and muscles together with the anatomy of the bony components of the joint [13], which means that the pathophysiology is multifactorial [14]. Concerning the anatomy of the TMJ, a steep articular eminence or an abnormal condylar shape [14] are risk factors for luxation.

Pathogenesis

When the TMJ condyle luxates into an anterior position of the eminence, a reflex is generated that sets the masticatory muscles into a spasm; this hinders the condyle from moving back to its normal position [15]. Systemic diseases associated with muscular spasm and muscular dystonia have been reported to increase the risk for TMJ luxation [14]. Some brands of antipsychotic medications could also contribute to the risk of TMJ luxation due to their side effects of dystonia [16]. Benign hypermobility, which often is hereditary, is another predisposing factor for TMJ luxation [17, 18]. In patients with Ehlers-Danlos syndrome, hypermobility is common and associated

with a weak capsule and ligament laxity [19]; these patients are at risk for recurrent TMJ luxation.

Acute therapy

Manual repositioning of the mandibular condyle into the glenoid fossa is the first choice for acute treatment and considered to be the best approach [2]. In patients with recurrent conditions, this acute treatment can be regarded as a temporary solution, and additional preventative measures may be required.

Preventive therapy

The preventive treatment of TMJ luxation can be either non-surgical or surgical. Jaw exercises are one example of nonsurgical treatment that aims to improve muscle strength and coordination after TMJ luxation. Jaw exercises are considered to have a moderate effect on the ability to prevent repeated luxation, but the scientific evidence is weak. Other nonsurgical methods include intermaxillary fixation (IMF) [20]; prolotherapy, which is injection of sclerosing or proliferant solutions [21] or autologous blood into the TMJ [22]; and botulinum toxin injection into the masseter and pterygoid muscles [23, 24].

Several surgical procedures for creating an obstacle at the eminence have been suggested for limiting the anterior movement of the condylar head to hinder recurrent TMJ luxation. Examples are down fracture of the zygomatic arch, also known as Dautrey's procedure [25], miniplating, bone grafting, and alloplastic materials attached to the articular eminence have also been described. Soft tissue surgery for restricting condyle movement has been suggested, i.e., myotomy of the lateral pterygoids, lateral pterygoid muscle tendon scarification, scarification of the temporalis tendon [26], and capsule plication. Another surgical strategy, eminectomy, clears the path of the condylar head by removing the eminence and is the recommended procedure for achieving total release of condylar translation [15].

In conclusion, several methods have been proposed for the treatment of TMJ luxation.

The aim of this systematic review was to evaluate clinical randomized controlled trials (RCTs) on the effectiveness of surgical and nonsurgical treatment of TMJ luxation that had been published over the last 50 years.

Materials and methods

Inclusion and exclusion criteria

Clinical RCT studies published in English, Swedish, or German on patients diagnosed with TMJ luxation were

considered. Non-RCT studies as well as data already reported in other studies (dual publication), studies on TMJ fractures, and studies with fewer than 10 patients were excluded.

Literature search

The search strategy was designed to identify studies on treatment of TMJ luxation and encompassed all articles in PubMed, the Cochrane Library, and Web of Science. The initial search included studies published from the inception of each database until 31 October 2015; an update search was carried out 26 March 2018. We used these search terms: “Temporomandibular joint” (MeSH) OR “TMJ” (MeSH) AND “Luxation” OR “Subluxation” OR “Dislocation” OR “Open lock” OR “Hypermobility” OR “JHS” OR “Joint Hypermobility Syndrome” and limited the search to randomized controlled trials. Table 1 provides the full search strategy for PubMed. A hand search of the reference lists in the included articles was done to identify additional studies. Grey literature was not included, and authors were not contacted for additional information.

Procedures

Two of the authors (HA, BHH) independently read all titles and abstracts that were found in searches to identify potentially eligible studies for inclusion. If one of the reviewers deemed an article as potentially of interest, it was included

for full-text assessment. All potentially eligible articles were then retrieved as full-text articles to determine if they met the inclusion criteria. Disagreement was resolved by discussion among the investigators. Authors were not contacted for missing information. One of the reviewers was an experienced orofacial pain researcher and the other, an orofacial pain registrar. One author (HA) carried out the data extraction which was reviewed by another author (BHH).

These data were extracted from the RCTs:

- Clinic setting
- Inclusion and exclusion criteria
- Number of patients
- Age and gender of patients
- Number of drop outs
- Treatment method
- Follow-ups
- Results
- Authors’ conclusions

Quality assessment

Two authors (HA, BHH) independently evaluated the quality of each identified article. The quality of each study was assessed using a tool for RCT studies from the Swedish Agency for Health Technology Assessment and Assessment of Social Services (SBU), which SBU

Table 1 Full search strategy on PubMed, 26 March 2018

Search	Search string	No. of articles
Temporomandibular joint		
1	Temporomandibular joint [MeSH]	25,556
2	TMJ [MeSH]	26,047
3	#1 OR #2	26,047
Luxation or subluxation		
4	Luxation	3,526
5	Subluxation	43,945
6	Dislocation	63,547
7	Open lock	397
8	Hypermobility	2,513
9	JHS	649
10	Joint hypermobility syndrome	2,220
11	#4 OR #5 OR #6 OR #7 OR #8 OR #9 OR #10	73,406
Study design		
13	(((((randomized controlled trial[Publication Type] OR (randomized[Title/Abstract] AND controlled[Title/Abstract] AND trial[Title/Abstract]))) OR randomi*[Title/Abstract]	718,112
Combined searches		
12	#3 AND #11	3,203
14	#12 AND #13	93

had modified by combining both parts from the Cochrane Risk of Bias Tool and adding a specific item on possible conflict of interest to the domain “Other risks of bias” [27].

Results

Altogether, 113 unique articles were identified after removal of duplicates (Fig. 1). Following the initial screening of all abstracts, nine articles were reviewed in full text by applying the inclusion and exclusion criteria. One article, Sato et al. [1] did not meet the inclusion criteria and was excluded. The eight remaining articles (Tables 2 and 3) met the inclusion criteria. Six articles were considered to be at moderate risk of bias and the remaining two articles low risk (Table 4).

Reports on surgical techniques and acute therapy

No RCT studies that evaluated surgical techniques were identified. Three of the included articles described acute management of TMJ luxation and evaluated methods for manual repositioning. In an external approach proposed by Ardehali et al., the physician places both hands externally, one hand on each of the patient’s cheeks. The mandibular angle is pulled anteriorly; at the same time, pressure is applied to the coronoid process on the opposite side, with a gentle movement the condylar head is then pushed back into the glenoid fossa on one side. This approach, termed the external approach for reduction of TMJ luxation, was less successful (55%) compared to the conventional method (86%) [28]. A later study by the same author compared conventional repositioning, the external approach, and a wrist pivot method, and reported no significant differences between the techniques concerning successful reduction [29]. Xu et al. evaluated a supine position

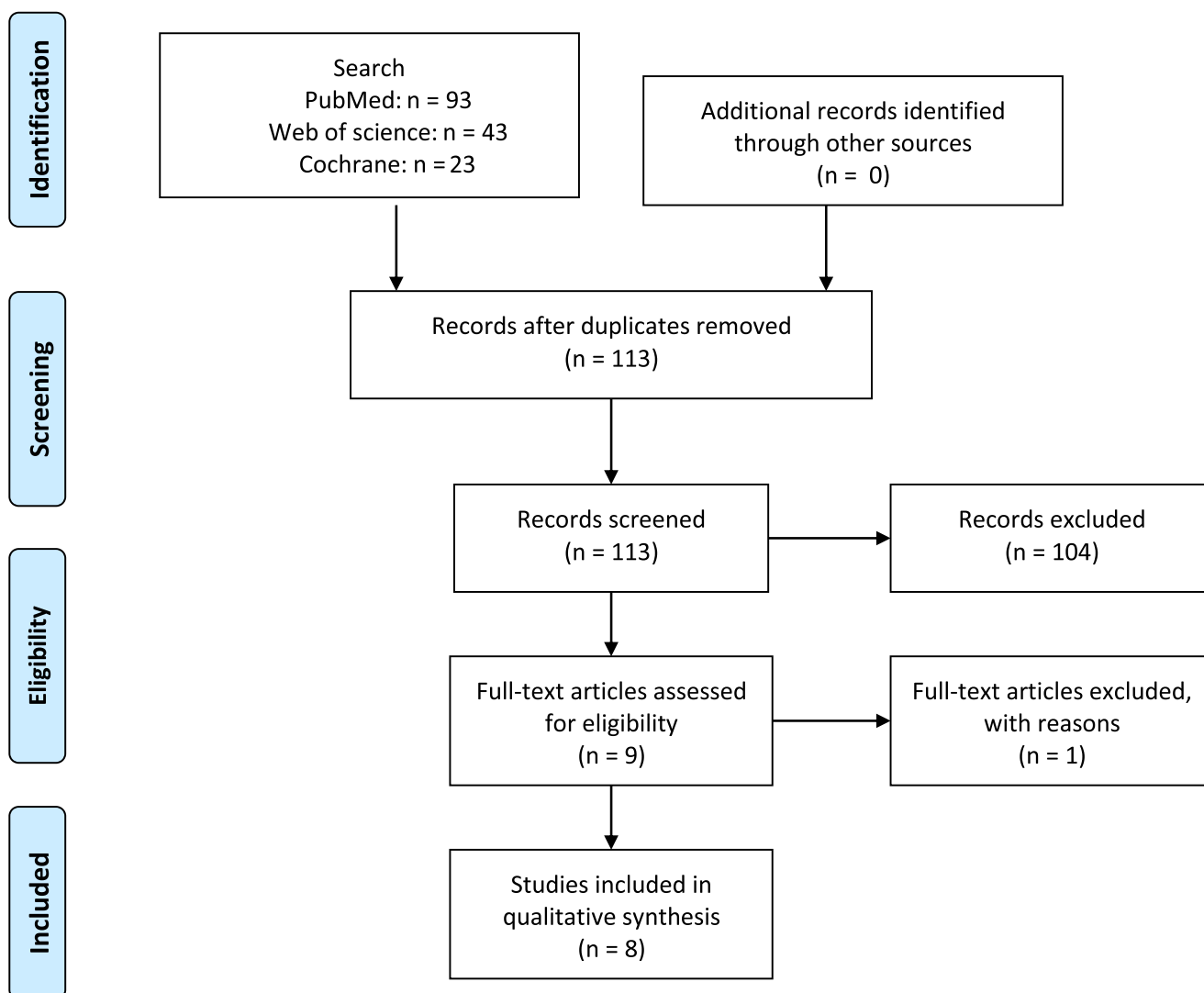


Fig. 1 Flowchart of articles included and excluded in the study

Table 2 Studies on methods for reducing TMJ luxation ($n = 3$) in the present systematic review

Article First author Year	Study sample Setting	Number of subjects (% females) mean age	Treatment	Outcome measures	Results	Authors' conclusions	Comments
Ardehali 2016	Acute TMJ dislocation Tertiary referral center otorrhino-laryngology	Total: 90 (53%) 47 years Conventional: 30 (47%) 47 years Extraoral: 30 (60%) 48 years Wrist pivot: 30 (53%) 47 years	Conventional method (intraoral) compared with extraoral and wrist pivot method	First try successful reduction	Successful reduction Method: Conventional: 87% Extraoral: 67% Wrist pivot: 97% More successful reductions for wrist pivot method compared to extraoral method ($p < 0.01$)	The wrist pivot method should be considered as the first line of treatment of acute TMJ luxation	Only acute short-term outcome
Jiantao 2016	Acute nontraumatic TMJ dislocation Hospital clinic	Total: 40 (48%) 34 years Conventional: 20 (45%) 34 years Supine technique: 20 (62%) 32 years	Conventional method (intraoral) compared with Supine position technique	First try successful reduction Reduction time Pain during reduction (VAS)	Conventional intraoral method: Reduction: 100% Operation time: 269 s (SD 70) Pain: 8.1 (0.7) Supine position technique: Reduction: 100% Operation time: 173s (SD 17) Pain: 6.3 (0.8) Reduced operation time ($p < 0.05$) and pain ($p < 0.01$) with supine position	Reduced operation time and reduced pain perception indicated that the supine position technique method might be a more viable alternative to the conventional method of reduction of acute nontraumatic TMJ dislocation	Only acute short-term outcome
Ardehali 2009	Acute dislocation of TMJ Tertiary referral center otorrhino-laryngology	58 attempts in 55 patients Conventional method: 29 (41%) 26 years Extraoral method: 29 (62%) 32 years	Intraoral compared to extraoral reposition	First try successful reduction	Successful reduction Conventional method: 86.2% (95% CI 73–100) Extraoral method: 55.2% (95% CI 39–79) $p = 0.009$	External method for TMJ reduction could be a good method to avoid bites, and if it is unsuccessful the conventional method still is the gold standard	Only acute short-term outcome Authors' conclusion not in line with the results. Unclear benefits with the new proposed method compared to the conventional intraoral method.

VAS visual analog scale

Table 3 Studies on injection of autologous blood or dextrose prolotherapy ($n = 5$) in the present systematic review

Article First author Year	Study sample Setting	Number of subjects (% females) mean age	Treatment	Outcome measures	Results	Authors' conclusions	Comments
Mustafa 2018	Painful TMJ subluxation or dislocation	Total: 37 (70%) 33 years Placebo: 9 (55%) 25 years 10% dextrose: 10 (70%) 24 years 20% dextrose: 9 (89%) 27 years 30% dextrose: 9 (67%) 24 years	Placebo injection (saline) compared with 10%, 20%, and 30% dextrose injections	MMO Pain intensity	Reduction MMO mm (SD) after 4 months Placebo: 52.3 (6.6)–43.4 (4.2) 10% dextrose: 54.3 (5.9)–39.4 (4.2) 20% dextrose: 52.1 (6.9)–41.2 (5.4) 30% dextrose: 54.0 (7.4)–39.4 (4.5) Reduction in all groups NS between groups	There was no significant difference between the placebo group and the dextrose groups and there is no superiority of any concentration of dextrose over the others in TMJ prolotherapy.	No recurrence of luxations Relatively short follow-up time (4 months)
Cömert Kiliç 2016	Bilateral TMJ hypermobility University clinic	Total: 26 (73%) 31 years Placebo: 12 (75%) 29 years Dextrose: 14 (71%) 32 years	Placebo injection (saline) compared with 30% dextrose injections	MMO TMJ pain (VAS)	Reduction MMO mm (SD) after 1 year Placebo: 46.3 (3.5)–43.7 (5.6) 30% dextrose: 46.1 (6.9)–43.3 (5.9) Reduction MMO in dextrose group Pain reduced both groups NS between groups	These findings suggest that dextrose prolotherapy is no more effective than placebo treatment for any of the outcome variables of TMJ hypermobility assessed	No evaluation of recurrence of luxation during follow-up period
Hegab 2013	Bilateral recurrent TMJ dislocation Outpatient Oral and Maxillofacial clinic	Total: 48 (77%) 33 years ABI 16 IMF 16 ABI+IMF 16	ABI compared to: IMF ABI+IMF	MMO (measured as interincisal distance) Number of recurrences of dislocation	Reduction MMO (mm) after 1 year (number of recurrences) ABI: 8.5 (8) IMF: 9.13 (3) ABI+IMF: 11.0 (0) MMO reduction all groups ($p < 0.0001$) Greatest MMO reduction ABI+IMF group and no recurrences NS between ABI and IMG groups	ABI is a simple and safe technique for treatment of TMJ dislocation in the outpatient clinic. Recurrence can be overcome by multiple injections. However, the best clinical results are given by a combination of ABI and IMF.	Sex and age distribution not provided for the subgroups
Refai 2011	Bilateral TMJ subluxation or dislocation Outpatient Oral and Maxillofacial clinic	Total: 12 (83%) Placebo: 6 (66%) 30 years Dextrose: 6 (100%) 23 years	Placebo injection (saline) compared with 10% dextrose injections	MMO Frequency of dislocations TMJ pain on palpation	Reduction MMO (cm) after 3 months Placebo: 0 Dextrose: 0.7 Greater reduction in the dextrose group ($p = 0.039$) Reduced frequency of luxation and pain in both groups NS between groups	Prolotherapy with 10% dextrose looks promising for the treatment of symptomatic TMJ hypermobility, as evidenced by the therapeutic benefits, simplicity, safety, patient acceptance of the injection technique and lack of significant side effects	Small groups; relatively short follow-up time (3 months)

Table 3 (continued)

Article First author Year	Study sample Setting	Number of subjects (% females) mean age	Treatment	Outcome measures	Results	Authors' conclusions	Comments
Daif 2010	Bilateral recurrent TMJ dislocation Oral and Maxillofacial clinic	Total: 30 (60%) 34 years ABI SJS: 15 ABI SJS+PT : 15	Injection of blood in SJS and SJS+PT	MMO Digital lateral double TMJ radiograph	Reduction MMO mm (SD) after 1 year SJS Group: 3.6 (1.5) no recurrence 60% SJS+PT: 5.3 (2.1) no recurrence 80% Reduction in both groups ($p < 0.05$) and greater in the SJS+PT group ($p < 0.05$) X-ray showed no destruction of bony components.	Injection of autologous blood into the TMJ in patients with chronic recurrent dislocation is a simple, safe and cost-effective technique	Sex and age distribution not provided for the groups

MMO maximal mouth opening, VAS visual analog scale, ABI autologous blood injection, IMF intermaxillary fixation, SJS superior joint space, PT pericapsular tissues

technique compared to the conventional technique and reported reduced operation time and pain with the supine position technique [30].

Reports on preventive therapy

Five studies [3, 11, 31–33] evaluated nonsurgical methods for treating recurrent TMJ luxation with injection. Three of these studies evaluated the effect of dextrose prolotherapy and reported that maximal mouth opening was significantly reduced with dextrose treatment, but only one study showed a significant difference compared to placebo [3]. There were no significant differences between the dextrose and placebo groups concerning the frequency of luxation or pain.

In the Daif et al. study, autologous blood was injected in the superior joint space in one group and compared with a group of patients injected in both the superior joint space and the pericapsular tissues. The group injected in both areas had a more favorable outcome after 1 year with an 80% success rate compared to 60% in the superior joint space only group. The group that had been injected in the superior joint space and pericapsular tissue also had a significantly larger reduction in maximal mouth opening. In both groups, digital radiographic imaging of the TMJ showed absence of any destructive changes of the bony components. However, only in the group injected in both areas did the condylar head not exceed the articular eminence in the open position [11].

Injections of autologous blood into the superior joint space and pericapsular tissue were also done in the Hegab et al. study. Patients treated with autologous blood injection in combination with 4 weeks of IMF had significantly better outcome ($p < 0.0001$) concerning reduced interincisal distance (average reduction 11 mm) and no recurrence of TMJ luxation, compared to autologous blood injection alone (8 mm reduction) and the intermaxillary fixation group (9 mm reduction) after 1 year. The autologous blood injection alone group had the highest recurrence of luxation during the study period (8 of 16 patients) [32].

Discussion

The main finding of this systematic review was that there are few RCTs on treatment of TMJ luxation and a lack of RCTs on surgical techniques. Only eight RCTs matching the inclusion and exclusion criteria were available, all dealing with nonsurgical treatment. These findings are in line with Prechel et al. [34] suggesting that the possibilities for evidence-based conclusions are limited. As the number of patients seeking treatment for recurrent TMJ luxation is limited, it seems necessary to do multicenter studies in order to recruit enough patients for the RCTs, especially concerning surgical treatment of TMJ luxation. However, in a surgical

Table 4 Risk-of-bias assessment of included studies ($n = 8$). Quality graded as low, moderate, or high

First author Year	Selection	Treatment	Assessment	Drop-out rate	Reporting	Conflict of interest	Summary
Mustafa 2018	Moderate	Moderate	Low	Moderate	Moderate	Moderate	Moderate
Cömert Kiliç 2016	Moderate	Low	Moderate	Moderate	Moderate	Moderate	Moderate
Ardehali 2016	Low	Low	Moderate	Moderate	Moderate	Moderate	Moderate
Jiantao 2016	Low	Low	Moderate	Low	Moderate	Moderate	Low
Hegab 2013	Moderate	Moderate	Moderate	Low	Moderate	Moderate	Moderate
Refai 2011	Moderate	Low	Moderate	Low	High	Moderate	Moderate
Daif 2010	Moderate	Moderate	Moderate	Moderate	Moderate	Moderate	Moderate
Ardehali 2009	Low	Low	Moderate	Low	Moderate	Moderate	Low

study, allocation of patients with recurrent TMJ luxation to a placebo surgical treatment group might be questionable from an ethical point of view. On the other hand, it is equally important to ensure that unnecessary surgical procedures are not done, as exemplified by a double-blind RCT on arthroscopic surgery for osteoarthritis of the knee, where the outcome after arthroscopic lavage or arthroscopic debridement were no better than those after a placebo procedure [35].

The three main weaknesses observed in many of the studies in the present review were lack of placebo groups in the intervention studies, small patient numbers, generally short follow-up periods, and being operator dependent comparative studies rather than true RCTs. Only three of the five studies on injection methods included a placebo treatment group [3]. The number of patients varied from a relatively large study on 90 patients [29] to one with 12 patients [3]. The latter had only six patients in each group, which raises concerns regarding the statistical power of this study. This highlights the problem of recruiting large numbers of patients with TMJ luxation or subluxation to RCT studies. In addition, the follow-up periods in the included studies varied from acute treatment with no follow-up [28] to a 1-year follow-up [11, 32]. The systematic review on treatment of recurrent TMJ luxation by de Almeida et al. only included studies with follow-ups of 3 years or more; none were RCTs. Thus, they concluded that, based on the data available at the time of their review, it was not possible to determine the treatment option that could guarantee a long-term elimination of recurrent TMJ luxation [15]. Another non-systematic review combined with case reports concluded that accurate comparisons of the reported surgical interventions are difficult because of varying follow-up times and definitions of success [8].

The main goal in surgical treatment of TMJ luxation has been to restore joint function by surgically modifying the bone morphology and/or modifying the supporting muscles and ligaments [36]. According to de Almeida et al., the TMJ system requires time to recover and adapt postoperatively; they suggest a 36-month recurrence-free period as a benchmark for a stable result [15]. Their systematic review included only prospective or retrospective cohort studies, while our review

included only RCTs, which provide a higher level of evidence compared to observational studies. In the Daif et al. study, 6 of the 15 patients in the superior joint space injection group had recurrences during the follow-up period and 3 of the 15 patients in the superior joint space and pericapsular tissues injection group had recurrences. These failures were later treated surgically as the patients refused further injections. Further follow-ups of these surgical patients have not yet been reported [11]. Hegab et al. performed repeated injections of autologous blood in the superior joint space and pericapsular tissues in patients with recurrent dislocations; this resulted in 6 recurrences of luxation in 16 patients after the first injection. After a second injection, there were still 2 recurrences, which were then finally successfully treated with a third injection. This indicates that repeated injections might be successful in recurrent TMJ luxation. However, the relatively short follow-up time of 12 months should be considered [32].

For open surgery to limit the forward movement of the condylar head by creating an obstacle [37] at the articular eminence, from a viewpoint of prognosis and risk for complications, treatment cost has been considered high in comparison to treatment effect [2]. For recurrent TMJ luxation, eminectomy is a recommended surgical procedure; however, significant evidence or RCTs that support best practice are lacking. Thus, this systematic review found no RCT studies of surgical techniques, even though surgery is a commonly used treatment option for recurring TMJ luxation. The rareness of this condition may explain this, together with the difficulties in comparing surgery to a sham surgical procedure.

The highest success rate based on the primary studies in our systematic review was reported for treatment with autologous blood injection in the superior joint space and pericapsular tissues in combination with intermaxillary fixation during 4 weeks [32]. According to Hasson et al., blood injected into the superior joint space and pericapsular tissues causes scarring when fibrous tissue forms, restricting the mobility of the condyle and preventing TMJ luxation [22]. Postoperative scarring may also be responsible for a substantial portion of the surgical benefit as evidence suggests that immobilization of a joint after an intra-articular surgical procedure results in fibrosis

[36]. Botulinum toxin injection into the masseter and pterygoid muscles is another proposed non-surgical technique [23, 24], although there is a lack of both RCT studies and consensus for guidelines [34, 38].

TMJ luxation has an obvious impact on the quality of life as it often is associated with pain as well as impaired function. Although no included study evaluated quality of life, three of the studies in this systematic review took this into account by evaluating pain [3, 31, 33]. In general, there were no significant differences between placebo and treatment groups with regard to pain intensity at the follow-ups.

The role of a systematic review is to summarize existing evidence, or lack thereof, for a specific topic. The present review highlights that the current evidence base for surgical techniques for TMJ luxation is weak, in accordance with the review from Pretchel et al. [34], but this makes it even more important to highlight that more research is needed in the area for the benefit of clinicians and patients.

In conclusion, several treatment options for surgical as well as conservative treatment of recurrent TMJ luxation have been proposed. However, most studies are case reports or nonrandomized trials, and in the present review, only eight articles in the last 50 years met the inclusion criteria for an RCT; none of these concerned surgical techniques. The reasons for this lack of studies on surgical options may be due to difficulties in recruiting patients for an RCT. Within the limitations of this systematic review, autologous blood injection in the superior joint space and pericapsular tissues in combination with IMF seems to be the treatment that has the best scientific support for recurrent TMJ luxation. However, there is a need for well-designed randomized of the various surgical and nonsurgical techniques in use, with longer follow-ups, and insight into the patient experience.

Funding Information Open access funding provided by Malmö University.

Compliance with ethical standards

Conflict of interest The authors declare that they have no conflict of interest.

Ethical approval This is a systematic review article and therefore no ethical approval is required.

Informed consent For this type of study, informed consent is not required.

Open Access This article is distributed under the terms of the Creative Commons Attribution 4.0 International License (<http://creativecommons.org/licenses/by/4.0/>), which permits unrestricted use, distribution, and reproduction in any medium, provided you give appropriate credit to the original author(s) and the source, provide a link to the Creative Commons license, and indicate if changes were made.

References

- Sato J, Segami N, Nishimura M, Suzuki T, Kaneyama K, Fujimura K (2003) Clinical evaluation of arthroscopic eminoplasty for habitual dislocation of the temporomandibular joint: comparative study with conventional open eminectomy. *Oral Surg Oral Med Oral Pathol Oral Radiol Endod* 95(4):390–395. <https://doi.org/10.1067/moe.2003.128>
- Swedish National Guidelines The National Board of Health and Welfare provides recommendations in pain and functional disorders of the mouth, face and jaws; Available at: <http://www.socialstyrelsen.se/nationalguidelines/nationalguidelinesforadultdentalcare>
- Refai H, Altahhan O, Elsharkawy R (2011) The efficacy of dextrose prolotherapy for temporomandibular joint hypermobility: a preliminary prospective, randomized, double-blind, placebo-controlled clinical trial. *J Oral Maxillofac Surg* 69(12):2962–2970. <https://doi.org/10.1016/j.joms.2011.02.128>
- Dworkin S, LeResche L (1992) Research diagnostic criteria for temporomandibular disorders: review, criteria, examinations and specifications, critique. *J Craniomand Disord* 6(4):301–355
- Peck CC, Goulet JP, Lobbezoo F, Schiffman EL, Alstergren P, Anderson GC, de Leeuw R, Jensen R, Michelotti A, Ohrbach R, Petersson A, List T (2014) Expanding the taxonomy of the diagnostic criteria for temporomandibular disorders. *J Oral Rehabil* 41(1):2–23. <https://doi.org/10.1111/joor.12132>
- Agbara R, Fomete B, Obiadazie AC, Idehen K, Okeke U (2014) Temporomandibular joint dislocation: experiences from Zaria, Nigeria. *J Korean Assoc Oral Maxillofac Surg* 40(3):111–116. <https://doi.org/10.5125/jkaoms.2014.40.3.111>
- Lowery LE, Beeson MS, Lum KK (2004) The wrist pivot method, a novel technique for temporomandibular joint reduction. *J Emerg Med* 27(2):167–170. <https://doi.org/10.1016/j.jemermed.2004.03.007>
- Martins WD, Ribas Mde O, Bisinelli J, Franca BH, Martins G (2014) Recurrent dislocation of the temporomandibular joint: a literature review and two case reports treated with eminectomy. *Cranio* 32(2):110–117. <https://doi.org/10.1179/0886963413Z.00000000017>
- Lovely FW, Copeland RA (1981) Reduction eminoplasty for chronic recurrent luxation of the temporomandibular joint. *J Can Dent Assoc* 47(3):179–184
- Adekeye EO, Shamia RI, Cove P (1976) Inverted L-shaped ramus osteotomy for prolonged bilateral dislocation of the temporomandibular joint. *Oral Surg Oral Med Oral Pathol* 41(5):568–577
- Daif ET (2010) Autologous blood injection as a new treatment modality for chronic recurrent temporomandibular joint dislocation. *Oral Surg Oral Med Oral Pathol Oral Radiol Endod* 109(1):31–36. <https://doi.org/10.1016/j.tripleo.2009.08.002>
- Kai S, Kai H, Nakayama E, Tabata O, Tashiro H, Miyajima T, Sasaguri M (1992) Clinical symptoms of open lock position of the condyle. Relation to anterior dislocation of the temporomandibular joint. *Oral Surg Oral Med Oral Pathol* 74(2):143–148
- Leopard PJ (1987) Surgery of the non-ankylosed temporomandibular joint. *Br J Oral Maxillofac Surg* 25(2):138–148
- Liddell A, Perez DE (2015) Temporomandibular joint dislocation. *Oral Maxillofac Surg Clin North Am* 27(1):125–136. <https://doi.org/10.1016/j.coms.2014.09.009>
- de Almeida VL, Vitorino Nde S, Nascimento AL, da Silva Junior DC, de Freitas PH (2016) Stability of treatments for recurrent temporomandibular joint luxation: a systematic review. *Int J Oral Maxillofac Surg* 45(3):304–307. <https://doi.org/10.1016/j.ijom.2015.10.022>
- Sharma NK, Singh AK, Pandey A, Verma V, Singh S (2015) Temporomandibular joint dislocation. *Natl J Maxillofac Surg* 6(1):16–20. <https://doi.org/10.4103/0975-5950.168212>

17. Buckingham RB, Braun T, Harinstein DA, Oral K, Bauman D, Bartynski W, Killian PJ, Bidula LP (1991) Temporomandibular joint dysfunction syndrome: a close association with systemic joint laxity (the hypermobile joint syndrome). *Oral Surg Oral Med Oral Pathol* 72(5):514–519
18. Harinstein D, Buckingham RB, Braun T, Oral K, Bauman DH, Killian PJ, Bidula LP (1988) Systemic joint laxity (the hypermobile joint syndrome) is associated with temporomandibular joint dysfunction. *Arthritis Rheum* 31(10):1259–1264
19. Thexton A (1965) A case of Ehlers-Danlos syndrome presenting with recurrent dislocation of the temporomandibular joint. *Br J Oral Surg* 3:190–193
20. Myrhaug H (1951) A new method of operation for habitual dislocation of the mandible; review of former methods of treatment. *Acta Odontol Scand* 9(3–4):247–260
21. Becker WH (1954) Report of ten years' experience in the treatment of subluxation and luxation of the temporomandibular joint by the injection of a sclerosing agent and immobilization of the mandible. *Oral Surg Oral Med Oral Pathol* 7(7):732–734
22. Hasson O, Nahlieli O (2001) Autologous blood injection for treatment of recurrent temporomandibular joint dislocation. *Oral Surg Oral Med Oral Pathol Oral Radiol Endod* 92(4):390–393
23. Daelen B, Thorwirth V, Koch A (1997) Treatment of recurrent dislocation of the temporomandibular joint with type A botulinum toxin. *Int J Oral Maxillofac Surg* 26(6):458–460
24. Fu KY, Chen HM, Sun ZP, Zhang ZK, Ma XC (2010) Long-term efficacy of botulinum toxin type A for the treatment of habitual dislocation of the temporomandibular joint. *Br J Oral Maxillofac Surg* 48(4):281–284. <https://doi.org/10.1016/j.bjoms.2009.07.014>
25. Gadre KS, Kaul D, Ramanojam S, Shah S (2010) Dautrey's procedure in treatment of recurrent dislocation of the mandible. *J Oral Maxillofac Surg* 68(8):2021–2024. <https://doi.org/10.1016/j.joms.2009.10.015>
26. Gould JF (1978) Shortening of the temporalis tendon for hypermobility of the temporomandibular joint. *J Oral Surg* 36(10):781–783
27. Swedish Agency of Health Technology A, Assessment of Social Services SBU (2017) Assessment of methods in health care - a handbook. Available at : http://www.sbuse/globalassets/eng_metodboken.pdf
28. Ardehali MM, Kouhi A, Meighani A, Rad FM, Emami H (2009) Temporomandibular joint dislocation reduction technique: a new external method vs. the traditional. *Ann Plast Surg* 63(2):176–178. <https://doi.org/10.1097/SAP.0b013e31818937aa>
29. Ardehali MM, Tari N, Bastaninejad S, Amirizad E (2016) Comparison of different approaches to the reduction of anterior temporomandibular joint dislocation: a randomized clinical trial. *Int J Oral Maxillofac Surg* 45(8):1009–1014. <https://doi.org/10.1016/j.ijom.2016.04.015>
30. Xu J, Dong S, Zhou H, Somar M, Lv K, Li Z (2016) The supine position technique method is better than the conventional method for manual reduction of acute nontraumatic temporomandibular joint dislocation. *J Craniofac Surg* 27(4):919–922. <https://doi.org/10.1097/SCS.0000000000002645>
31. Comert Kilic S, Gungormus M (2016) Is dextrose prolotherapy superior to placebo for the treatment of temporomandibular joint hypermobility? A randomized clinical trial. *Int J Oral Maxillofac Surg* 45(7):813–819. <https://doi.org/10.1016/j.ijom.2016.01.006>
32. Hegab AF (2013) Treatment of chronic recurrent dislocation of the temporomandibular joint with injection of autologous blood alone, intermaxillary fixation alone, or both together: a prospective, randomised, controlled clinical trial. *Br J Oral Maxillofac Surg* 51(8):813–817. <https://doi.org/10.1016/j.bjoms.2013.04.010>
33. Mustafa R, Gungormus M, Mollaoglu N (2018) Evaluation of the efficacy of different concentrations of dextrose prolotherapy in temporomandibular joint hypermobility treatment. *J Craniofac Surg*. <https://doi.org/10.1097/SCS.0000000000004480>
34. Prechel U, Ottl P, Ahlers OM, Neff A (2018) The treatment of temporomandibular joint dislocation. *Dtsch Arztebl Int* 115(5):59–64. <https://doi.org/10.3238/arztebl.2018.0059>
35. Moseley JB, O'Malley K, Petersen NJ, Menke TJ, Brody BA, Kuykendall DH, Hollingsworth JC, Ashton CM, Wray NP (2002) A controlled trial of arthroscopic surgery for osteoarthritis of the knee. *N Engl J Med* 347(2):81–88. <https://doi.org/10.1056/NEJMoa013259>
36. Shorey CW, Campbell JH (2000) Dislocation of the temporomandibular joint. *Oral Surg Oral Med Oral Pathol Oral Radiol Endod* 89(6):662–668
37. Medra AM, Mahrous AM (2008) Glenotemporal osteotomy and bone grafting in the management of chronic recurrent dislocation and hypermobility of the temporomandibular joint. *Br J Oral Maxillofac Surg* 46(2):119–122
38. Ziegler CM, Haag C, Muhling J (2003) Treatment of recurrent temporomandibular joint dislocation with intramuscular botulinum toxin injection. *Clin Oral Investig* 7(1):52–55. <https://doi.org/10.1007/s00784-002-0187-y>

Publisher's note Springer Nature remains neutral with regard to jurisdictional claims in published maps and institutional affiliations.