



# Clinical outcomes and complications after biportal endoscopic spine surgery: a comprehensive systematic review and meta-analysis of 3673 cases

Don Y. Park<sup>1</sup> · Alexander Upfill-Brown<sup>1</sup> · Nora Curtin<sup>1</sup> · Christopher D. Hamad<sup>1</sup> · Akash Shah<sup>1</sup> · Brian Kwon<sup>2</sup> · Yong H. Kim<sup>3</sup> · Dong Hwa Heo<sup>4</sup> · Cheol Woong Park<sup>5</sup> · William L. Sheppard<sup>1</sup>

Received: 7 December 2022 / Revised: 7 December 2022 / Accepted: 4 April 2023 / Published online: 20 April 2023  
This is a U.S. Government work and not under copyright protection in the US; foreign copyright protection may apply 2023

## Abstract

**Purpose** Current literature suggests that biportal spinal endoscopy is safe and effective in treating lumbar spine pathology such as lumbar disc herniation, lumbar stenosis, and degenerative spondylolisthesis. No prior study has investigated the postoperative outcomes or complication profile of the technique as a whole. This study serves as the first comprehensive systematic review and meta-analysis of biportal spinal endoscopy in the lumbar spine.

**Methods** A PubMed literature search provided over 100 studies. 42 papers were reviewed and 3673 cases were identified with average follow-up time of 12.5 months. Preoperative diagnoses consisted of acute disc herniation (1098), lumbar stenosis (2432), and degenerative spondylolisthesis (229). Demographics, operative details, complications, and perioperative outcome and satisfaction scores were analyzed.

**Results** Average age was 61.32 years, 48% male. 2402 decompressions, 1056 discectomies, and 261 transforaminal lumbar Interbody fusions (TLIFs) were performed. Surgery was performed on 4376 lumbar levels, with L4-5 being most common (61.3%). 290 total complications occurred, 2.23% durotomies, 1.29% inadequate decompressions, 3.79% epidural hematomas, and < 1% transient nerve root injuries, infections, and iatrogenic instability. Significant improvement in VAS-Back, VAS-Leg, ODI, and Macnab Scores were seen across the cohort.

**Conclusion** Biportal spinal endoscopy is a novel method to address pathology in the lumbar spine with direct visualization through an endoscopic approach. Complications are comparable to previously published rates. Clinical outcomes demonstrate effectiveness. Prospective studies are required to assess the efficacy of the technique as compared to traditional techniques. This study demonstrates that the technique can be successful in the lumbar spine.

**Keywords** Biportal endoscopic spine surgery · Endoscopic spine surgery · Minimally invasive spine surgery

✉ Don Y. Park  
dypark@mednet.ucla.edu

- <sup>1</sup> Department of Orthopaedic Surgery, David Geffen School of Medicine at University of California Los Angeles, 16th Street, Suite 3142, Los Angeles, Santa Monica, CA 90404, USA
- <sup>2</sup> Department of Orthopaedic Surgery, New England Baptist Hospital, Tufts University School of Medicine, Boston, MA 02120, USA
- <sup>3</sup> Department of Orthopaedic Surgery, NYU Grossman School of Medicine, New York, NY 10016, USA
- <sup>4</sup> Department of Neurosurgery, Champodonamu Hospital, Seoul, South Korea
- <sup>5</sup> Department of Neurosurgery, Woori Hospital, Seoul, South Korea

## Introduction

With the growing demand for increasingly less invasive surgery, spinal endoscopy has grown in utilization particularly in Asia and Europe [1]. Spinal endoscopy has been employed for a variety of indications ranging from degenerative pathology to malignancy. There are multiple endoscopic techniques and platforms, including uniportal endoscopy, microendoscopy, and biportal endoscopy. In general, the literature to date has shown that biportal spinal endoscopy is safe and effective in treating lumbar spine pathology. Similar in principle to arthroscopy, biportal endoscopic spinal surgery has been employed successfully in the lumbar spine for the treatment of degenerative lumbar stenosis, primary and recurrent disc protrusion/extrusion, spondylolisthesis,

and segmental instability [2–5]. If the trends of arthroscopic utilization in knee and shoulder pathology hold, it is likely that endoscopic surgery for spine will be in greater demand by both patients and clinicians alike in the future. It is thus of great clinical importance to determine the safety profile and expected postoperative outcomes of these procedures.

While there have been multiple case reports and series detailing surgical technique, post-operative complications and outcomes of biportal endoscopy, comprehensive evaluations in the form of prospective/randomized controlled trials or systematic reviews are lacking. While prior studies have evaluated the performance of the techniques, no study has investigated the postoperative outcomes or complication profile of the technique as a whole. Furthermore, no extensive analyses have been done with regard to clinical outcomes after endoscopic decompression via discectomy, laminectomy, and transforaminal lumbar Interbody fusions (TLIFs). We aim to investigate the post-operative outcomes and complication profile of biportal endoscopic lumbar spine surgery with a comprehensive systematic review and meta-analysis. We hypothesize that outcomes will be favorable with a low complication profile overall.

## Methods

### Literature Search

The PubMed library database was utilized in the development of this systematic review. A comprehensive search was completed collecting all articles dates prior to March 31<sup>st</sup>, 2022. Utilizing search terms “Biportal” and “Lumbar”, abstracts and article titles were individually reviewed in conjunction with PRISMA (Preferred Reporting Items for Systematic Reviews and Meta-Analyses) checklist. This yielded over 100 articles for review. Literature was selected and analyzed to ensure that it followed the following inclusion criteria: 1) Studies written in the English language; 2) Primary reports, series, clinical trials, or cohort studies; 3) Published in Peer-Reviewed Journals; 4) Contained subjects, demographics, complication profiles, and functional outcome scores. Any meta-analyses, systematic reviews, cadaveric, biomechanical or animal-based experiments were excluded for the purposes of this study. After inclusion/exclusion, a total of 46 studies were evaluated further. One study was removed due to copyright access restrictions. A technique paper without patient demographics, complications, or outcomes profiles was also removed from analysis. Lastly, 2 additional studies were removed as duplicates. A total of 42 studies, with 3673 cases, were

subsequently included for analysis [2, 3, 5–43]. A total of 28 articles were retrospective studies, 12 were prospective, and 2 were case reports.

### Data Abstraction

A full text review of each article took place after inclusion/exclusion criteria were applied. Data on patient age, sex, study period, clinical follow-up, preoperative diagnosis/indications, biportal endoscopic decompression technique (laminectomy, discectomy, and TLIF), operative detail (including lumbar level, operative time and blood loss), hospital stay length, and functional outcome scores were abstracted and reported.

### Statistics

Only studies reporting estimates of variance, such as standard deviation, for functional outcome scores were included in the meta-analysis. Functional outcomes were analyzed using a random effects model with sub-group analysis performed for different procedure types using the “meta” package [44]. Between study heterogeneity was quantified using  $I^2$  [2] and Cochran’s  $Q$ . The between study variance,  $\tau^2$ , was used to generate prediction intervals for each sub-group and the study population as a whole. In analysis of complication rates, only studies reporting clinically diagnosed complications, rather than those uncovered during routine post-operative MRI without any clinical symptoms, were included in analysis. To generate estimates of complication rates across studies, multi-level logistic regression models with 95% prediction intervals generated using bootstrapping with 1000 replicates to account for between study heterogeneity using the “lme4” package in R [45]. All tests were unpaired with a significance level defined as a 2-tailed  $P$  of 0.05. Statistical analysis was carried out in R 3.6.0 (R Foundation for Statistical Computing, Vienna, Austria).

## Results

### Demographics (Table 1)

A total of 42 papers were included for analysis and review, providing 3673 patients and 3719 cases with an average follow-up time of 12.5 months. Leading preoperative diagnoses consisted of acute disc herniation (1098), lumbar stenosis (2432), and degenerative spondylolisthesis (229). The average age of the population was 61.32 years, with 48% identifying as male. Surgery was performed on

**Table 1** Table depicting the overall demographic data collected for the study from the papers that fit the inclusion criteria

Demographics	
Average study period(Years)	1.6
Total patients	3673
Average age	61.3
Total males	1752
Total females	1899
Total operative levels	4376
Average follow-up (Months)	12.5
Preoperative disc herniation	1098
Preoperative lumbar stenosis	2432
Preoperative degenerative spondylolisthesis	229
Preoperative facet cysts	2

4376 lumbar levels, with L4-5 as the most common level (61.3%).

### Operative Detail and Complication Profile

A total of 1056 Biportal Endoscopic Discectomies and 2402 Biportal Endoscopic Laminectomies were employed. The least utilized intervention for Biportal Endoscopic decompression in the lumbar spine was TLIF, with a total of 261 cases. Mean age was significantly different between groups ( $p < 0.001$ ). The average age for Biportal Discectomy was 50, whereas the ages for Biportal Laminectomy and TLIF were 65 and 67 respectively. The most common lumbar level was L4-5 followed widely by adjacent levels above and below (Table 2). Of a total 3761 operative levels, the average operative time was 89.53 min (range: 36–182). Estimated blood loss (EBL) was noted at 119.24 cc on average (range: 34.67–332.1). Total Hospital

**Table 2** Operative Detail

Biportal endoscopic discectomy	Biportal endoscopic decompression	Biportal endoscopic TLIF	Surgery performed at lumbar levels				
			L1-L2	L2-L3	L3-L4	L4-L5	L5-S1
1056	2402	261	2	101	351	1255	338

Table depicting the number of each surgery type performed and the lumbar levels involved in the surgeries

**Table 3** Global Complication Profile

	Dural tear	Incomplete decompression	Epidural hematoma	Nerve root injury (transient)	Iatrogenic instability	Infection
Total	83	48	141	9	6	3
% of cases	2.23%	1.29%	3.79%	0.24%	0.16%	0.08%

Table depicting the number of occurrences for the respective complications and the percentage rate of each complication

stay varied widely, but was found to be 5.38 days on average (range: 0.33–14.53).

There were 290 total complications, with 2.23% durotomies, 1.29% inadequate decompressions, 3.79% epidural hematomas, and < 1% for transient nerve root injuries, infections, and iatrogenic instability (Table 3). Total complication percentage was 7.79% amongst all cases.

Subgroup complication analysis noted dural tear, epidural hematoma, and incomplete decompression to be most common. Dural tear and epidural hematoma were most common in the TLIF group at 2.1% and 2.4%, respectively. The highest reported incidence of dural tear and epidural hematoma was 5%. Incomplete decompression was highest at 1.7% in biportal laminectomy cases. In general, no complication occurred at a rate greater than 2.5%, irrespective of surgical procedure (Table 4).

### Functional Outcome and Patient-Reported Satisfaction Scores

Perioperative outcome scores (VAS – Visual Analog Scale, and ODI – Oswestry Disability Index), as well as patient satisfaction MacNab scores were analyzed from 36 papers which included this data. Significant improvements in total scores for VAS-Back, VAS-Leg, and ODI ( $p < 0.01$ ) were seen across the cohort when assessing perioperative change (Figs. 1, 2, 3). When calculating the mean difference in preoperative to postoperative outcome scores, VAS-Back improved by a mean of 4.06 (95% CI: 3.59–4.53), VAS-Leg improved by 5.47 (95% CI: 5.04–5.91), and ODI improved by 40.62 (95% CI: 36.13–45.10). Patients reported a mean MacNab score of 80.06% (Range: 56.1%–95%). On average, Biportal discectomy had the highest patient satisfaction scores at 82.4%, followed by decompression at 80.8% and TLIF at 70.3%.

**Table 4** Subgroup complication analysis

	Group	Min	Mean	Max
Dural tear	TLIF	0.002	0.021	0.050
	Laminectomy	0.009	0.018	0.029
	Discectomy	0.001	0.018	0.041
Epidural hematoma	TLIF	0.004	0.024	0.050
	Laminectomy	0.008	0.014	0.020
	Discectomy	0.000	0.000	0.000
Nerve injury	TLIF	0.000	0.009	0.022
	Laminectomy	0.000	0.000	0.001
	Discectomy	0.000	0.007	0.018
Incomplete decompression	TLIF	0.021	0.004	0.021
	Laminectomy	0.017	0.017	0.167
	Discectomy	0.023	0.005	0.050
Iatrogenic instability	TLIF	0.018	0.004	0.018
	Laminectomy	0.006	0.002	0.006
	Discectomy	0.000	0.000	0.000
Infection	TLIF	0.014	0.004	0.014
	Laminectomy	0.001	0.000	0.001
	Discectomy	0.002	0.001	0.002

Table depicting the subgroup analysis of the complications for each of the surgery types

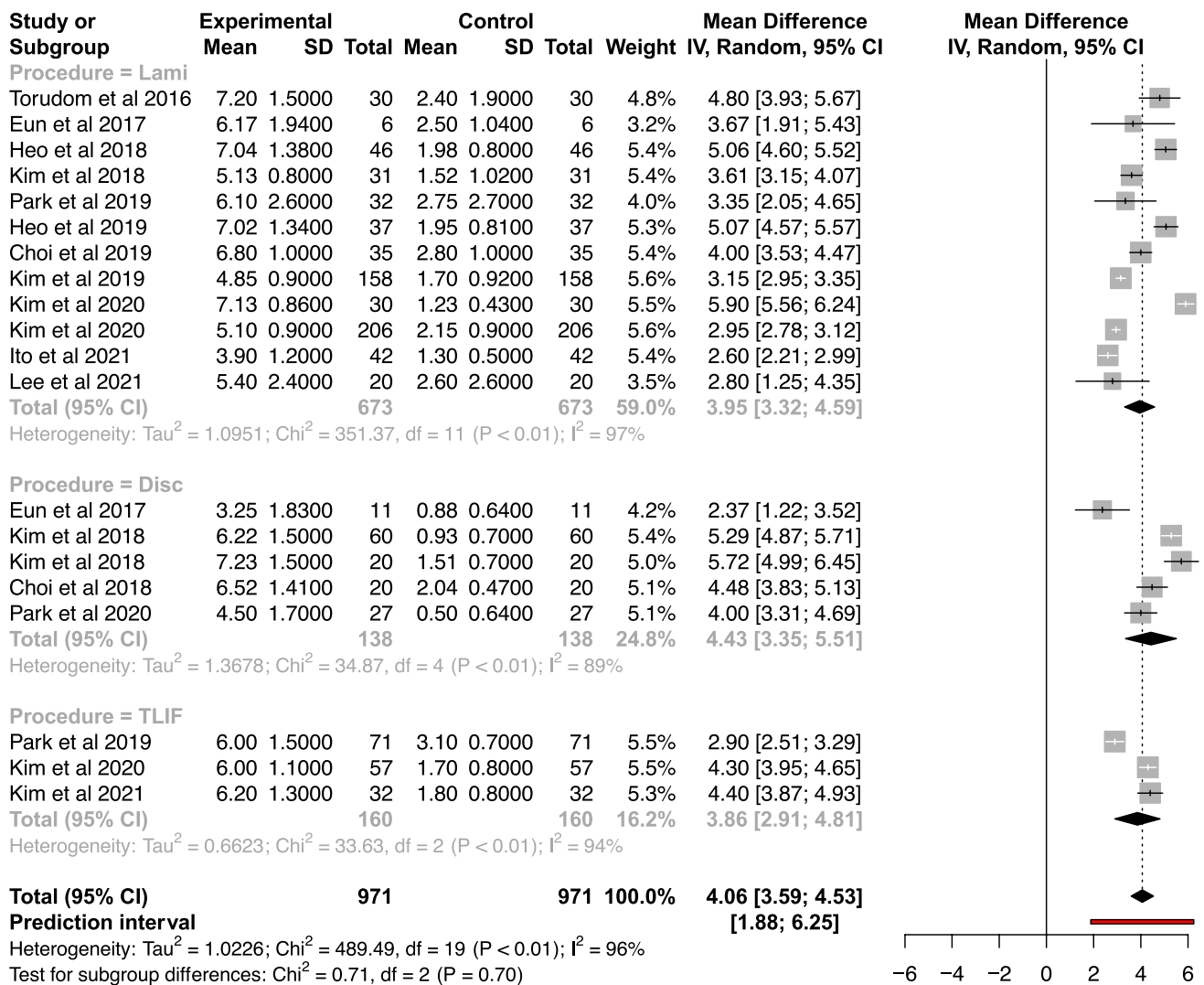
Perioperative outcome scores were also analyzed by surgical procedure. Similar significant improvements ( $p < 0.01$ ) in VAS-Back, VAS-Leg, and ODI scores were noted for biportal endoscopic laminectomy, discectomy, and TLIF, respectively (Figs. 1, 2, 3). For biportal endoscopic TLIF, VAS-Back improved by a mean of 3.86 (95% CI: 2.91–4.81;  $p < 0.01$ ), VAS-Leg improved by 5.35 (95% CI: 3.77–6.94;  $p < 0.01$ ), and ODI improved by 41.62 (95% CI: 30.90–52.34;  $p < 0.01$ ). Similarly, for biportal endoscopic discectomy, VAS-Back improved by a mean of 4.43 (95% CI: 3.35–5.51;  $p < 0.01$ ), VAS-Leg improved by 6.10 (95% CI: 5.57–6.64;  $p < 0.01$ ), and ODI improved by 44.87 (95% CI: 27.57–62.18;  $p < 0.01$ ). Lastly, for biportal endoscopic laminectomy, VAS-Back improved by a mean of 3.95 (95% CI: 3.32–4.59;  $p < 0.01$ ), VAS-Leg improved by 5.25 (95% CI: 4.72–5.79;  $p < 0.01$ ), and ODI improved by 39.36 (95% CI: 34.48–44.25;  $p < 0.01$ ). Overall, improvements were noted in these scores regardless of population heterogeneity or procedure type.

## Discussion

Biportal spinal endoscopy is a novel method to address pathology in the lumbar spine, offering surgeons direct visualization through an ultra-minimally invasive approach. Biportal spinal endoscopy differs from uniportal and microendoscopic techniques in that the endoscope is separate from the surgical instruments and triangulated in the surgical region of interest. The use of endoscopic irrigation allows for excellent visualization, especially in obese populations, while providing hemostasis through hydrostatic pressure [46]. This technique is similar to the basic principles of arthroscopy, which is now considered the standard of care in most shoulder and knee surgeries.

This study analyzed a large sample size of 3673 lumbar biportal endoscopic cases, ranging from discectomies, decompressions, and TLIFs, and demonstrated the clinical effectiveness with improved clinical outcome scores demonstrating clinical success. Across all the various surgery types, the biportal technique significantly improved post-operative VAS-back, VAS-leg and ODI scores as compared to the preoperative status. These findings were consistent for all 3 procedures across all reporting studies, despite  $> 80\%$  heterogeneity amongst available literature. Most importantly, confidence intervals remained narrow, with all mean differences remaining  $> 0$  for functional outcome scores above ( $p < 0.01$ ). This suggests that reported functional improvements hold true for each procedure despite significant differences in patient population. Additionally, using the MacNab score,  $\sim 80\%$  patient satisfaction overall was reported. Thus, functional outcome improvements mirror patient satisfaction reports with respect to each procedure. Differences in perioperative metrics such as EBL, Hospital-Stay, and Operative Time did not influence these findings.

The 3 main complications seen with the highest rates in our study were (1) dural tears, (2) incomplete decompression, and (3) epidural hematoma. Although dural tears had the highest proportion of the reported complications across the published studies, the overall dural tear rate was 2.23%, which is in the lower range of the previously reported incidence of dural tears in the literature (1.6 to 10%) [47–49]. Biportal discectomy had the lowest rate of dural tears at 1.8% while biportal TLIF had the highest rate at 2.1%, which is likely associated with the use of osteotomes to perform the facetectomy during the TLIF procedure. In contrast, biportal decompressions had the highest rates of inadequate decompression at 1.7%, which may be related to the surgeons' technique during their learning curve, which were included in many of the studies included in this analysis. Biportal studies included in the analysis are unique in that the vast majority of biportal cases had post-operative MRIs



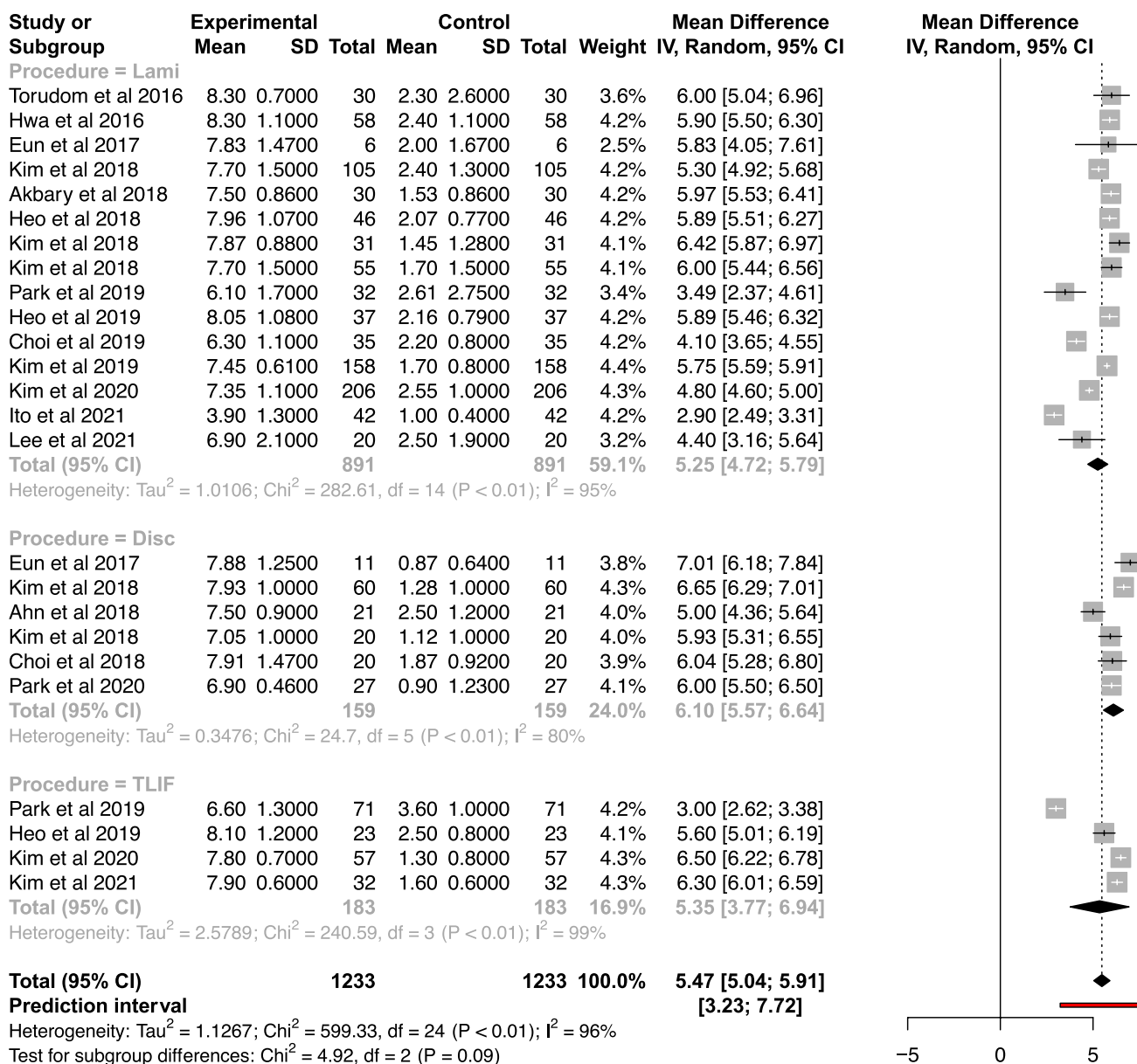
**Fig. 1** Mean Difference in VAS-Back Scores by Surgical Procedure. Analysis of Heterogeneity. Figure depicting meta-analysis of the VAS-Back Scores for each of the surgery types and the analysis of

heterogeneity. Improvement was demonstrated regardless of population heterogeneity or surgery type

for analysis, allowing us to determine an accurate rate of complications such as inadequate decompression. This rate is consistent with the rate of reoperation within 30 days after a standard lumbar laminectomy or discectomy (2.2%), which is the closest comparison in the literature since most studies do not routinely obtain post-operative MRIs to evaluate the surgical results [50].

The overall rate of epidural hematoma was 3.79% and was the highest in biportal TLIF at 2.4%, likely due to the increased bony resection required for TLIF leading to more bony bleeding into the epidural space. The paraspinal musculature and soft tissue envelope closes quite effectively after biportal endoscopy due to very small fascial incisions for the endoscope and working portal, potentially retaining any bleeding at the surgical site with reduced egress. In

addition, the hydrostatic pressure of the endoscopic fluid assists with hemostasis but once the endoscopic fluid is removed and the pressure dissipates, bleeding can occur within the laminotomy site, leading to a false sense of security. Strategies such as keeping the fluid pressure low, examining for sources of bleeding under endoscopic visualization with the fluid pressure off, and the use of a post-operative drain can mitigate the risk of post-operative epidural hematoma. With the strength of routine post-operative MRIs in these biportal studies, our study accurately reflects the incidence of post-operative epidural hematomas with biportal endoscopy, while other studies in the literature only report the incidence of symptomatic hematomas that require evacuation and likely underreport the true incidence [51].



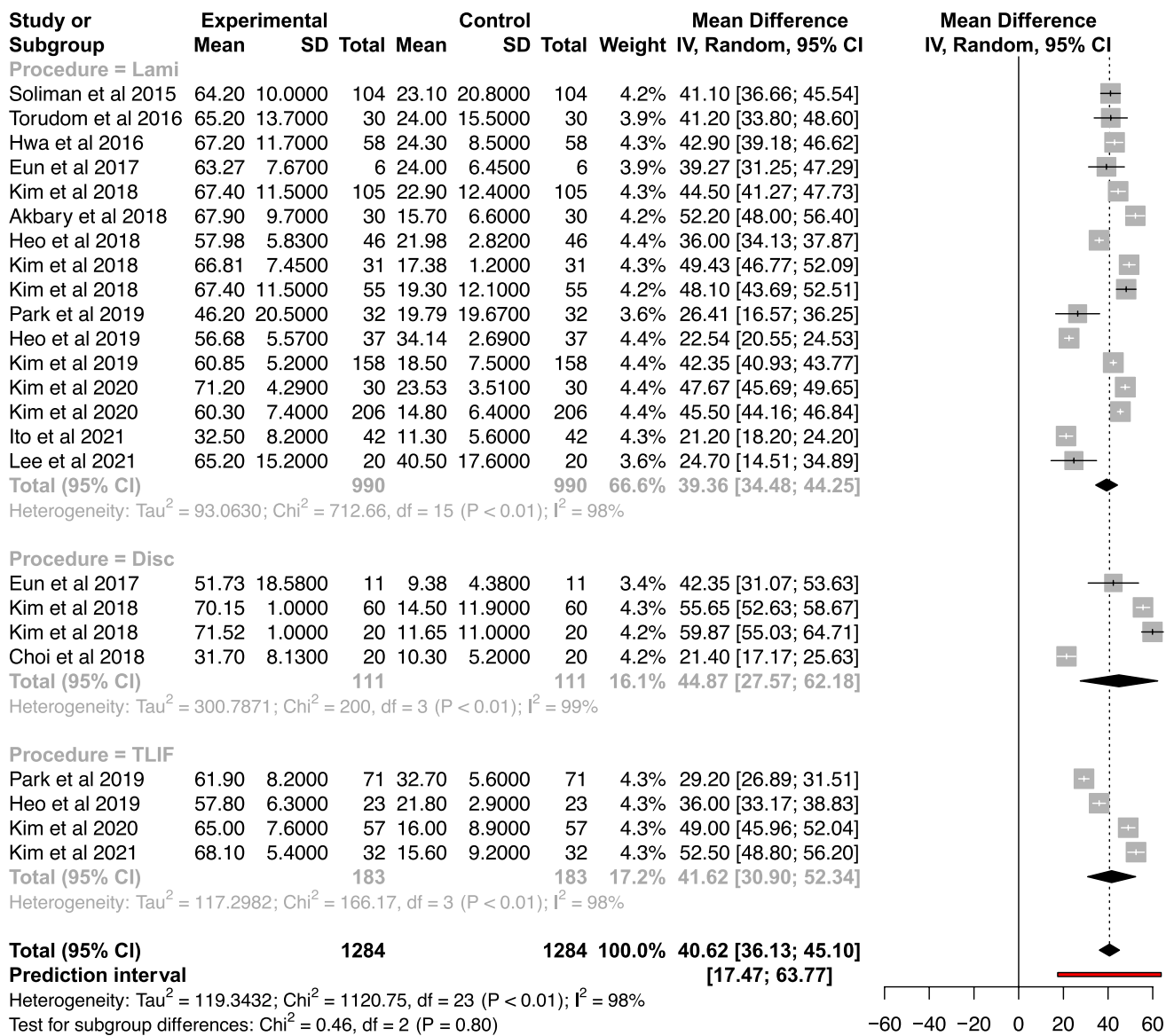
**Fig. 2** Mean Difference in VAS-Leg Scores by Surgical Procedure. Analysis of Heterogeneity Figure depicting meta-analysis of the VAS-Leg Scores for each of the surgery types and the analysis of het-

erogeneity. Improvement was demonstrated regardless of population heterogeneity or surgery type

Another important complication to consider is transient nerve root injury as this weigh heavily on the minds of many surgeons considering to learn the technique. Our study demonstrated that the rates were low with the lowest rate with biportal laminectomy decompression at 0%, biportal discectomy at 0.7%, and the highest rate seen with biportal TLIF at 0.9%. The endoscopic fluid creates hydrostatic pressure that helps gently displace the thecal sac and nerve roots away from the endoscope. This allows for more of a working space for the surgical instruments without significant retraction of the neural elements. Evaniew et al. performed

a meta-analysis on nerve root injuries after open lumbar discectomy, which resulted in a 2.25% rate and Mehta et al. demonstrated that TLIF had a 2% rate of post-operative nerve root injury [52, 53].

Biportal decompressions had the highest rate of iatrogenic instability with 0.6%, which may be correlated with performing the decompression with concomitant degenerative spondylolisthesis that may be at the cusp of instability. Despite the preservation of the posterior ligamentous complex and paraspinal muscular attachments, facet violation may not be avoidable to perform a complete decompression,



**Fig. 3** Mean Difference in ODI Scores by Surgical Procedure. Analysis of Heterogeneity. Figure depicting meta-analysis of the ODI Scores for each of the surgery types and the analysis of heterogeneity.

Improvement was demonstrated regardless of population heterogeneity or surgery type

hence leading to iatrogenic instability. However, the rates of iatrogenic instability were quite low in our study. As expected, the rate of post-operative infection was very low with only 3 total cases of the entire cohort, which is likely due to the constant flow of endoscopic irrigation through the surgical field and the ultra-minimally invasive nature of the technique. In all, our study demonstrated that the complication rates with biportal endoscopy are at least comparable or even lower than the published rates in the literature, demonstrating the safety of the technique.

There are several limitations to this study. (1) Utilizing heterogenous populations in our analysis for external publications exposes potential for publication bias. We attempted

to control for bias within PRISMA guidelines by selecting for primary clinical studies, analyzing only raw data. (2) There were less cases reported for the TLIF group. As such, despite attempting to control for heterogeneity, analyses may be underpowered for this particular surgical technique. (3) MRI was obtained postoperatively for the vast majority of patients who underwent biportal endoscopic surgeries in Korea. This artificially inflates the complication profile as the majority of the incomplete decompressions and epidural hematomas were asymptomatic and only noted due to available data from advanced imaging. This potentially overestimates the reported complications associated with biportal techniques. (4) Given the nature of systematic reviews and

meta-analyses in general, we are limited by the data presented in each article. Certain studies were excluded from analysis given absence data, or failures to report standard deviations, means, etc. However, this is likely due to the lack of literature within the field of endoscopic spine surgery globally. This relatively novel technique has remained in a unique niche, only recently introduced in the Western Hemisphere. Nonetheless, our findings show favorable results, which may help increase the employment of these techniques; increasing the likelihood of future quality comparative studies.

In conclusion, our study examining 3673 cases demonstrated that biportal spinal endoscopy is safe and effective. Complications are comparable or less than previously published rates with respect to open and microscopic techniques. Overall, durotomy, inadequate decompression, and epidural hematoma occur < 4% of the time. Clinical outcomes are promising with approximately 80% overall patient satisfaction and significant improvements in pain and disability scores postoperatively. Large, prospective studies are required to assess the efficacy of the technique as compared to traditional techniques; however, this comprehensive review and meta-analysis demonstrates that biportal spinal endoscopy can be successfully utilized in the lumbar spine.

## Declarations

**Conflict of interest** No funds, grants, or other support was received.

**Open Access** This article is licensed under a Creative Commons Attribution 4.0 International License, which permits use, sharing, adaptation, distribution and reproduction in any medium or format, as long as you give appropriate credit to the original author(s) and the source, provide a link to the Creative Commons licence, and indicate if changes were made. The images or other third party material in this article are included in the article's Creative Commons licence, unless indicated otherwise in a credit line to the material. If material is not included in the article's Creative Commons licence and your intended use is not permitted by statutory regulation or exceeds the permitted use, you will need to obtain permission directly from the copyright holder. To view a copy of this licence, visit <http://creativecommons.org/licenses/by/4.0/>.

## References

- Simpson AK, Lightsey HM 4th, Xiong GX, Crawford AM, Minamide A, Schoenfeld AJ (2022) Spinal endoscopy: evidence, techniques, global trends, and future projections. *Spine J* 22(1):64–74
- Heo DH, Lee DC, Park CK (2019) Comparative analysis of three types of minimally invasive decompressive surgery for lumbar central stenosis: biportal endoscopy, uniportal endoscopy, and microsurgery. *Neurosurg Focus* 46(5):E9. <https://doi.org/10.3171/2019.2.Focus197>
- Heo DH, Quillo-Olvera J, Park CK (2018) Can percutaneous biportal endoscopic surgery achieve enough canal decompression for degenerative lumbar stenosis? Prospective case-control study. *World Neurosurg* 120:e684–e689. <https://doi.org/10.1016/j.wneu.2018.08.144>
- Heo DH, Eum JH, Jo JY, Chung H (2021) Modified far lateral endoscopic transforaminal lumbar interbody fusion using a biportal endoscopic approach: technical report and preliminary results. *Acta Neurochir (Wien)* 163:1205–1209. <https://doi.org/10.1007/s00701-021-04758-7>
- Heo DH, Lee DC, Kim HS, Park CK, Chung H (2021) Clinical results and complications of endoscopic lumbar interbody fusion for lumbar degenerative disease: a meta-analysis. *World Neurosurg* 145:396–404. <https://doi.org/10.1016/j.wneu.2020.10.033>
- Soliman HM (2013) Irrigation endoscopic discectomy: a novel percutaneous approach for lumbar disc prolapse. *Eur Spine J* 22:1037–1044. <https://doi.org/10.1007/s00586-013-2701-0>
- Soliman HM (2015) Irrigation endoscopic decompressive laminotomy. A new endoscopic approach for spinal stenosis decompression. *Spine J* 15(10):2282–2289. <https://doi.org/10.1016/j.spinee.2015.07.009>
- Torudom Y, Dilokhuttakarn T (2016) Two portal percutaneous endoscopic decompression for lumbar spinal stenosis: preliminary study. *Asian Spine J* 10(2):335–342. <https://doi.org/10.4184/asj.2016.10.2.335>. (Epub 2016 Apr 15. PMID: 27114776 PMCID: PMC4843072)
- Hwa Eum J, Hwa Heo D, Son SK, Park CK (2016) Percutaneous biportal endoscopic decompression for lumbar spinal stenosis: a technical note and preliminary clinical results. *J Neurosurg Spine* 24(4):602–607. <https://doi.org/10.3171/2015.7.SPINE15304>. (Epub 2016 Jan 1 PMID: 26722954)
- Choi DJ, Choi CM, Jung JT, Lee SJ, Kim YS (2016) Learning curve associated with complications in biportal endoscopic spinal surgery: challenges and strategies. *Asian Spine J.* 10(4):624–629. <https://doi.org/10.4184/asj.2016.10.4.624>. (Epub 2016 Aug 16. PMID: 27559440 PMCID: PMC4995243)
- Eun SS, Eum JH, Lee SH, Sabal LA (2017) Biportal endoscopic lumbar decompression for lumbar disk herniation and spinal canal stenosis: a technical note. *J Neurol Surg A Cent Eur Neurosurg* 78(4):390–396. <https://doi.org/10.1055/s-0036-1592157>. (Epub 2016 Sep 21 PMID: 27652804)
- Kim SK, Kang SS, Hong YH, Park SW, Lee SC (2018) Clinical comparison of unilateral biportal endoscopic technique versus open microdiscectomy for single-level lumbar discectomy: a multicenter, retrospective analysis. *J Orthop Surg Res* 13(1):22. <https://doi.org/10.1186/s13018-018-0725-1>
- Ahn JS, Lee HJ, Choi DJ, Lee KY, Hwang SJ (2018) Extraforaminal approach of biportal endoscopic spinal surgery: a new endoscopic technique for transforaminal decompression and discectomy. *J Neurosurg Spine* 28(5):492–498. <https://doi.org/10.3171/2017.8.SPINE17771>. (Epub 2018 Feb 23 PMID: 29473790)
- Kim JE, Choi DJ (2018) Unilateral biportal endoscopic decompression by 30° endoscopy in lumbar spinal stenosis: Technical note and preliminary report. *J Orthop* 15(2):366–371. <https://doi.org/10.1016/j.jor.2018.01.039>. (PMID:29881155 PMCID:PMC5990374)
- Akbary K, Kim JS, Park CW, Jun SG, Hwang JH (2018) Biportal endoscopic decompression of exiting and traversing nerve roots through a single interlaminar window using a contralateral approach: technical feasibilities and morphometric changes of the lumbar canal and foramen. *World Neurosurg* 117:153–161. <https://doi.org/10.1016/j.wneu.2018.05.111>. (Epub 2018 May 29 PMID: 29857220)
- Kim JE, Choi DJ (2018) Bi-portal arthroscopic spinal surgery (BASS) with 30° arthroscopy for far lateral approach of L5–S1—Technical note. *J Orthop* 15(2):354–358. <https://doi.org/10.1016/j.jor.2018.01.034>. (PMID:29881152 PMCID:PMC5990375)
- Kang SS, Kim JE, Choi DJ, Park EJ (2019) Pseudomeningocele after biportal endoscopic spine surgery: a case report.



- J Orthop 18:1–4. <https://doi.org/10.1016/j.jor.2019.10.004>. (PMID:32189874 PMID:PMC7068011)
18. IS, Han SY, Chung HJ, Hong JE, Kang MS. (2021) Unstable non-isthmic spondylolisthesis following unilateral biportal endoscopy assisted unilateral laminotomy for bilateral decompression: a case report. *Malays Orthop J* 15(3):147–151. <https://doi.org/10.5704/MOJ.2111.025>. (PMID:34966512 PMID:PMC8667255)
  19. Hong YH, Kim SK, Hwang J, Eum JH, Heo DH, Suh DW, Lee SC (2021) Water dynamics in unilateral biportal endoscopic spine surgery and its related factors: an in vivo proportional regression and proficiency-matched study. *World Neurosurg* 149:e836–e843. <https://doi.org/10.1016/j.wneu.2021.01.086>. (Epub 2021 Feb 2 PMID: 33540105)
  20. Aygun H, Abdulshafi K (2021) Unilateral biportal endoscopy versus tubular microendoscopy in management of single level degenerative lumbar canal stenosis: a prospective study. *Clin Spine Surg* 34(6):E323–E328. <https://doi.org/10.1097/BSD.0000000000001122>. (PMID:33470660 PMID:PMC8225231)
  21. Jiang HW, Chen CD, Zhan BS, Wang YL, Tang P, Jiang XS (2022) Unilateral biportal endoscopic discectomy versus percutaneous endoscopic lumbar discectomy in the treatment of lumbar disc herniation: a retrospective study. *J Orthop Surg Res* 17(1):30. <https://doi.org/10.1186/s13018-022-02929-5>. (PMID:35033143 PMID:PMC8760683)
  22. Kang MS, Park HJ, Hwang JH, Kim JE, Choi DJ, Chung HJ (2020) Safety evaluation of biportal endoscopic lumbar discectomy: assessment of cervical epidural pressure during surgery. *Spine* 45(20):E1349–E1356. <https://doi.org/10.1097/BRS.0000000000003585>. (PMID: 32969993)
  23. Kim JE, Choi DJ, Kim MC, Park EJ (2019) Risk factors of post-operative spinal epidural hematoma after biportal endoscopic spinal surgery. *World Neurosurg* 129:e324–e329. <https://doi.org/10.1016/j.wneu.2019.05.141>. (Epub 2019 May 31 PMID: 31158548)
  24. Ahn DK, Lee JS, Shin WS, Kim S, Jung J (2021) Postoperative spinal epidural hematoma in a biportal endoscopic spine surgery. *Medicine (Baltimore)* 100(6):e24685. <https://doi.org/10.1097/MD.00000000000024685>. (PMID: 33578600)
  25. Kim W, Kim SK, Kang SS, Park HJ, Han S, Lee SC (2020) Pooled analysis of unsuccessful percutaneous biportal endoscopic surgery outcomes from a multi-institutional retrospective cohort of 797 cases. *Acta Neurochir (Wien)* 162(2):279–287. <https://doi.org/10.1007/s00701-019-04162-2>. (Epub 2019 Dec 9 PMID: 31820196)
  26. Kang MS, You KH, Choi JY, Heo DH, Chung HJ, Park HJ (2021) Minimally invasive transforaminal lumbar interbody fusion using the biportal endoscopic techniques versus microscopic tubular technique. *Spine J* 21(12):2066–2077. <https://doi.org/10.1016/j.spinee.2021.06.013>. (Epub 2021 Jun 23 PMID: 34171465)
  27. Park SM, Kim HJ, Kim GU, Choi MH, Chang BS, Lee CK, Yeom JS (2019) Learning curve for lumbar decompressive laminectomy in biportal endoscopic spinal surgery using the cumulative summation test for learning curve. *World Neurosurg* 122:e1007–e1013. <https://doi.org/10.1016/j.wneu.2018.10.197>. (Epub 2018 Nov 4 PMID: 30404053)
  28. Kim HS, Choi SH, Shim DM, Lee IS, Oh YK, Woo YH (2020) Advantages of new endoscopic unilateral laminectomy for bilateral decompression (ULBD) over conventional microscopic ULBD. *Clin Orthop Surg* 12(3):330–336. <https://doi.org/10.4055/cios19136>. (Epub 2020 Jun 29. PMID: 32904063 PMID: PMC7449863)
  29. Park S-M, Park J, Jang Ho, Heo Y, Han H, Kim H-J, Chang B-S, Lee C-H, Yeom JS (2019) Biportal endoscopic versus microscopic lumbar decompressive laminectomy in patients with spinal stenosis: a randomized controlled trial. *The Spine Journal*. <https://doi.org/10.1016/j.spinee.2019.09.015>
  30. Kim JE, Choi DJ, Park EJ (2018) Clinical and radiological outcomes of foraminal decompression using unilateral biportal endoscopic spine surgery for lumbar foraminal stenosis. *Clin Orthop Surg* 10(4):439–447. <https://doi.org/10.4055/cios.2018.10.4.439>. (Epub 2018 Nov 21. PMID: 30505412 PMID: PMC6250968)
  31. Park MK, Park SA, Son SK, Park WW, Choi SH (2019) Clinical and radiological outcomes of unilateral biportal endoscopic lumbar interbody fusion (ULIF) compared with conventional posterior lumbar interbody fusion (PLIF): 1-year follow-up. *Neurosurg Rev* 42(3):753–761. <https://doi.org/10.1007/s10143-019-01114-3>. (Epub 2019 May 29. Erratum in: *Neurosurg Rev*. 2019 Jun 24 PMID: 31144195)
  32. Ito Z, Shibayama M, Nakamura S, Yamada M, Kawai M, Takeuchi M, Yoshimatsu H, Kuraishi K, Hoshi N, Miura Y, Ito F (2021) Clinical comparison of unilateral biportal endoscopic laminectomy versus microendoscopic laminectomy for single-level laminectomy: a single-center. Retrospective Analysis *World Neurosurg* 148:e581–e588. <https://doi.org/10.1016/j.wneu.2021.01.031>. (Epub 2021 Jan 19 PMID: 33476779)
  33. Kim JE, Choi DJ (2018) Clinical and radiological outcomes of unilateral biportal endoscopic decompression by 30° arthroscopy in lumbar spinal stenosis: minimum 2-year follow-up. *Clin Orthop Surg* 10(3):328–336. <https://doi.org/10.4055/cios.2018.10.3.328>. (Epub 2018 Aug 22. PMID: 30174809 PMID: PMC6107815)
  34. Lee HJ, Park EJ, Ahn JS, Kim SB, Kwon YS, Park YC (2021) Clinical outcomes of biportal endoscopic interlaminar decompression with oblique lumbar interbody fusion (OLIF): comparative analysis with TLIF. *Brain Sci* 11(5):630. <https://doi.org/10.3390/brainsci11050630>. (PMID:34068334 PMID:PMC8153266)
  35. Kim JE, Yoo HS, Choi DJ, Park EJ, Jee SM (2021) Comparison of minimal invasive versus biportal endoscopic transforaminal lumbar interbody fusion for single-level lumbar disease. *Clin Spine Surg* 34(2):E64–E71. <https://doi.org/10.1097/BSD.00000000000001024>. (PMID:33633061 PMID:PMC8035997)
  36. Choi KC, Shim HK, Hwang JS, Shin SH, Lee DC, Jung HH, Park HA, Park CK (2018) comparison of surgical invasiveness between microdiscectomy and 3 different endoscopic discectomy techniques for lumbar disc herniation. *World Neurosurg* 116:e750–e758. <https://doi.org/10.1016/j.wneu.2018.05.085>. (Epub 2018 May 19 PMID: 29787880)
  37. Park JH, Jang JW, Park WM, Park CW (2020) Contralateral key-hole biportal endoscopic surgery for ruptured lumbar herniated disc: a technical feasibility and early clinical outcomes. *Neurospine* 17(Suppl 1):S110–S119. <https://doi.org/10.14245/ns.2040224.112>. (PMID:32746524 PMID:PMC7410376)
  38. Park HJ, Kim SK, Lee SC, Kim W, Han S, Kang SS (2020) Dural tears in percutaneous biportal endoscopic spine surgery: anatomical location and management. *World Neurosurg* 136:e578–e585. <https://doi.org/10.1016/j.wneu.2020.01.080>. (Epub 2020 Jan 17 PMID: 31958589)
  39. Kim JE, Yoo HS, Choi DJ, Park EJ, Hwang JH, Suh JD, Yoo JH (2020) Effectiveness of gelatin-thrombin matrix sealants (flo-seal®) on postoperative spinal epidural hematoma during single-level lumbar decompression using biportal endoscopic spine surgery: clinical and magnetic resonance image study. *Biomed Res Int* 2020:4801641. <https://doi.org/10.1155/2020/4801641>. (PMID:32695815 PMID:PMC7368184)
  40. Choi DJ, Kim JE (2019) Efficacy of biportal endoscopic spine surgery for lumbar spinal stenosis. *Clin Orthop Surg* 11(1):82–88. <https://doi.org/10.4055/cios.2019.11.1.82>. (Epub 2019 Feb 18. PMID: 30838111 PMID: PMC6389528.)
  41. Kim JE, Choi DJ, Park EJ (2019) Evaluation of postoperative spinal epidural hematoma after biportal endoscopic spine surgery for single-level lumbar spinal stenosis: clinical and magnetic resonance imaging study. *World Neurosurg* 126:e786–e792.

- <https://doi.org/10.1016/j.wneu.2019.02.150>. (Epub 2019 Mar 14 PMID: 30878758)
42. Kang T, Park SY, Kang CH, Lee SH, Park JH, Suh SW (2019) Is biportal technique/endoscopic spinal surgery satisfactory for lumbar spinal stenosis patients?: a prospective randomized comparative study. *Medicine (Baltimore)* 98(18):e15451. <https://doi.org/10.1097/MD.00000000000015451>
  43. Kim JE, Yoo HS, Choi DJ, Hwang JH, Park EJ, Chung S (2020) learning curve and clinical outcome of biportal endoscopic-assisted lumbar interbody fusion. *Biomed Res Int* 2020:8815432. <https://doi.org/10.1155/2020/8815432>. (PMID:33381586 PMID:PMC7762649)
  44. Balduzzi S, Rucker G, Schwarzer G (2019) How to perform a meta-analysis with R: a practical tutorial. *Evid Based Ment Health* 22:153–160
  45. Bates D, Maechler M, Bolker B, Walker S (2015) Fitting linear mixed-effects models using lme4. *J Stat Softw* 67(1):1–48. <https://doi.org/10.18637/jss.v067.i01>
  46. Williams BJ, Sansur CA, Smith JS, Berven SH, Broadstone PA, Choma TJ, Goytan MJ, Noordeen HH, Knapp DR Jr, Hart RA, Zeller RD, Donaldson WF 3rd, Polly DW Jr, Perra JH, Boachie-Adjei O, Shaffrey CI (2011) Incidence of unintended durotomy in spine surgery based on 108,478 cases. *Neurosurgery* 68(1):117–123. <https://doi.org/10.1227/NEU.0b013e3181fcf14e>. (PMID: 21150757)
  47. Choi DJ, Kim JE, Jung JT, Kim YS, Jang HJ, Yoo B, Kang IH (2018) Biportal endoscopic spine surgery for various foraminal lesions at the lumbosacral lesion. *Asian Spine J.* 12(3):569–573. <https://doi.org/10.4184/asj.2018.12.3.569>. (Epub 2018 Jun 4. PMID: 29879787 PMID: PMC6002165.)
  48. Baker GA, Cizik AM, Bransford RJ, Bellabarba C, Konodi MA, Chapman JR, Lee MJ (2012) Risk factors for unintended durotomy during spine surgery: a multivariate analysis. *Spine J* 12(2):121–126. <https://doi.org/10.1016/j.spinee.2012.01.012>. (Epub 2012 Feb 18. PMID: 22342249 PMID: PMC3299921)
  49. Yoshihara H, Yoneoka D (2014) Incidental dural tear in spine surgery: analysis of a nationwide database. *Eur Spine J* 23(2):389–394. <https://doi.org/10.1007/s00586-013-3091-z>. (Epub 2013 Nov 9. PMID: 24212480 PMID: PMC3906460)
  50. Samuel AM, Morse K, Lovecchio F, Maza N, Vaishnav AS, Katsura Y, Iyer S, McAnany SJ, Albert TJ, Gang CH, Qureshi SA (2021) Early failures after lumbar discectomy surgery: an analysis of 62 690 patients. *Global Spine J.* 11(7):1025–1031. <https://doi.org/10.1177/2192568220935404>. (Epub 2020 Jul 17. PMID: 32677471 PMID: PMC8351058)
  51. Aono H, Ohwada T, Hosono N, Tobimatsu H, Ariga K, Fuji T, Iwasaki M (2011) Incidence of postoperative symptomatic epidural hematoma in spinal decompression surgery. *J Neurosurg Spine* 15(2):202–205. <https://doi.org/10.3171/2011.3.SPINE.10716>. (Epub 2011 May 6 PMID: 21529204)
  52. Evaniew N, Khan M, Drew B, Kwok D, Bhandari M, Ghert M (2014) Minimally invasive versus open surgery for cervical and lumbar discectomy: a systematic review and meta-analysis. *CMAJ Open* 2(4):E295–305. <https://doi.org/10.9778/cmajo.20140048>. PMID:25485257;PMCID:PMC4251505
  53. Mehta VA, McGirt MJ, Garcés Ambrossi GL, Parker SL, Sciubba DM, Bydon A, Wolinsky JP, Gokaslan ZL, Witham TF (2011) Trans-foraminal versus posterior lumbar interbody fusion: comparison of surgical morbidity. *Neurol Res* 33(1):38–42. <https://doi.org/10.1179/016164110X12681290831289>. (Epub 2010 Jun 11 PMID: 20546682)

**Publisher's Note** Springer Nature remains neutral with regard to jurisdictional claims in published maps and institutional affiliations.