

Perioperative management and outcome of patients with Rett syndrome undergoing scoliosis surgery: a retrospective review

Iosifina Karmanioliou · Ramprabu Krishnan ·
Eleanor Galtrey · Stuart Cleland ·
Ramesh Vijayaraghavan

Received: 12 September 2014 / Accepted: 4 January 2015 / Published online: 24 January 2015
© Japanese Society of Anesthesiologists 2015

Abstract

Background Rett syndrome is a rare genetically inherited neuromuscular disorder exclusively affecting female patients. Progressive scoliosis is one of the main features of the disease and affected individuals are very likely to need spine correction surgery.

Methods We undertook a retrospective notes review of patients with Rett syndrome who had undergone spine surgery from 2005 to 2013. Patients were identified through the hospital's electronic records. The aim of the present study was to identify the anesthetic implications encountered and the perioperative adverse events, in an effort to improve perioperative management and reduce complications.

Result We identified twenty-four children who had 29 procedures in total in this period. Frequent chest infections and poorly controlled epilepsy were the main preoperative findings. There were no adverse events during induction and intubation. Common anesthetic/analgesic drugs were used throughout. Postoperatively, gastrointestinal and respiratory tract complications were the most common. Mean intensive care unit stay was 8.1 days and mean time to discharge from hospital was 26.5 days. We had one in-hospital death.

Conclusions Our case series demonstrates a high incidence of complications in this subpopulation, mainly

postoperative. Extreme postoperative vigilance is required and recovery in a high dependency unit is highly recommended.

Keywords Anesthesia · Rett syndrome · Scoliosis · Spinal fusion

Introduction

Rett syndrome is a rare genetically inherited neuromuscular disorder, with an estimated incidence of 1:10,000, affecting exclusively female patients [1]. One of the main characteristics of the disease is the progressive loss of previously acquired cognitive, social and motor milestones at the age of 6–18 months in children with apparently normal milestone achievements until then. Other features comprise epilepsy, stereotypic hand movements, autistic behavior, abnormal respiratory patterns, gastroesophageal reflux, nutrition issues and severe scoliosis [2, 3]. Mutations in the *MECP2* gene, associated with a structural defect in the short arm of the X chromosome, are found to be implicated in most of the patients with the syndrome. Due to the high incidence and the severe degree of progressive scoliosis these children are very likely to undergo spinal fusion. In fact, nearly half of the patients will need operation as the curvature worsens [4]. The aforementioned pre-existing disease-related abnormalities, mainly relating to respiratory and gastrointestinal systems, mean that the management of patients with Rett syndrome is challenging with a high risk of perioperative complications [5]. Due to the rarity of the disease, the current information comes mainly from case reports and case series, the latter focusing mainly on surgical outcome [2, 4]. The aim of the present study was to identify the anesthetic

I. Karmanioliou (✉)
Pentelis Children's Hospital, Ippokratous 8, Penteli,
15236 Athens, Greece
e-mail: zozefina_k@hotmail.com

R. Krishnan · E. Galtrey · S. Cleland · R. Vijayaraghavan
Royal National Orthopaedic Hospital, Brockley Hill, Stanmore,
Middlesex HA7 4LP, UK

difficulties encountered and the perioperative adverse events of patients with Rett syndrome undergoing spine surgery, in an effort to improve perioperative management and reduce complications.

Methods

Local Ethics Committee approval was applied for, but was not deemed necessary for the present study by our hospital committee (SE12.021). All patients with Rett syndrome who had scoliosis surgery in the period 2005–2013 were identified from the hospital's registration system and were included in the study. The search resulted in 25 anesthetic charts/notes. The records of these eligible patients were reviewed by the authors and the data were entered into a standardized form. One patient was excluded from the study as she was diagnosed with Chiari malformation instead of Rett syndrome. Procedures other than spine surgery, such as general anesthesia for tracheostomy, were not included.

We evaluated the preoperative assessment details, premedication, type of anesthesia and the main postoperative outcome and complications. The preoperative assessment focused on the presence of epilepsy and the degree of control, the frequency of chest infections, the cardiovascular status and any other existing co-morbidity. We also recorded the preoperative blood pressure, heart rate and oxygen saturation (SpO_2). Blood investigations included hemoglobin, white blood cell count, platelets, sodium, potassium, blood urea nitrogen (BUN) and creatinine.

Intraoperative data recorded included the drugs used for induction and maintenance of anesthesia and analgesia. Intraoperative blood loss, amount and types of intravenous fluids administered, use of tranexamic acid and cell salvage, and somatosensory evoked potentials (SSEP) monitoring were also recorded. Postoperatively, we recorded all complications as well as the number of days spent in high dependency unit (HDU)/intensive care unit (ICU), days until discharge from hospital and in-hospital mortality. A high dependency ("level 2") unit is an area in a hospital where patients can be cared for more extensively than on a normal ward, but not to the point of intensive care. Level 2 care is defined as "more detailed observations or intervention including support for a single failing organ system or postoperative care and those 'stepping down' from higher levels of care".

Data are presented as mean values \pm standard deviation (SD) or percentages when applicable. A two-sample *t* test was used for comparison between subgroups. $P < 0.05$ was considered statistically significant. For skewed data, median values are also presented in brackets.

Results

We identified 24 children with Rett syndrome who underwent 29 procedures between 2005 and 2013. Procedures comprised 16 single-stage posterior fusions and 3 single-stage anterior fusions, while 5 patients had a two-stage operation (anterior and posterior). Mean age was 15.2 ± 3.4 years (range 10–22 years). All were conducted by experienced pediatric anesthetists and specialized spine surgeon consultants. The anesthetic chart was missing in one patient.

Patient characteristics, preoperative vital signs and blood test results are shown in Table 1. Cardiovascular abnormalities were identified in two patients only. One of them had mitral valve prolapse and the other had transposition of the great arteries which had been repaired in early childhood and good ventricular function was confirmed by echocardiography. Of the 24 patients, 12 (50 %) had a history of frequent respiratory tract infections defined as 4 or more episodes in a year, among whom 4 patients needed nebulizers at home. Eighteen children had epilepsy (75 %). Of these, 6 were on triple antiepileptic treatment, 5 were receiving two different medications, 6 were only having one antiepileptic drug and 1 patient was not on any regular medication. Regarding feeding, 8 children (33.3 %) had normal oral intake, 10 were able to eat semi-solid food only and 6 were fed through percutaneous endoscopic gastrostomy (PEG). Among the 24 patients, 11 (45.8 %) were wheelchair-bound, 5 were able to stand but not walk, only 6 could walk and data were missing for 2 patients. No premedication was given in any of the patients.

Both inhalational and intravenous induction was used with a variety of neuromuscular blocking agents, analgesics and adjuvants administered intraoperatively (Table 2). The

Table 1 Patients' characteristics, preoperative vital signs and blood tests results

Age (years)	15.2 \pm 3.4 [14]
Weight (kg)	34.4 \pm 7.2
HR (beats/min)	93 \pm 12 [96]
BP (mmHg)	103 \pm 12/61 \pm 9
SpO_2 (%)	97 \pm 2
Na^+ (mmol/L)	139 \pm 2
K^+ (mmol/L)	4.0 \pm 0.4
Blood urea nitrogen (BUN) (mmol/L)	4.6 \pm 4.3 [3.45]
Creatinine ($\mu\text{mol/L}$)	41.9 \pm 17.1 [45]
Hb (g/dl)	12.5 \pm 1.1
WBC ($\times 10^9/\text{L}$)	7.2 \pm 1.9
PLT ($\times 10^9/\text{L}$)	242 \pm 62

Values are expressed as mean \pm SD. For skewed data median values are included in brackets

Table 2 Induction, maintenance, analgesic and adjuvants administered

	Number of patients
Induction	
Sevoflurane	13
Propofol	12
N/A	4
Maintenance	
Desflurane	16
Isoflurane	8
Sevoflurane	2
Propofol	0
N/A	3
Muscle relaxant	
Vecuronium	24
Rocuronium	3
N/A	2
Opioid	
Remifentanyl	25
Morphine	21
Fentanyl	5
N/A	3
Other	
Ketamine	2
Clonidine	13
Paracetamol	20
Tranexamic acid	14

N/A not available

minimum alveolar concentration (MAC) was used as a guide for anesthetic depth as a bispectral index (BIS) monitor was not available in our institute. Sixteen patients (66.7 %) were classified as grade 1 Cormack–Lehane laryngoscopy view, 3 (12.5 %) as grade 2 and only 1 (4.2 %) as grade 3. Data were not available for 4 patients. For the patient with grade 3 view, the trachea was intubated using a gum elastic bougie. Difficult intubation was attributed to microcephaly and repaired cleft palate rather than the syndrome itself. This same patient suffered from multiple desaturation episodes when re-intubated in ICU in an emergency setting. Somatosensory evoked potentials (SSEPs) were monitored in all procedures, but data were missing in two cases. The only finding was small amplitude traces in one girl. Data on intraoperative blood loss and fluid replacement are presented in Table 3. One patient suffered intraoperative cardiac arrest just before the end of the surgical procedure. Return of spontaneous circulation (ROSC) after cardiopulmonary resuscitation (CPR) was achieved and the patient was transferred to ICU with an endotracheal tube in situ.

All patients were electively admitted to HDU/ICU postoperatively. Ten (34.5 %) patients were electively ventilated

Table 3 Intraoperative blood loss and fluid replacement

Total blood loss (ml)	1160 ± 835
Blood loss in relation to TA administration (ml)	
With TA	1507 ± 816 [1500] p = 0.08
Without TA	856 ± 836 [475]
Fluids administered (ml)	
Crystalloids	1169
Colloids	750
Autologous blood transfused (ml) (number of patients: 16 or 55 %)	549 ± 305 [540]
Homologous red blood cells transfused (units) (number of patients: 14 or 48 %)	2.2 ± 1.16 [2]

Values are expressed as mean ± SD. For skewed data median values are included in brackets

TA tranexamic acid

after the surgical procedure. The mean time of mechanical ventilation was 4.1 ± 6.0 (range 1–22 days). The reasons were respiratory issues in 5 patients, intraoperative blood loss in 4 patients and intraoperative cardiac arrest with return of spontaneous circulation (ROSC) after cardiopulmonary resuscitation (CPR) in 1 individual. This latter patient had subsequent cardiac arrest episodes and died on the first postoperative day. A postmortem conducted on the patient could not identify the cause of death. The probable cause of death was blood loss (1.5 times the total circulating volume) and hyperkalemia induced by massive blood transfusion. Five patients (21 %) had to be re-intubated in ICU. The reasons were pneumonia in 3 patients, lung collapse in one and post-extubation aspiration in one. Tracheostomy was carried out in 4 patients (13.7 %) and mean duration was 19.5 ± 4.1 days (range 16–25 days). Failure of weaning from mechanical ventilation was secondary to chest infection in 3 and aspiration in 1 patient. The remaining postoperative complications are described in Table 4. In total, the common postoperative complications involved the gastrointestinal tract (14 episodes, 48.3 %) and the respiratory system (13 episodes, 44.8 %). Five patients (21 %) had to be re-admitted to ICU after discharge to the ward. The reasons for re-admission were chest infection in 4 patients and probable aspiration in 1. One patient had to be re-intubated, 1 patient needed noninvasive ventilation and the others were conservatively managed with antibiotics and monitoring. Mean total ICU days were 8.1 ± 8.7 [median 6] and mean days to discharge were 26.5 ± 19.6 [median 21]. When patients were sub-divided into single-posterior, single-anterior and two-stage operation groups, mean HDU days were 9.4 ± 10.2 [median 6], 15 ± 8.2 [median 17], and 8 ± 7.4 [median 5], respectively (Fig. 1). Similarly, total days to discharge were 27 ± 23.8 [median 20], 21.3 ± 10.0 [median 22], and 28.2 ± 8.13 [median 26], respectively (Fig. 2).

Table 4 Main postoperative complications after spinal fusion in Rett syndrome patients

Complication	Number of patients
Pyrexia	12
Feeding issues (total)	9
Nasogastric tube insertion needed	5
Total parenteral nutrition (TPN)	4
Persistent vomiting	8
Pneumonia	6
Continuous positive airway pressure (CPAP) needed	6
Seizures	4
Inadequate pain control	4
Aspiration	3
Clotting disorders	2
Wound infection	1

Discussion

Scoliosis can affect 50–75 % of patients with Rett syndrome [6, 7]. Since the curvature is usually severe and progressive, surgical correction is often required. Indications for surgery include a curve greater than 40–45°, pain or loss of function [4]. Long-term benefits include improvement in posture and digestion and reduction in the frequency/severity of respiratory tract infections [4]. The perioperative risks and the potential for long-term benefit have to be

weighed before the final decision. In our case, a multidisciplinary team participated from a preoperative evaluation to postoperative management, and all cases were managed postoperatively in HDU/ICU.

Preoperative evaluation

All the patients were admitted preoperatively as inpatients to facilitate evaluation by a multidisciplinary team including surgeons, anesthetist, intensivist, paediatrician, physiotherapist and dietician. Evaluation of the respiratory status is crucial in patients with Rett syndrome. The chest was evaluated by anaesthetists, paediatricians and intensivists. There is a wide spectrum of breathing disorders which include periods of hyperventilation, hypoventilation, breath holding, apneic episodes and Valsalva maneuvers [8]. Usually, apneic events alternate with hyperventilation and irregular breathing. The breathing disorders along with the severe degree of scoliosis result in frequent chest infections. This finding was confirmed in our study, as almost half of the patients suffered from recurrent respiratory tract infections. Our medical history was as detailed as possible in an effort to identify every aspect of the aforementioned pre-existing respiratory defects. More specific evaluation needing patients’ cooperation remains challenging and mostly impossible. Therefore, spirometry results were scarce. Similarly, airway assessment was deficient.

From the cardiovascular point of view, only two patients had a pre-existing cardiac abnormality. Exercise tolerance

Fig. 1 Days spent in HDU according to the type of operation. HDU high dependency unit

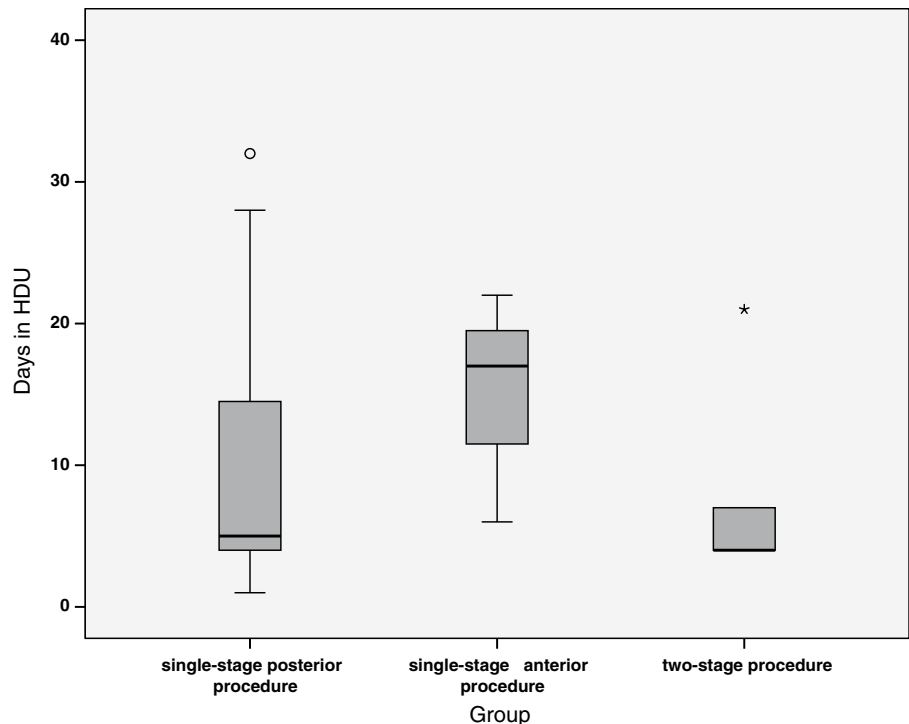
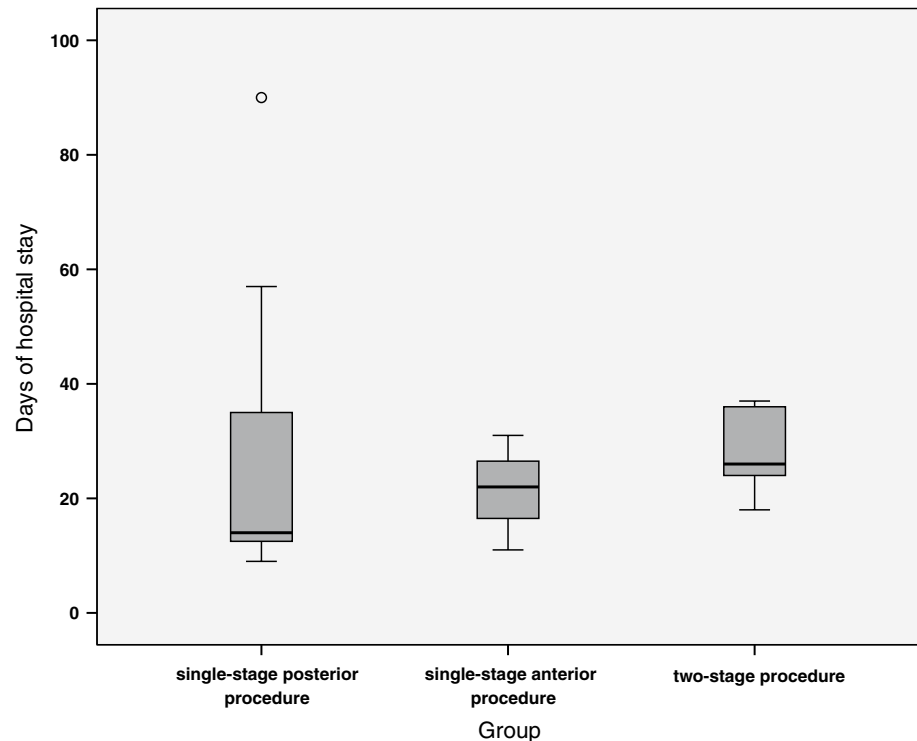


Fig. 2 Days of hospital stay according to the type of operation



was not evaluated as mobility is limited. Specifically, almost half of the patients were wheelchair-bound. Nevertheless, the possibility of structural cardiac defects is not high in this population. However, cardiac conduction abnormalities, prolonged QTc, T-wave abnormalities and severe bradycardia have been reported [9–11]. In our series of patients, we did not notice any adverse event due to cardiac abnormalities in the perioperative period, and, similarly to other case series, no long QTc was found in any of the subjects [10]. However, we cannot ignore the necessity of vigilance with QT-prolonging drugs.

Seizures are present in the majority of patients and characteristically about 46 % are resistant to medication [12]. This finding was again confirmed in our study. Seizures may be even more difficult to manage in the perioperative period and special attention to optimum preoperative control should be given.

Feeding issues are encountered in the vast majority of affected patients. Among these, of particular importance is the presence of vomiting/gastroesophageal reflux and subsequent potential aspiration [5]. No information exists as to whether rapid sequence induction would be prudent, but it seems that if the patients are adequately fasted the risk of aspiration during induction is not common [5]. No studies, including ours, have reported regurgitation and/or aspiration during induction [5]. The preoperative nutritional status, on the other hand, has an impact on the recovery process and should be assessed thoroughly before the planned surgery. Expert consensus is that preoperative nutritional

status should include body mass index, hemoglobin, electrolytes, albumin and white blood cell count [9]. We did not find any electrolyte or white cell count abnormalities, hemoglobin was normal, while body mass index and albumin were not extracted from the patients' notes. However, dieticians, part of the team, also assessed all patients preoperatively in an attempt to optimize any nutritional deficits and minimize postoperative complications.

Airway and anesthesia/intraoperative complications

The risk of difficult intubation, mainly associated with micrognathia and trismus, has been underlined in the past [13]. Limited mouth opening, due to which fiberoptic intubation was carried out, has also been reported recently [14]. In our case series, there was no difficult intubation during induction and only one patient needed intubation with gum elastic bougie.

The type and dose of drugs used were no different from the current anesthetic practice for the general pediatric population. Even though autonomic dysfunction may exist [9, 15], we did not have any marked hypotension or other incident during induction. Some authors claim that affected patients have reduced analgesic requirements [9], but we did not confirm this finding. Doses of opioids, adjusted to body weight, were similar to the general population. Moreover, we did not encounter any incidence of delayed awakening from anesthesia, even though this has been reported in the past [3, 16]. In a case report by Kim et al. [3],

continuous propofol (100–125 $\mu\text{g}/\text{kg}/\text{min}$) and remifentanyl (0.1–0.15 $\mu\text{g}/\text{kg}/\text{min}$), monitored by BIS (30–45), was administered for 6.5 h and the patient's trachea was extubated 4 h after the procedure. Normal awakening times are reported in most subsequent recent studies [7, 17, 18]. BIS can be a successful tool for anesthesia depth monitoring in such cases [3, 9].

SSEPs were monitored in all cases. Since epilepsy was a relative contraindication to motor evoked potentials (MEPs), these were omitted, in agreement with the surgical team, although it is well-known that the combination of SSEPs and MEPs provides the best results [19]. Currently, MEPs are also advised in Rett syndrome patients undergoing spine surgery [9]. The reliability of SSEPs alone, especially in Rett syndrome patients, is relatively unknown, but they are still recommended [9]. A recent retrospective study of a limited number of cases (7 patients/8 procedures) showed promising results and good correlation between SSEPs and neurological injury, but more studies are needed [19]. Low-amplitude waveforms have been seen in patients with Rett syndrome, but not consistently. In our study, normal baseline traces were obtained in all but one child who demonstrated low-amplitude traces, which were not correlated with spinal cord/nerve injury.

Intraoperative bleeding is always a risk in spinal fusion surgery with high perioperative transfusion rates [20]. The risk of hemorrhage was discussed with the surgical team before the operation and in cases of high risk the cell saver was used in theatre. Tranexamic acid was administered in 14 of the 29 procedures. It is not yet clear, however, whether its use offers any protection against red blood cell transfusion in neuromuscular scoliosis correction and our study was too small to add any information to elucidate [20, 21].

Postoperative complications/outcome

The recommendations are postoperative monitoring in intensive care setting due to a high complication rate [9]. Feeding difficulties, respiratory complications and pain control are some of the well-recognized issues that may be encountered. In our study, the most commonly encountered complications involved the gastrointestinal and the respiratory systems. The respiratory complications had a greater impact on the hospital stay than the gastrointestinal ones, which were minor like vomiting and can be treated easily.

Similarly, in a case–control study by Gabos et al. [2], respiratory complications were the most common in patients with Rett syndrome, comprising 61 % of all major complications. In this study, 6 of the total of 16 patients developed pneumonia postoperatively and 2 had to be re-intubated due to low oxygen saturation associated with underlying pulmonary disease. In our case series, there was

a 21 % re-intubation rate and readmission to ICU, predominantly due to pneumonia. 13 % of the patients needed tracheostomy due to prolonged mechanical ventilation. Irregular breathing with low tidal volumes has been reported even after minor procedures [11]. Aggressive chest physiotherapy is mandatory [9]. Non-invasive positive pressure airway support is very likely to be needed and should be applied early [9]. 25 % of the patients needed noninvasive ventilator support in our case series.

Out of 18 patients with pre-existing seizures, 4 had seizures postoperatively. Of those, 3 had poorly controlled epilepsy with seizures every week and only one had better control with seizures less frequently than once a month. Patients suffering from poorly controlled seizures are at increased risk of postoperative deterioration. To this end, pharmacological control should be optimized preoperatively.

Analgesia should be carefully titrated in order to avoid any degree of respiratory depression. Ideally, a specialist team should be involved in the first 24 h [9]. Analgesia issues are common, especially due to lack of communication, and parental input should be taken into consideration. Multimodal analgesia, including paracetamol, ketamine and/or small doses of clonidine, could also be of help in reducing opioid requirements. Increased anxiety, due to pain or other causes, can worsen breathing disorders [8]. Increased pain threshold has also been described in one case [22].

Early postoperative death occurred in one patient. After thorough discussion and review, we speculated that hypovolemia, lactic acidosis and subsequent poor response to hyperkalemia treatment was the main cause of death. In fact, lactic acidosis and elevated ammonia levels have been associated with the disease [11, 23]. Sudden death is a feature of patients with Rett syndrome [10, 24].

Regarding staged procedures, it seems that two-stage scoliosis repair is not associated with more days spent in ICU, but the total number of days in the hospital is higher, as would be expected.

Feeding issues may arise postoperatively. What is more common, though, is the risk of postoperative deterioration of any feeding difficulties [4]. Post-extubation aspiration is a risk which impacts recovery. As in our study, total parenteral nutrition may be needed in cases of prolonged ICU stay.

The limitation of the study is that it is a retrospective review of cases notes and includes no control group. Moreover, the number of patients included is quite small. Unfortunately, the rarity and the characteristics of the disease make the design of randomized controlled trials very difficult. Due to the retrospective nature of the study, some minor complications may have not been included in the patients' notes. However, even such studies can add valuable information to the current literature.

Conclusions

For the patients with Rett syndrome, a multidisciplinary team participated from preoperative evaluation to postoperative management, and all cases were managed postoperatively in HDU/ICU. Nevertheless, more than a few serious complications occurred. In fact, our case series demonstrates a high incidence of complications, mainly postoperative, in patients diagnosed with Rett syndrome who undergo spinal fusion surgery. These mainly include the respiratory and gastrointestinal systems, with the former involving more major complications than the latter. Extreme postoperative vigilance is required and recovery in a high dependency unit is highly recommended. Moreover, a multidisciplinary team approach including surgeons, anesthesiologists, dietitians and physiotherapists is mandatory for not worsening the outcome.

Acknowledgments None.

References

- Neul JL, Kaufmann WE, Glaze DG, Christodoulou J, Clarke AJ, Bahi-Buisson N, Leonard H, Bailey ME, Schanen NC, Zappella M, Renieri A, Huppke P, Percy AK, Rett Search Consortium. Rett syndrome: revised diagnostic criteria and nomenclature. *Ann Neurol*. 2010;68:944–50.
- Gabos PG, Inan M, Thacker M, Borkhu B. Spinal fusion for scoliosis in Rett syndrome with an emphasis on early postoperative complications. *Spine*. 2012;37:E90–4 (Phila Pa 1976).
- Kim JT, Muntyan I, Bashkirov IL, Bloom M, Hartmannsgruber MW. The use of bispectral index monitoring in the anesthetic management of a patient with Rettsyndrome undergoing scoliosis surgery. *J Clin Anesth*. 2006;18:161–2.
- Kerr AM, Webb P, Prescott RJ, Milne Y. Results of surgery for scoliosis in Rett syndrome. *J Child Neurol*. 2003;18:703–8.
- Tofil NM, Buckmaster MA, Winkler MK, Callans BH, Islam MP, Percy AK. Deep sedation with propofol in patients with Rett syndrome. *J Child Neurol*. 2006;21:857–60.
- Ager S, Fyfe S, Christodoulou J, Jacoby P, Schmitt L, Leonard H. Predictors of scoliosis in Rett syndrome. *J Child Neurol*. 2006;21:809–13.
- Freire VE, De la Iglesia LA, Juncal DJL. Rett syndrome: double epidural catheter for the control of postoperative pain after scoliosis surgery. A literature review. *Rev Esp Anesthesiol Reanim*. 2013;60:161–6.
- Ramirez JM, Ward CS, Neul JL. Breathing challenges in Rett Syndrome: lessons learned from humans and animal models. *Respir Physiol Neurobiol*. 2013;189:280–7.
- Downs J, Bergman A, Carter P, Anderson A, Palmer GM, Roye D, van Bosse H, Bebbington A, Larsson EL, Smith BG, Baikie G, Fyfe S, Leonard H. Guidelines for management of scoliosis in Rett syndrome patients based on expert consensus and clinical evidence. *Spine*. 2009;34:E607–17 (Phila Pa 1976).
- Dearlove OR, Walker RW. Anaesthesia for Rett syndrome. *Paediatr Anaesth*. 1996;6:155–8.
- Kumar HA, Chaudhuri S, Budania LS, Joseph TT. Peculiar breathing in Rett syndrome: anesthesiologist's nightmare. *J Anaesthesiol Clin Pharmacol*. 2013;29:278–80.
- Haas RH, Dixon SD, Sartoris DJ, Hennessy MJ. Osteopenia in Rett syndrome. *J Pediatr*. 1997;131:771–4.
- Kawasaki E, Mishima Y, Ito T, Ito A, Takaseya H, Kameyama N, Fukugasako H, Ushijima K. Anesthetic management of a patient with Rett syndrome associated with trismus and apnea attacks. *Masui*. 2012;61:96–9.
- Nho JS, Shin DS, Moon JY, Yi JW, Kang JM, Lee BJ, Kim DO, Chung JY. Anesthetic management of an adult patient with Rett syndrome and limited mouth opening - A case report. *Korean J Anesthesiol*. 2011;61:428–30.
- Julu PO, Kerr AM, Apartopoulos F, Al-Rawas S, Engerström IW, Engerström L, Jamal GA, Hansen S. Characterisation of breathing and associated central autonomic dysfunction in the Rett disorder. *Arch Dis Child*. 2001;85:29–37.
- Konarzewski WH, Misso S. Rett syndrome and delayed recovery from anaesthesia. *Anaesthesia*. 1994;49:357.
- Pierson J, Mayhew JF. Anesthesia in a child with Rett syndrome: a case report and literature review. *AANA J*. 2001;69:395–6.
- Coleman P. Rett syndrome: anaesthesia management. *Paediatr Anaesth*. 2003;13:180.
- Master DL, Thompson GH, Poe-Kochert C, Biro C. Spinal cord monitoring for scoliosis surgery in Rett syndrome: can these patients be accurately monitored? *J Pediatr Orthop*. 2008;28:342–6.
- McLeod LM, French B, Flynn JM, Dormans JP, Keren R. Antifibrinolytic use and blood transfusions in pediatric scoliosis surgeries performed at US children's hospitals. *J Spinal Disord Tech* 2013 Oct 30. [Epub ahead of print].
- Verma K, Errico TJ, Vaz KM, Lonner BS. A prospective, randomized, double-blinded single-site control study comparing blood loss prevention of tranexamic acid (TXA) to epsilon aminocaproic acid (EACA) for corrective spinal surgery. *BMC Surg*. 2010;10:13.
- Devarakonda KM, Lowthian D, Raghavendra T. A case of Rett syndrome with reduced pain sensitivity. *Paediatr Anaesth*. 2009;19:625–7.
- Philippart M. Clinical recognition of Rett syndrome. *Am J Med Genet Suppl*. 1986;1:111–8.
- Khalil SN, Hanna E, Farag A, Armendartz G. Rett syndrome: anaesthesia management. *Paediatr Anaesth*. 2002;12:375.