

Low-dose vasopressin infusion in patients with severe vasodilatory hypotension after prolonged hemorrhage during general anesthesia

ISAO TSUNEYOSHI, MASANORI ONOMOTO, ARATA YONETANI, and YUICHI KANMURA

Department of Anesthesiology and Critical Care Medicine, Kagoshima University School of Medicine, 8-35-1 Sakuragaoka, Kagoshima 890-8520, Japan

Abstract We report the successful use of a low-dose vasopressin (VP) infusion to recover a hypotensive crisis in patients who suffered persistent hypotension after prolonged hemorrhage during general anesthesia. VP was infused in two posthemorrhagic vasodilatory shock patients when they remained persistently hypotensive despite adequate fluid resuscitation and infusions of pharmacological doses of catecholamines. On administration of VP at $0.04 \text{ U}\cdot\text{min}^{-1}$, systemic vascular resistance, systolic arterial pressure, and urine output were immediately increased (as compared with the values obtained just before VP), and infusion of catecholamine could be decreased. No adverse cardiac effects were observed during VP infusions in these patients. During vasodilatory shock after prolonged and severe hemorrhage, VP seems to be effective in reversing hypotension and decreasing the need for exogenous catecholamines while preserving cardiac function and critical organ blood flow.

Key words Vasopressin · Hemorrhage · Vasodilatory hypotension · General anesthesia

Introduction

In recent years, exogenous arginine vasopressin (VP) has been used clinically to maintain blood pressure during hypotensive crises [1–5]. However, data regarding the efficacy and safety of VP in hemorrhagic conditions are limited [6]. Here, we report two cases of severe hypotension due to prolonged hemorrhagic shock who recovered when treated with a low-dose VP infusion.

Case reports

Case 1

A 58-year-old man weighing 58 kg, who had no past history of serious illness, operation, or hospitalization, experienced an acute episode of back pain and was rushed to the emergency department of our hospital. A CT scan of the chest, at the level of the aortic arch, revealed an acute type-A aortic dissection and he was scheduled to undergo aortic-arch repair. The patient was monitored for ST segment and arrhythmia using continuous electrocardiography, and his blood pressure was measured continuously using an indwelling arterial catheter. Anesthesia was induced by injecting 4 mg midazolam, 250 μg fentanyl, and 10 mg vecuronium intravenously, and then maintained with 40%–100% oxygen and a continuous infusion of propofol ($8 \text{ mg}\cdot\text{kg}^{-1}\cdot\text{h}^{-1}$). Occasionally, intravenous fentanyl (total, 1000 μg) was administered. Hemodynamic parameters, including cardiac output by thermodilution, were recorded using a pulmonary artery catheter. Profound hypothermia (25°C) was initiated by cardiopulmonary bypass (CPB), via catheters inserted in a femoral vein and artery, and individual cannulation and perfusion of cerebral vessels was used for the purpose of aortic-arch surgery. After separation from CPB, however, excessive postbypass bleeding at the graft–aorta junctions continued, with severe hypotension [systolic arterial pressure (SAP), 60–80 mmHg], for more than 5 h (Fig. 1, upper). Despite aggressive intravenous fluid and blood products resuscitation and pharmacological manipulation ($0.4 \mu\text{g}\cdot\text{kg}^{-1}\cdot\text{min}^{-1}$ norepinephrine, $2 \mu\text{g}\cdot\text{kg}^{-1}\cdot\text{min}^{-1}$ dopamine, and $0.2 \mu\text{g}\cdot\text{kg}^{-1}\cdot\text{min}^{-1}$ epinephrine), we noted that 8 h after CPB (with his bleeding already controlled) his SAP began to decline gradually to below 50 mmHg. This was accompanied by a low systemic vascular resistance index (SVRI, $690 \text{ dyne}\cdot\text{s}\cdot\text{m}^{-2}\cdot\text{cm}^{-5}$), a high cardiac index (CI, $4.41\cdot\text{min}^{-1}\cdot\text{m}^{-2}$), and a low central venous

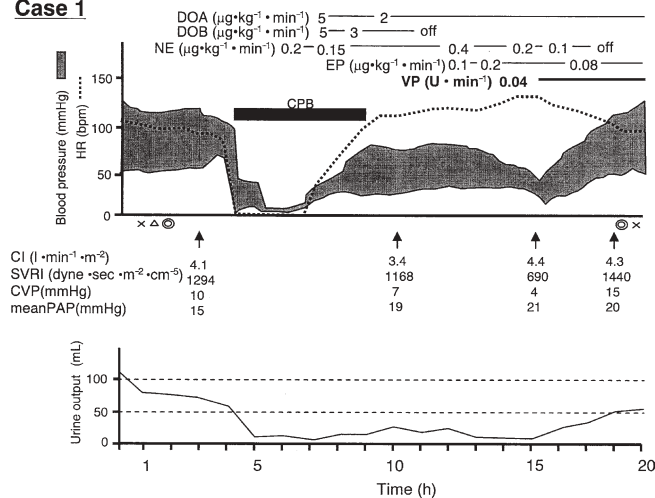
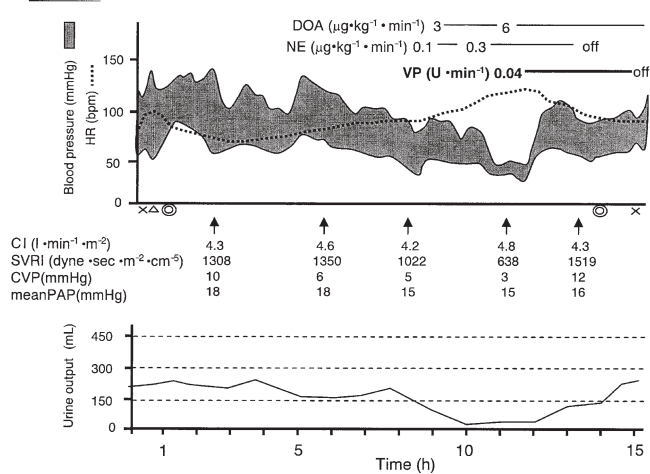
Case 1**Case 2**

Fig. 1. Anesthesia records: cases 1 and 2. DOA, dopamine; DOB, dobutamine; NE, norepinephrine; EP, epinephrine; VP, vasopressin; CPB, cardiopulmonary bypass; CI, cardiac index; SVRI, systemic vascular resistance index; CVP, central venous pressure; PAP, pulmonary arterial pressure

pressure (CVP, 4 mmHg). His plasma VP level increased $537\text{pg}\cdot\text{ml}^{-1}$ in the early stage of hemorrhagic shock (2h after CPB), and then decreased to $182\text{pg}\cdot\text{ml}^{-1}$ at 5h after CPB, despite the presence of the massive hypotension. After intravenous VP was started at $0.04\text{U}\cdot\text{min}^{-1}$, however, his blood pressure improved dramatically; within 1h, his SAP increased to 120 mmHg (so catecholamine pressor could be decreased), and urine output gradually increased. At the same time, the plasma concentration of VP elevated again at $293\text{pg}\cdot\text{ml}^{-1}$. Total anesthetic time was 17h 45 min, total bleeding volume was 7150 ml, total infusion and blood transfusion volume was 12350 ml, and total urine output was 1070 ml. After arrival in the intensive care unit (ICU), the patient's hemodynamic data were within normal limits, and VP was discontinued unevent-

fully after 35h of administration. Five days later, the patient was transferred to a general ward with stable vital signs.

Case 2

A 60-year-old man weighing 53 kg was referred to our hospital for an operation for hepatocellular carcinoma. A CT scan of the liver showed a solitary space-occupying lesion (size, $12 \times 8\text{cm}$) in the right posterior segment, and an extended right hepatectomy was scheduled. Anesthesia was induced by injecting 200 mg thiopental and 6 mg vecuronium intravenously, and then maintained with 40%–100% oxygen and 1%–3% sevoflurane. Occasionally, intravenous fentanyl (total, 300 μg) was administered. Monitoring and measured parameters were the same as case 1.

During the hepatectomy, bleeding was controlled using the Pringle maneuver, but massive oozing continued from the incised wound in the liver (Fig. 1, lower). The bleeding continued for more than 4h with sustained hypotension (SAP, 70–90 mmHg), despite cardiovascular support being given by i.v. fluid resuscitation and dopamine ($6\mu\text{g}\cdot\text{kg}^{-1}\cdot\text{min}^{-1}$) plus norepinephrine ($0.3\mu\text{g}\cdot\text{kg}^{-1}\cdot\text{min}^{-1}$) infusion. Ten hours later, when the bleeding already reached a level of 11450 ml, SAP decreased further, to below 60 mmHg, and hemodynamic values indicated vasodilatory shock, as demonstrated by the high CI ($4.8\text{l}\cdot\text{min}^{-1}\cdot\text{m}^{-2}$), low SVRI ($638\text{dyne}\cdot\text{s}\cdot\text{m}^{-2}\cdot\text{cm}^{-5}$), and low CVP (3 mmHg). Intravenous administration of VP ($0.04\text{U}\cdot\text{min}^{-1}$) quickly restored SAP to 120 mmHg and allowed us to cease norepinephrine infusion, with SAP maintained at $>100\text{mmHg}$ (SVRI $>1500\text{dyne}\cdot\text{s}\cdot\text{m}^{-2}\cdot\text{cm}^{-5}$). During VP infusion, CI remained almost unchanged ($4.3\text{l}\cdot\text{min}^{-1}\cdot\text{m}^{-2}$), but urine output increased from 25 to $100\text{ml}\cdot\text{h}^{-1}$. After the 3-h VP treatment, the patient's hemodynamics had improved sufficiently to allow discontinuation of VP. His plasma VP level increased $177\text{pg}\cdot\text{ml}^{-1}$ in the early stage of hemorrhagic shock (8h after the start of the operation); after 11h, however, it decreased to $115\text{pg}\cdot\text{ml}^{-1}$. However, 1h after intravenous VP was started at $0.04\text{U}\cdot\text{min}^{-1}$, it elevated again to $323\text{pg}\cdot\text{ml}^{-1}$. Total anesthetic time was 16h 50 min, total bleeding volume was 17065 ml, total infusion and blood transfusion volume was 32730 ml, and total urine output was 4555 ml. In the ICU, the patient was weaned from the ventilator the next morning; he left the ICU on the third day, with no undesirable events.

Discussion

The two patients described here had severe bleeding with prolonged and severe hypotension; several hours

after its onset it could not be reversed despite volume replacement and massive doses of catecholamine pressors. However, the initiation of low-dose VP infusion was accompanied by a significant increase in blood pressure and SVRI, whereas cardiac output remained almost unchanged throughout the VP treatment period. Moreover, in these patients urine output increased with VP administration, despite its well-known antidiuretic action. These results indicate that pharmacological manipulation of VP might prove clinically useful as a way of mitigating abnormal vascular reactions after hemorrhagic shock.

Severe hemorrhage is well known to be a potent stimulus for VP release [7]. During hemorrhagic shock, plasma VP rises to very high levels immediately after bleeding, but rapidly declines if the condition is prolonged [7]. Indeed, in each of our hemorrhagic shock patients, the initial increase in plasma VP levels was followed by a precipitous decline, suggesting that VP responses are best viewed as a potentially important “rapid response” system that cannot remain active for prolonged periods [6]. On the other hand, when VP was applied intravenously, the plasma concentration became elevated again, with a subsequent increase in blood pressure. These results suggest that the underlying VP-response mechanism may become exhausted when hemorrhagic shock is prolonged.

To date, only limited information is available concerning VP treatment in hemorrhagic shock. In the only other clinical investigation published on this subject, Morales et al. [6] reported that, in two patients with hemorrhagic shock, VP infusions at $1\text{--}4\ \mu\text{U}\cdot\text{kg}^{-1}\cdot\text{min}^{-1}$ increased both blood pressure and cardiac output while reducing catecholamine requirements. During VP infusions, plasma concentrations increased rapidly up to $\approx 300\ \text{pg}\cdot\text{ml}^{-1}$, in comparison to normal VP plasma levels ($<4\ \text{pg}\cdot\text{ml}^{-1}$) [2]. Our observations appear to support their conclusion because the concentrations of VP were similar in both studies.

As demonstrated by other investigators, however, VP produces little effect on blood pressure in normotensive individuals with intact baroreflexes. A VP-induced increase in cardiac preload (CVP) appears to attenuate the activation of the sympathetic nervous system due to a sensitization of cardiac baroreceptors. This cardiac reflex was not observed, however, in the present study. There is some indirect evidence in humans to support our observation that VP increases arterial pressure dramatically when peripheral sympathetic nerve activity is impaired [7]. Möhring et al. have suggested that a loss of the blood pressure buffering cardiovascular reflex systems *per se* accounts, at most, for a tenfold increase in sensitivity to this pressor substance in humans [8].

The cause of posthemorrhagic vasodilatory shock is unclear but possibly involves a variety of noninfectious

stimuli that lead to excessive vasodilation, as in septic shock [9]. As already mentioned, VP depletion, after massive release during hemorrhage, also may contribute to this syndrome. VP may restore, either by direct and indirect mechanisms, the attenuated vasomotor reactivity in resistant arteries, which play a major role in maintaining peripheral vascular tone [7]. Interestingly, in this study as well as in a previous human study from this laboratory [2], continuous infusion of VP had little effect on pulmonary arterial pressure, suggesting that pulmonary vascular tone may be unaffected by elevations in plasma VP. This may be partially related to the ability of VP to cause release of the endothelium-derived vasodilator, nitric oxide (NO), which may specifically counteract the increased pulmonary vascular tone in patients with such pathophysiological conditions [9].

VP is also well known to be a regulator of water balance, largely via the antidiuretic action resulting from activation of V_2 receptors on renal collecting duct cells [7]. Studies have indicated that concentrated urine in the nephron segment is produced in response to VP by the transepithelial recovery of water from the lumen of the kidney collecting tubule through highly water-permeable proteins, called aquaporins [10]. Actually, VP has been reported to effectively manipulate the massive water diuresis that occurred in postoperative patients [11]. In our hemorrhagic shock patients, however, VP acted as a natriuretic hormone. Although it is difficult to draw any conclusions regarding the mechanisms underlying the improved urine output seen during VP infusion, the positive effect on blood pressure would, by itself, be expected to contribute to an increase in urine output. Another possible explanation for the lack of antidiuretic function of VP in this situation may be associated with impaired tubular functions, intrarenal and peritubular hemodynamics, or a redistribution of renal blood flow, leading to an alternating functional interaction between VP and aquaporin. However, further studies are needed to clarify how this peptide can initiate such dual renal reactions—which one occurs (or predominates) being dependent, apparently, on the presence or absence of a hypotensive crisis.

It has been shown that a dose of $0.01\text{--}0.1\ \text{U}\cdot\text{min}^{-1}$ VP is most effective in patients with vasodilatory shock, without causing any adverse effects [9]. Nevertheless, to date, there have only been a small number of randomized controlled trials of VP in humans. Furthermore, whether these data will translate into improved long-term outcome is not known [12]. The most possible adverse effect of VP administration may be coronary vasoconstriction, although this is still controversial [12]. There is no doubt that effective treatment of vasodilatory shock is possible if patients possess normal cardiac performance and are maintained by adequate intra-

vascular volume replacement. Patients undergoing VP treatment must be carefully followed up and monitored for potential adverse effects, such as cardiac dysfunction or myocardial ischemia.

In conclusion, during vasodilatory shock, after prolonged and severe hemorrhage, VP seems to be effective in reversing hypotension and decreasing the need for exogenous catecholamines, while preserving cardiac function and critical organ blood flow, especially in the kidney. In addition, the dose of VP used has little pressor effect on pulmonary arteries but exerts a potent increase on cardiac filling pressures.

References

1. Landry DW, Levin HR, Gallant EM, Ashton RC, Seo S, D'Alessandro D, Oz MC, Oliver JA (1997) Vasopressin deficiency contributes to the vasodilation of septic shock. *Circulation* 95:1122–1125
2. Tsuneyoshi I, Yamada H, Kakihana Y, Nakamura M, Nakano Y, Boyle WA (2001) Hemodynamic and metabolic effects of low-dose vasopressin infusion in vasodilatory septic shock. *Crit Care Med* 29:487–493
3. Overand PT, Teply JF (1998) Vasopressin for the treatment of refractory hypotension after cardiopulmonary bypass. *Anesth Analg* 86:1207–1209
4. Voelckel WG, Lurie KG, Lindner KH, Zielinski T, McKnite S, Krismer AC, Wenzel V (2000) Vasopressin improves survival after cardiac arrest in hypovolemic shock. *Anesth Analg* 91:627–634
5. Patel BM, Chittock DR, Russell JA, Walley KR (2002) Beneficial effects of short-term vasopressin infusion during severe septic shock. *Anesthesiology* 96:576–582
6. Morales D, Madigan J, Cullinane S, Chen J, Heath M, Oz M, Oliver JA, Landry DW (1999) Reversal by vasopressin of intractable hypotension in the late phase of hemorrhagic shock. *Circulation* 100:226–229
7. Tsuneyoshi I, Boyle WA (2003) Vasopressin: new uses for an old drug. *Contemp Crit Care* 1:1–12
8. Möhring J, Glanzer K, Maciel JA Jr, Dusing R, Kramer HJ, Arbogast R, Koch-Weser J (1980) Greatly enhanced pressor response to antidiuretic hormone in patients with impaired cardiovascular reflexes due to idiopathic orthostatic hypotension. *J Cardiovasc Pharmacol* 2:367–376
9. Landry DW, Oliver JA (2001) The pathogenesis of vasodilatory shock. *N Engl J Med* 345:588–595
10. Fushimi K, Uchida S, Hara Y, Hirata Y, Marumo F, Sasaki S (1993) Cloning and expression of apical membrane water channel of rat kidney collecting tubule. *Nature (Lond)* 361:549–552
11. Wise-Faberowski L, Soriano SG, Ferrari L, McManus ML, Wolfsdorf JJ, Majzoub J, Scott RM, Truog R, Rockoff MA (2004) Perioperative management of diabetes insipidus in children. *J Neurosurg Anesthesiol* 16:220–225
12. Krismer AC, Wenzel V, Stadlbauer KH, Mayr VD, Lienhart HG, Arntz HR, Lindner KH (2004) Vasopressin during cardiopulmonary resuscitation: a progress report. *Crit Care Med* 32:S432–S435
13. Mayr VD, Wenzel V, Muller T, Antretter H, Rheinberger K, Lindner KH, Strohmenger HU (2004) Effects of vasopressin on left anterior descending coronary artery blood flow during extremely low cardiac output. *Resuscitation* 62:229–235