



The value of cryoablation in orbital surgery

Johannes Herta · Christian Matula · Lisa Wadiura · Matthias Millesi 

Received: 15 January 2024 / Accepted: 20 February 2024
© The Author(s) 2024

Summary Aim of this article is to give an overview of the technical background and the advantages of modern devices for different applications of cryoablation in cranio-orbital neurosurgery.

The treatment of orbital lesions is complicated by the complex and potentially inapparent anatomy due to retro-orbital fat. With the help of cryoprobes different well-defined lesions such as cavernous venous malformations can be safely and effectively removed thanks to the cryoadhesive effect. Their use has been described in several different approaches including traditional lateral or transcranial orbitotomy but also anterior transconjunctival as well as transnasal endoscopic approaches. Recently, single-use devices were introduced that allow the use of cryosurgery also without the need for large investment or service costs.

Keywords Cryosurgery · Orbital tumors · Cryoadhesion · Orbital schwannoma · Cavernous venous malformation

Introduction

In orbital tumors treatment is typically indicated in growing lesions or if they become symptomatic [1, 2]. Such typical symptoms include orbital protrusion, double vision, and visual decline [1, 2]. In most of these cases, complete surgical removal is the treat-

ment of choice. If possible, entire removal of the orbital mass or tumor should be performed without penetration of the lesion [1, 2]. A variety of different surgical corridors are nowadays available including traditional open microsurgical transcranial and transorbital but also endoscopic transcranial, transorbital, and transnasal approaches depending on the different locations of tumors within the orbit [1–8].

Independent of the chosen surgical approach, meticulous preparation and dissection of the orbital mass or tumor without harming surrounding healthy structures such as the globe, ocular muscles or nerves needs to be performed. Eventually, after the lesion is freed from all adhesions, one piece removal should be performed. Different techniques and instruments such as grasping forceps or placement of a suture through the mass can be used; however, the frailty of some of these masses or their capsule puts them at risk of rupture and opening during this maneuver which might complicate lesion removal due to the narrow and complex retro-orbital conditions.

Another option to gently grasp a lesion without perforating it may be to use a cryoprobe [1, 7, 9]. In general, cryosurgery is used in various disciplines for different diseases. These include dermatological surgery, oral and maxillofacial surgery but also general and gynecological surgical applications for tumors and other conditions [10–14]. In most of these treatments the aim is maximum cellular destruction by rapid freezing [15].

Already in 1975 the use of the adhesive effect of a cryoprobe for grasping and gentle removal of orbital lesions was described by Putterman and Goldberg in a small series of 4 patients [9]. Following this, various probes have been developed and used to facilitate orbital tumor removal. Aim of this report is to give an overview of the technical background and different uses together with a discussion of the most appropri-

Supplementary Information The online version of this article (<https://doi.org/10.1007/s00508-024-02340-6>) contains supplementary material, which is available to authorized users.

J. Herta, MD PhD · C. Matula, MD · L. Wadiura, MD PhD · M. Millesi, MD PhD (✉)
Department of Neurosurgery, Medical University of Vienna, Währinger Gürtel 18–20, 1090 Vienna, Austria
matthias.millesi@meduniwien.ac.at

ate conditions to apply such a cryoprobe in orbital surgery.

Technical background of cryosurgery

The method of destroying tissue by freezing is called cryoablation. Cryoablation was first introduced by the English physician James Arnott (1797–1883) who used a combination of salt and crushed ice to treat breast, uterine and skin cancer [10, 12]. Since then, it has found many suitable areas of application as it is simple, cheap and safe to use in medicine. Resulting from the testing of various different cooling agents, liquid nitrogen has emerged as the most popular cryogen for medical use with achievable low temperatures of -197°C but other possible agents used today include noble gases like argon but also oxygen, nitrous oxide or carbon dioxide [14, 16, 17].

In general, the lesion must be targeted with the cryo-probe. Once in physical contact, the probe is rapidly cooled down and removes heat from the lesion by conduction. The cryoprobe contains the pressurized gas which flows out through a narrow opening. During this process the gas rapidly expands at room temperature and exhibits the Joule-Thompson cooling effect [16]. This effect leads to rapid cooling of the metallic probe itself which then transfers the freezing effect to the surrounding tissue [16].

The extent of cellular injury may be influenced by the cooling rate, the target temperature, cooling duration and the thawing rate [17]; however, in nearly all tissues cell death is induced by cooling rapidly below -40°C [15]. Cell death may occur due to direct injury to cells and indirect mechanisms that induce changes to the cellular microenvironment. Such direct damage occurs through ice crystal formation in the extracellular space during the freezing process [16, 17]. Due to the increased osmolality, more intracellular water is withdrawn, which leads to dehydration of the cells. If cooling occurs rapidly, intracellular ice formation leads to physical cellular damage and cell death [16]. Contrary to the freezing process thawing usually occurs in the extracellular space first and leads to water influx into the cells. This eventually can lead to swelling and bursting which also creates direct injury to the cells [16, 17]. In contrast to the freezing process, more damage occurs if thawing happens slowly [17]. Following this, indirect cell damage occurs via apoptosis processes and inflammatory changes in the surrounding damaged tissue and its microenvironment [16].

In addition to these ablative effects, cryoprobes also have an adhesive effect that became of interest as a tool in modern surgery especially for the use during minimally invasive procedures.

Cryoablation devices

There are currently several providers of cryoablation devices on the market. The main differences between the devices are: (1) the gas used, (2) the controllability of the gas flow, (3) single or multi-use probes and (4) difference in probe shape.

Regarding different probes, their design varies according to their field of use. In this sense, special designs such as slings are used to cover larger areas or balloons in the setting of intravascular applications [18, 19]. Otherwise, most of the cryoprobes have narrow tips for cryoablation.

In orbital surgery, in multi-use devices the probe can be changed but most of them are designed with a long thin tip [2, 4]. Furthermore, most of these tips are round although attempts were made to introduce flat oblique tips to increase the surface that comes in contact with the lesion for a better adhesion effect [2, 4, 20, 21]. Single-use devices are often wider at the grip as they need to give space for the container with the cooling agent and their probes are fixed [20]. These different aspects need to be considered, especially when different surgical approaches are used [2, 4, 7].

At our institution we currently use two different cryoablation devices (Fig. 1). CryoTreq (BVI Medical, Waltham, MA, USA) is a single-use wireless cryoprobe that has a liquid nitrous oxide container integrated into the handpiece [20]. The clear advantage of this system is that it is an easy to use wireless device with no service or investment costs that can be used up to 1h. The drawback of a single-use device like this is the lack of adjustment options. Additionally, the rear part with the small container is wider and the thin tip shorter and curved in comparison to other devices. In most situations this is sufficient for most of the lesions but to reach to the orbital apex, the superficial opening needs to be large enough. Other single-use devices also exist but are mostly designed for superficial or skin lesions.

On the other hand, the Erbecryo (Erbe Elektromedizin GmbH, Tübingen, Germany) device at our institution needs more space for the equipment cart and the associated carbon dioxide bottle but it allows more flexibility as it can be used with different probe shapes as outlined above. Similar to this, the Optikon Cryoline device (Optikon 2000 S.p.A., Rome, Italy) offered a variety of tips and has been described also in the setting of an endonasal approach to the orbit in the publication by Castelnuovo et al. [4].

Newer cryoablation devices are currently in development. In these devices, rarer noble gases such as argon are used to cool the probe tip by circulation of the cryogen. The aim here is to reduce the costs and size of the devices due to the current loss of gases due to the Joule-Thompson effect [16].

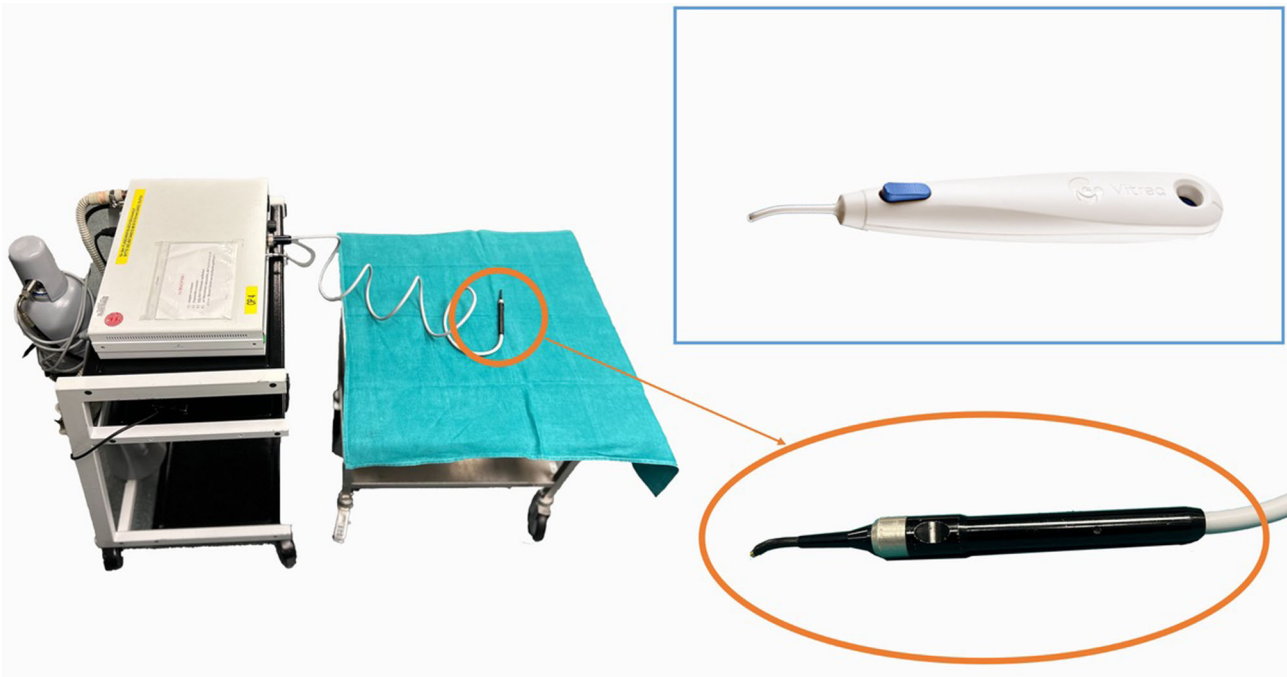


Fig. 1 Two different cryoablation devices are shown. The CryoTreq (blue square) is a single-use wireless cryoprobe that integrates its gas container in its handpiece. The Erbecryo (or-

ange circle) on the other hand is a multi-use device that consists of a gas tank, the device itself on a cart and a wired cryoprobe. Different cryoprobes can be used

Discussion

The abovementioned ablative processes of cryotherapy have been used in various surgical disciplines. These included dermatological, oral and maxillofacial, general and gynecological surgery [10–12]. Especially in recent years, the field of cryosurgery received a new wave of interest in the treatment of prostate cancer and breast cancer [13, 14].

Cryosurgery in surgical procedures of the orbit

Ablative cryosurgery was also used extensively in ophthalmological surgery starting as early as the 1930s with the treatment of retinal tears [10]. To date, cryoablation in ophthalmological surgery remains in use for a variety of different conditions such as glaucoma, cataract, retinopathy, disorders of the eyelid or neoplastic lesion [22–26].

Additionally, the adhesive effect of a cryoprobe came into the focus of interest after the first description of its use for removal of orbital masses [1, 9]. As a result, it became clear that certain advantages exist for both the ablative effect as well as the adhesive effect of cryosurgery during surgery of orbital pathologies. For demonstration of the cryoadhesive effect for removal of a cavernous venous malformation in an illustrative case see video 1 (supplementary material).

Advantages and disadvantages of cryosurgery

An advantage of cryoablation is the direct visual control of the ablation progress. During cryoablation the lesion undergoes a phase transition forming an ice ball that is attached to the tip of the device. This allows the surgeon to dissect the tumor out of the surgical site very safely and clearly using gentle traction. This means that lesions that are otherwise difficult to grasp can be removed en bloc in a narrow and complex anatomical space due to the intraorbital fat tissue. Another theoretically potential advantage of cooling may be the anesthetic effect that is provided by cryoablation in comparison to resection by thermocoagulation [27].

Furthermore, the developing adhesion through the ice ball formation allows gentle manipulation of an orbital mass and removal with reduced risk of opening the lesion or tearing off a capsule [1, 2]. Moreover, the freezing effect of the tumor itself but also close vessels can lead to reduced bleeding during the removal [1].

Orbital pathologies suitable for removal with a cryoprobe

After initial case series, the application of the cryoadhesive effect for removal of orbital tumors gained remarkable interest with orbital surgeons [1, 7, 28]. Several studies reported the use of cryoprobes for the removal of different orbital tumors with variable success. The most suitable lesions represent well-circumscribed encapsulated masses with no relevant adhe-

sions or tendency to infiltrate surrounding structures. Therefore, orbital cavernous venous malformations represent the most suitable lesions as they consist of dilated venous channels that are typically surrounded by a thin fragile capsule (video 1, supplementary material) [29, 30]. They are also the most common benign intraorbital mass, typically requiring resection only if they show growth on serial imaging or become symptomatic or lead to disfiguring proptosis [2, 29, 30].

Besides cavernous venous malformations schwannomas, hemangiopericytomas, dermoid or epidermoid cysts and meningiomas within the orbit are also well-circumscribed benign lesions in which the use of a cryoprobe can facilitate complete removal [1, 7, 9]. In addition, some cases of removal of malignant tumors with the use of a cryoprobe were also reported and include rhabdomyosarcoma or carcinomas [1, 7]. In these situations, removal with a cryoprobe can also facilitate en bloc resection without rupture of the lesions and spillage of malignant tumor cells [1, 7].

In pathologies that infiltrate surrounding tissue like the eyeball, muscles but also the surrounding bone, the application of cryosurgery is of limited value [1, 7]. This also applies to diffuse pathologies, although some authors advocate using cryosurgery also for tissue acquisition during biopsy procedures [1, 2, 7].

Possible approaches for cryoextraction of orbital masses

Traditionally, a lateral orbitotomy (Kroenlein approach) represented the workhorse for the extraction of orbital masses [5, 7, 9, 28]. This applied to both traditional procedures with grasping forceps or threads to resect orbital lesions as well as surgical procedures with the application of a cryoprobe [1, 3, 5, 7, 9]. Over the years, various transcranial approaches but also anterior transconjunctival approaches have been applied and advocated to remove orbital masses with cryoextraction [1–3, 7, 28, 31].

In recent years, the application of a cryoprobe for the removal of intraorbital masses was also used in endoscopic transnasal approaches leading to a small number of published cases reports [4, 6, 8, 32].

Conclusion

Although cryosurgery has been in medical use for a very long time, it has not yet had a major role in general neurosurgery; However, cryosurgery shows its strength especially when it comes to interventions in the narrow and complex orbital anatomy when removing well-circumscribed lesions. The cryoadhesive effect makes the removal of these lesions gentle and safe. As there are now single-use cryoprobes that do not require a large gas tank, cryosurgical devices should be considered part of every orbital surgeon's standard armamentarium.

Author Contribution J. Herta: study design, drafting the manuscript, reviewing the final manuscript; C. Matula: study design, reviewing the final manuscript; L. Wadiura: study design, reviewing the final manuscript; M. Millesi: study design, drafting the manuscript, reviewing the final manuscript. All authors approved the final version of the manuscript.

Funding Open access funding provided by Medical University of Vienna.

Declarations

Conflict of interest J. Herta, C. Matula, L. Wadiura and M. Millesi declare that they have no competing interests.

Ethical standards Waived due to the anonymous description of a surgical technique.

Open Access This article is licensed under a Creative Commons Attribution 4.0 International License, which permits use, sharing, adaptation, distribution and reproduction in any medium or format, as long as you give appropriate credit to the original author(s) and the source, provide a link to the Creative Commons licence, and indicate if changes were made. The images or other third party material in this article are included in the article's Creative Commons licence, unless indicated otherwise in a credit line to the material. If material is not included in the article's Creative Commons licence and your intended use is not permitted by statutory regulation or exceeds the permitted use, you will need to obtain permission directly from the copyright holder. To view a copy of this licence, visit <http://creativecommons.org/licenses/by/4.0/>.

References

- Kiratli H, Bilgiç S. Cryoextraction in the management of orbital tumors. An old technique revisited. *Orbit*. 1998;17:189–94.
- Millesi M, Pichler L, Denk C, Lukas J, Matula C, Wadiura L. Clinical Outcome and Technical Nuances After Resection of Orbital Cavernous Venous Malformations—A Single-Center Experience. *World Neurosurg*. 2021;153:e244–9.
- Kannan S, Hasegawa M, Yamada Y, Kawase T, Kato Y. Tumors of the orbit: Case report and review of surgical corridors and current options. *Asian J Neurosurg*. 2019;14:678–85.
- Castelnuovo P, Arosio AD, Volpi L, De Maria F, Ravasio A, Donati S, et al. Endoscopic Transnasal Cryo-Assisted Removal of Orbital Cavernous Hemangiomas: Case Report and Technical Hints. *World Neurosurg*. 2019;126:66–71.
- Dalfino G, Sileo G, Ronchi A, Lazzari E, Castelnuovo P, Turri Zanoni M. Lateral Orbitotomy Cryo-Assisted Removal of Orbital Cavernous Hemangiomas: Case Report and Technical Hints. *World Neurosurg*. 2023;178:69.
- Leocata A, Veiceschi P, Ferlendis L, Agresta G, Castelnuovo P, Locatelli D. Endoscopic Endonasal Excision of a Cavernous Hemangioma of the Orbital Apex with Cryoprobe Assistance: Two-Dimensional Surgical Video. *World Neurosurg*. 2023;176:142.
- Rosen N, Priel A, Simon GJB, Rosner M. Cryo-assisted anterior approach for surgery of retroocular orbital tumours avoids the need for lateral or transcranial orbitotomy in most cases. *Acta Ophthalmol*. 2010;88:675–80.
- Rimmer RA, Graf AE, Fastenberg JH, Bilyk J, Nyquist GG, Rosen MR, et al. Management of Orbital Masses: Outcomes of Endoscopic and Combined Approaches With No Orbital Reconstruction. *Allergy Rhinol (providence)*. 2020;11:215265671989992.

9. Putterman A, Goldberg MF. Retinal Cryoprobe in Orbital Tumor Management. *Am J Ophthalmol.* 1975;80:88–92.
10. Cooper SM, Dawber RPR. The History of Cryosurgery. *J R Soc Med.* 2001;94:196–201.
11. Clebak KT, Mendez-Miller M, Croad J. Cutaneous Cryosurgery for Common Skin. *Conditions.* 2020;101.
12. Kujan O, Azzeghaiby SN, Tarakji B, Abuderman A, Sakka S. Cryosurgery of the oral and peri-oral region: a literature review of the mechanism, tissue response, and clinical applications. *J Invest Clin Dent.* 2013;4:71–7.
13. Gao L, Yang L, Qian S, Tang Z, Qin F, Wei Q, et al. Cryosurgery would be An Effective Option for Clinically Localized Prostate Cancer: A Meta-analysis and Systematic Review. *Sci Rep.* 2016;6:27490.
14. Mokbel K, Kodresko A, Ghazal H, Mokbel R, Trembley J, Jouhara H. The Evolving Role of Cryosurgery in Breast Cancer Management: A Comprehensive Review. *Cancers.* 2023;15:4272.
15. Baust J, Gage AA, Ma H, Zhang C-M. Minimally Invasive Cryosurgery—Technological Advances. *Cryobiology.* 1997;34:373–84.
16. Erinjeri JP. Cryoablation CTWI. Mechanism of Action and Devices. *J Vasc Interv Radiol.* 2010;21:S187–91.
17. Baust JG, Gage AA. The molecular basis of cryosurgery. *BJU Int.* 2005;95:1187–91.
18. Desai V, Sampieri G, Namavarian A, Lee JM. Cryoablation for the treatment of chronic rhinitis: A systematic review. *Journal of Otolaryngology—Head & Neck Surgery.* 2023;52:s40463-023-00645–6.
19. Ohkura T, Yamasaki T, Kakita K, Hattori T, Nishimura T, Iwakoshi H, et al. Comparison of maximum-sized visually guided laser balloon and cryoballoon ablation. *Heart Vessels.* 2023;38:691–8.
20. Rizzo S, Savastano MC, Gambini G, De Vico U, Caporossi T, Savastano A. New Disposable Cryotherapy Device: A Small, Smart, and Useful Tool. *Ophthalmology Retina.* 2021;5:598–600.
21. Finger PT. “Fingertip” cryoprobe assisted orbital tumour extraction. *Br J Ophthalmol.* 2005;89:777.
22. Andersen C, Phelps D. Peripheral retinal ablation for threshold retinopathy of prematurity in preterm infants. *Cochrane Neonatal Group, editor. Cochrane Database of Systematic Reviews [Internet].* 1999 [cited 2023 Nov 18];2010. Available from: <https://doi.org/10.1002/14651858.CD001693>
23. Bartley GB, Bullock JD, Olsen TG, Lutz PD. An Experimental Study to Compare Methods of Eyelash Ablation. *Ophthalmology.* 1987;94:1286–9.
24. Hajjaj A, Van Overdam KA, Gishti O, Ramdas WD, Kiliç E. Efficacy and safety of current treatment options for peripheral retinal haemangioblastomas: a systematic review. *Acta Ophthalmologica [Internet].* 2022 [cited 2023 Nov 18];100. Available from: <https://doi.org/10.1111/aos.14865>
25. Yi X, Meng F, Bi Y, He L, Qian J, Xue K. Intraocular medulloepithelioma clinical features and management of 11 cases. *Br J Ophthalmol.* 2023;bjo-2022-322449.
26. Bellows JG. *Cryotherapy of Ocular Diseases.* Philadelphia: J. B. Lippincott; 1966.
27. Khezri MB, Akrami A, Majdi M, Gahandideh B, Mohammadi N. Effect of cryotherapy on pain scores and satisfaction levels of patients in cataract surgery under topical anesthesia: a prospective randomized double-blind trial. *BMC Res Notes.* 2022;15:234.
28. Lazar M, Rosen N, Geyer O, Godel V. A Transconjunctival Cryosurgical Approach For Intraorbital Tumours. *Aust N Z J Ophthalmol.* 1985;13:417–20.
29. Calandriello L, Grimaldi G, Petrone G, Rigante M, Petroni S, Riso M, et al. Cavernous venous malformation (cavernous hemangioma) of the orbit: Current concepts and a review of the literature. *Surv Ophthalmol.* 2017;62:393–403.
30. Rootman DB, Heran MKS, Rootman J, White VA, Luem-samran P, Yucl YH. Cavernous venous malformations of the orbit (so-called cavernous haemangioma): a comprehensive evaluation of their clinical, imaging and histologic nature. *Br J Ophthalmol.* 2014;98:880–8.
31. Campbell PG, Yadla S, Rosen M, Bilyk JR, Murchison AP, Evans JJ. Endoscopic Transnasal Cryo-Assisted Removal of an Orbital Cavernous Hemangioma: A Technical Note. *Minim Invasive Neurosurg.* 2011;54:41–3.
32. Marcellino CR, Peris-Celda M, Link MJ, Stokken JK. Endoscopic Endonasal Resection of Orbital Apex Cavernous Hemangioma: 2-Dimensional Operative Video. *Oper Surg.* 2019;16:E144–5.

Publisher’s Note Springer Nature remains neutral with regard to jurisdictional claims in published maps and institutional affiliations.