



# Suspected common bile duct stones: reduction of unnecessary ERCP by pre-procedural imaging and timing of ERCP

Christina J. Sperna Weiland<sup>1,2</sup> · Evelien C. Verschoor<sup>2</sup> · Alexander C. Poen<sup>3</sup> · Xavier J. M. N. Smeets<sup>4</sup> · Niels G. Venneman<sup>5</sup> · Abha Bhalla<sup>6</sup> · Ben J. M. Witteman<sup>7</sup> · Hester C. Timmerhuis<sup>2,8</sup> · Devica S. Umans<sup>2,9</sup> · Jeanin E. van Hooft<sup>10</sup> · Marco J. Bruno<sup>11</sup> · P. Fockens<sup>9</sup> · Robert C. Verdonk<sup>12</sup> · Joost P. H. Drenth<sup>1</sup> · Erwin J. M. van Geenen<sup>1</sup> · for the Dutch Pancreatitis Study Group

Received: 24 May 2022 / Accepted: 7 September 2022 / Published online: 26 September 2022  
© The Author(s) 2022

## Abstract

**Background** Endoscopic retrograde cholangiopancreatography (ERCP) is the procedure of choice to remove sludge/stones from the common bile duct (CBD). In a small but clinically important proportion of patients with suspected choledocholithiasis ERCP is negative. This is undesirable because of ERCP associated morbidity. We aimed to map the diagnostic pathway leading up to ERCP and evaluate ERCP outcome.

**Methods** We established a prospective multicenter cohort of patients with suspected CBD stones. We assessed the determinants that were associated with CBD sludge or stone detection upon ERCP.

**Results** We established a cohort of 707 patients with suspected CBD sludge or stones (62% female, median age 59 years). ERCP was negative for CBD sludge or stones in 155 patients (22%). Patients with positive ERCPs frequently had pre-procedural endoscopic ultrasonography (EUS) or magnetic resonance cholangiopancreatography (MRCP) imaging (44% vs. 35%;  $P=0.045$ ). The likelihood of ERCP sludge and stones detection was higher when the time interval between EUS or MRCP and ERCP was less than 2 days (odds ratio 2.35; 95% CI 1.25–4.44;  $P=0.008$ ; number needed to harm 7.7).

**Conclusions** Even in the current era of society guidelines and use of advanced imaging CBD sludge or stones are absent in one out of five ERCPs performed for suspected CBD stones. The proportion of unnecessary ERCPs is lower in case of pre-procedural EUS or MRCP. A shorter time interval between EUS or MRCP increases the yield of ERCP for suspected CBD stones and should, therefore, preferably be performed within 2 days before ERCP.

✉ Christina J. Sperna Weiland  
christa.spernaweiland@radboudumc.nl

<sup>1</sup> Department of Gastroenterology and Hepatology, Radboudumc, Postbus 9101, 6500 HB Nijmegen, The Netherlands

<sup>2</sup> Department of Research and Development, St. Antonius ziekenhuis, Nieuwegein, The Netherlands

<sup>3</sup> Department of Gastroenterology and Hepatology, Isala Clinics, Zwolle, The Netherlands

<sup>4</sup> Department of Gastroenterology and Hepatology, Jeroen Bosch Ziekenhuis, Den Bosch, The Netherlands

<sup>5</sup> Department of Gastroenterology and Hepatology, Medisch Spectrum Twente, Enschede, The Netherlands

<sup>6</sup> Department of Gastroenterology and Hepatology, Hagaziekenhuis, The Hague, The Netherlands

<sup>7</sup> Department of Gastroenterology and Hepatology, Gelderse Vallei Hospital, Ede, The Netherlands

<sup>8</sup> Department of Surgery, St. Antonius ziekenhuis, Nieuwegein, The Netherlands

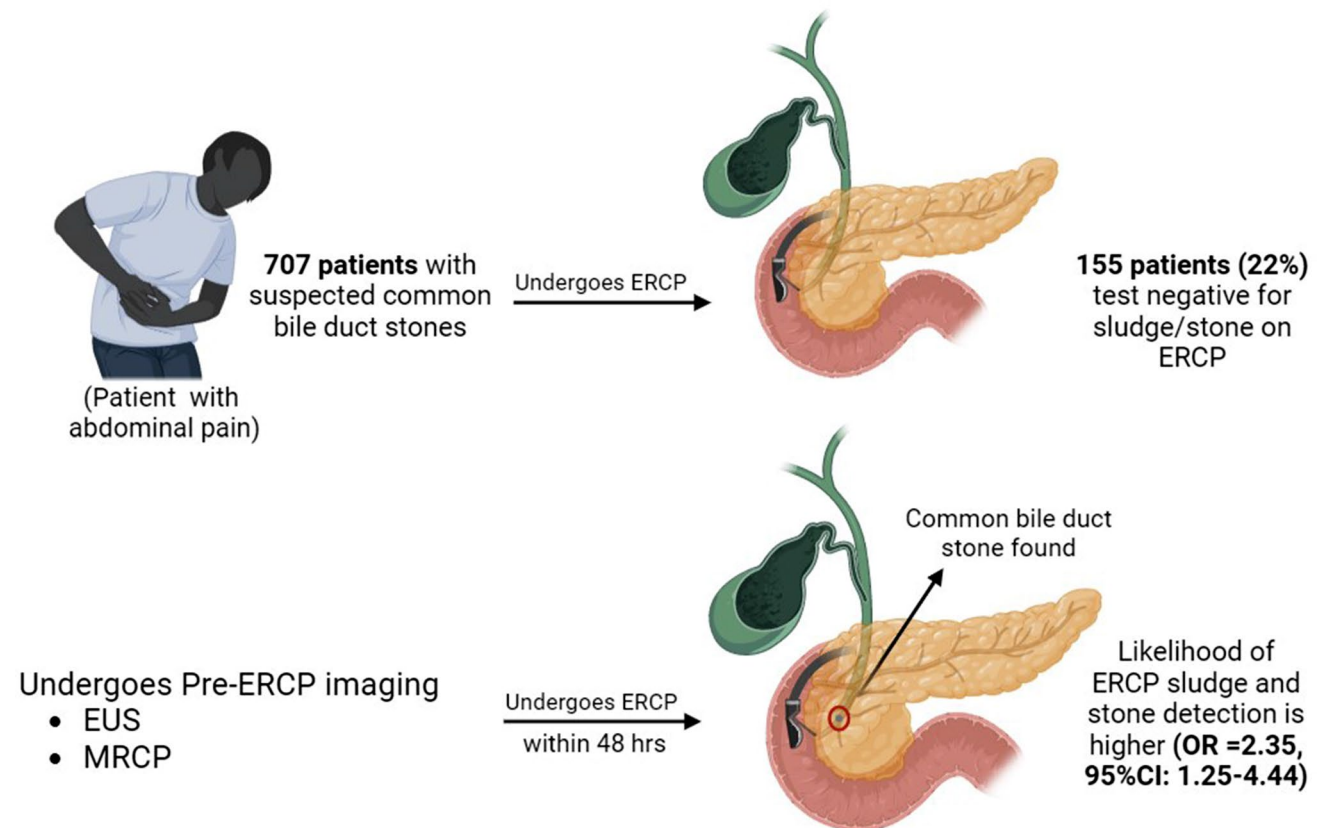
<sup>9</sup> Department of Gastroenterology and Hepatology, Amsterdam Gastroenterology & Metabolism, Amsterdam UMC, Amsterdam, The Netherlands

<sup>10</sup> Department of Gastroenterology and Hepatology, Leiden University Medical Center, Leiden, The Netherlands

<sup>11</sup> Department of Gastroenterology and Hepatology, Erasmus Medical Center, Rotterdam, The Netherlands

<sup>12</sup> Department of Gastroenterology and Hepatology, St. Antonius ziekenhuis, Nieuwegein, The Netherlands

## Graphical abstract



**Keywords** Choledocholithiasis · Gallstones · Cholangiopancreatography · Endoscopic retrograde · Cholangiopancreatography magnetic resonance

## Abbreviations

ASGE	American society for gastrointestinal endoscopy
CBD	Common bile duct
CI	Confidence interval
CT	Computed tomography
ERCP	Endoscopic retrograde cholangiopancreatography
EUS	Endoscopic ultrasound
IQR	Interquartile range
MRCP	Magnetic resonance cholangiopancreatography
NNH	Number needed to harm
NPV	Negative predictive value
PPV	Positive predictive value
SD	Standard deviation
ULN	Upper limit of normal
US	Ultrasound
LR	Likelihood ratio

Common bile duct (CBD) stones are a commonly occurring gastroenterological condition, with an estimated yearly

incidence of 45 per 100,000 in Western populations, increasing with age [1–3]. CBD stones can lead to symptoms and complications, such as abdominal pain, jaundice, infection, and acute pancreatitis [4]. Guidelines recommend removal of CBD stones with endoscopic retrograde cholangiopancreatography (ERCP) [4–6].

Although ERCP is considered the gold standard for the treatment of CBD stones, the diagnostic role of this modality is limited by its invasive nature and safety issues, most notably the risk of post-ERCP pancreatitis (3.5–9.7%), cholangitis (0.5–3.0%), bleeding (0.3–9.6%), perforation (0.08–0.6%), and anesthesia-related adverse events (0.02%) [7, 8]. Therefore it is important to curtail ERCP use to patients with the highest likelihood of CBD sludge or stones. The recommended diagnostic work-up consists of liver biochemistry and abdominal ultrasound (US) or cross-sectional imaging [4, 6]. In order to avoid unnecessary ERCPs, guidelines stratify patients with suspected CBD stones into three risk categories. Patients with a low likelihood (< 10%) of CBD stones are recommended for a prompt cholecystectomy

without prior ERCP. Patients with a persistent clinical suspicion of CBD stones, but insufficient evidence of stones on abdominal US or cross-sectional imaging, are stratified with an intermediate likelihood (10–50%) of CBD stones. These patients are recommended to receive further imaging with endoscopic ultrasound (EUS) or magnetic resonance cholangiopancreatography (MRCP), representing less-invasive and lower-risk alternatives for initial evaluation. For patients with a high likelihood (> 50%) it is advised to proceed directly to an ERCP procedure for stone clearance. However, even in patients with a high likelihood of CBD stones established after appropriate diagnostic work-up, 17–57% do not have stones or sludge on ERCP while being exposed to the risk of developing potential harmful complications [9–14].

We aimed to map the diagnostic pathway leading up to ERCP in current clinical practice and evaluate the ERCP outcome in a prospectively collected multicenter cohort of patients with suspected CBD stones.

## Materials and methods

### Study design and setting

We created a prospective cohort of patients with suspected CBD stones from a nationwide multicenter, parallel-group open-label randomized controlled superiority trial [15]. Briefly, this trial investigated whether aggressive periprocedural hydration with lactated Ringer's solution additional to standard rectal non-steroidal anti-inflammatory drugs (NSAIDs) could prevent post-ERCP pancreatitis in moderate-to-high-risk patients. The study received permission from the Medical Research Ethics Committees United (NL52341.100.15, April 14, 2015). Written informed consent was obtained from all participants. The study included 826 adult patients (18–85 years), from 22 Dutch hospitals, who underwent ERCP between June 2015 and June 2019. This study adheres to the Strengthening the Reporting of Observational studies in Epidemiology (STROBE) guideline.

### Participants

Patients with ongoing acute pancreatitis were not included in the original trial. For the current study, patients were excluded when no ERCP was performed, if suspected CBD stones was not the indication for performing the ERCP, or when the presence of CBD sludge/stones could not be

assessed during ERCP due to technical failure. ERCPs were performed in an outpatient and inpatient setting.

### Data collection

During the trial, data were prospectively collected using standardized case record forms. The study coordinator verified these through patient chart review. We collected the following data for each patient: presence of fever (> 38 °C) or/and chills before ERCP, biochemical test results within 1 month prior to ERCP, and results from abdominal imaging (abdominal US, computed tomography (CT), EUS, or MRCP) performed in the 3 months preceding ERCP. In case abdominal US or CT was performed, this was scored as initial imaging according to the guidelines, while performance of EUS or MRCP was considered additional imaging.

### Outcomes and definitions

The primary endpoint was the proportion of ERCPs negative for sludge or stones in the CBD, irrespective of other ERCP findings (e.g., cholangiocarcinoma, papillary stenosis). The ERCP was considered positive upon clear photographic documentation of filling defect on cholangiography or when the endoscopist's report documented stones or any sludge. ERCP was considered negative in all other cases. Work-up toward ERCP was left at the discretion of the treating clinician. For this reason, we were able to assess the endpoint in a cohort of patients which reflects real-world practice work-up (whole cohort) and a subgroup of patients who have had a work-up as defined by the American Society for Gastrointestinal Endoscopy (ASGE) 2019 guidelines. This subgroup included patients stratified to intermediate likelihood of CBD stones who underwent additional imaging and patients stratified to high likelihood of CBD stones who went straight to ERCP.

Each patient was retrospectively categorized in a low, intermediate, or high likelihood of CBD stones, according to the ASGE guideline for endoscopic management of CBD stones of 2010 and 2019 [4, 5] and the European Society for Gastrointestinal Endoscopy (ESGE) guideline of 2019 [6]. Patients were considered to have a high likelihood for CBD stones according the ASGE 2019 guideline when they met one of the following criteria: CBD stone on abdominal US/cross-sectional imaging, clinical ascending cholangitis, or combination of total bilirubin > 4 mg/dL and dilated CBD on abdominal US/cross-sectional imaging. Intermediate likelihood for CBD stones when they met one of the following

criteria: abnormal liver biochemical tests, age > 55 years or dilated CBD on abdominal US/cross-sectional imaging. All other patients were considered as having low likelihood for CBD stones. Clinical ascending cholangitis was defined according to the 2018 Tokyo Guideline [16]. See Appendix Table S1, for details of ASGE and ESGE guideline criteria.

Secondary endpoints included the effects of pre-ERCP imaging on CBD sludge/stone visualization during ERCP, the timing (in days) of pre-ERCP imaging, and the ERCP-related complication rate in relation to presence of CBD stones. We used the Cotton criteria to describe ERCP-related complications (pancreatitis, cholangitis, bleeding, and perforation) [17].

## Statistical analysis

Baseline variables were assessed by mean with standard deviation (SD) or median with interquartile range (IQR). Primary and secondary endpoints were assessed using Mann–Whitney *U* test, Pearson  $\chi^2$  test, or Fisher exact test as appropriate. All statistical analyses were conducted using

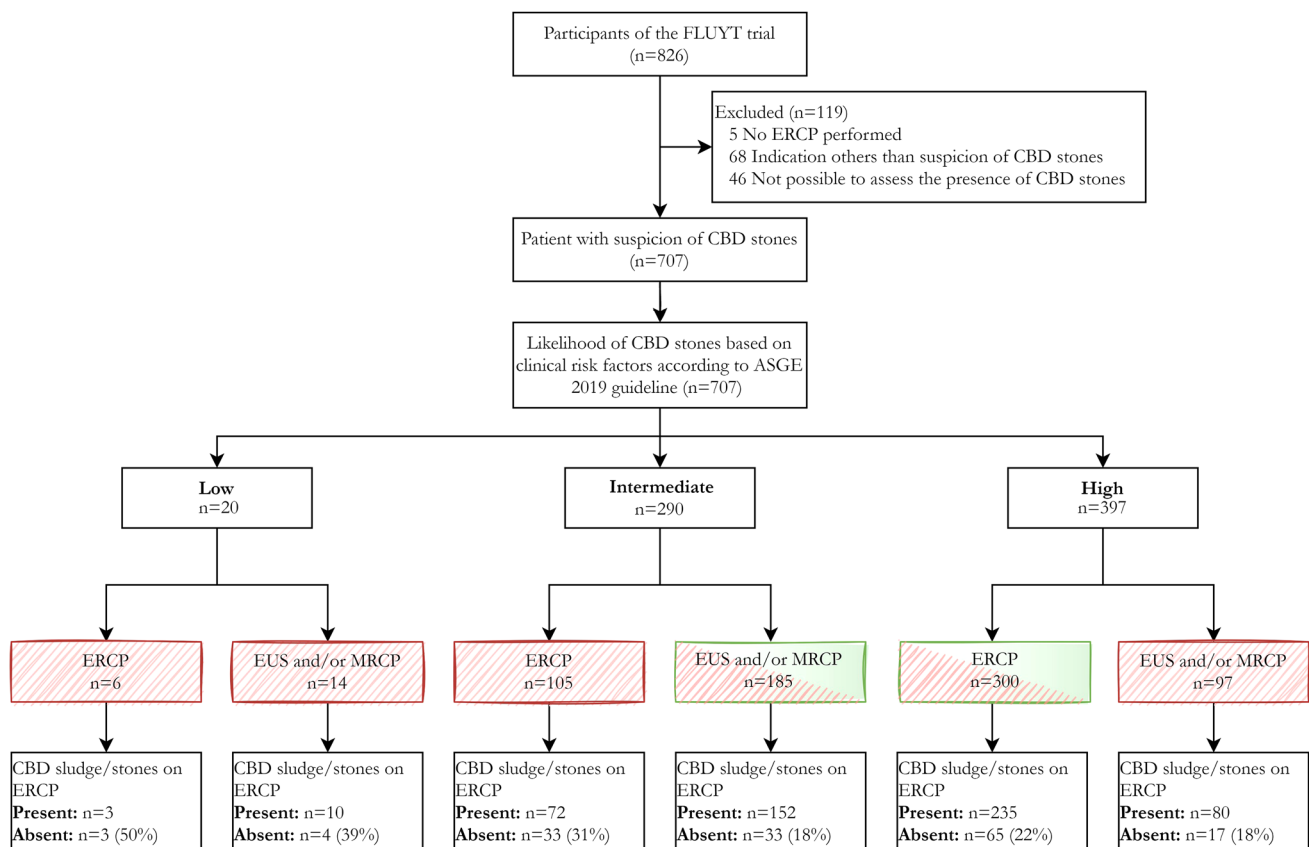
IBM SPSS Statistics for Windows, version 24, with statistical significance set at a two-sided alpha level of 5%.

## Results

### Cohort identification and characteristics

A total of 826 patients were enrolled in the original multicenter randomized trial. We excluded 119 patients (Fig. 1), because of an indication for ERCP other than (suspected) stones in the CBD ( $n=68$ ), procedure failure of ERCP (e.g., failed cannulation, ampulla not reached) ( $n=46$ ), and no performance of ERCP ( $n=5$ ). Finally, we included a total of 707 patients in the current study.

The median age of the patients was 59 years, and 436 (62%) patients were female (Table 1). The majority of the patients (92%) had biochemical tests examined prior to ERCP. Abdominal US was performed in 617 (87%) patients and CT in 90 (13%) patients. 338 (48%) patients suffered from acute cholangitis. According to the ASGE 2019



**Fig. 1** Patient selection and risk stratification of included patients with suspected common bile duct stones. ASGE American society for gastrointestinal endoscopy, CBD common bile duct, ERCP endoscopic retrograde cholangiopancreatography EUS endoscopic

ultrasonography, MRCP magnetic resonance cholangiopancreatography. Fully striped box work-up according to real-world practice, Half striped box work-up according to ASGE 2019 guideline

**Table 1** Patient characteristics

	<i>N</i> (%)	Median (IQR)
Age (years)		59 (46–71)
Female sex	436 (62%)	
Body mass index		27 (24–30)
Previous cholecystectomy	187 (26%)	
Cholangitis*	338 (48%)	
Biochemical test values	644 (91%)	
Days before ERCP		1 (0–3)
Total bilirubin (umol/L) > ULN	470/632 (74%)	44 (16–84)
ALT (U/L) > ULN	586/635 (92%)	278 (116–446)
AST (U/L) > ULN	538/612 (88%)	141 (68–245)
ALP (U/L) > ULN	520/618 (84%)	218 (137–323)
GGT (U/L) > ULN	599/628 (95%)	430 (214–727)
Abdominal US	617 (87%)	
CBD stone or sludge	191 (31%)	
Dilated CBD	387 (63%)	
Previous cholecystectomy	81	
No previous cholecystectomy	306	
CT-scan	90 (13%)	
CBD stone or sludge	41	
Dilated CBD	65	
Imaging positive for choledocholithiasis prior to ERCP	296 (42%)	
MRCP	71/82 (87%)	
EUS	216/225 (96%)	

\*According to Tokyo Guidelines 2018

AST Aspartate transaminase, ALT Alanine transaminase, ALP Alkaline phosphatase, GGT Gamma-glutamyltransferase, US Ultrasound, CT computed tomography, EUS endoscopic ultrasonography, MRCP magnetic resonance cholangiopancreatography, ERCP endoscopic retrograde cholangiopancreatography, IQR Interquartile range, ULN Upper limit of normal, CBD common bile duct

guideline, 20 patients were considered as low likelihood, 290 patients as intermediate likelihood, and 397 patients as high likelihood for choledocholithiasis. 485 patients (69%) received work-up as recommended by the ASGE 2019 guideline. See Appendix Table S2, for risk stratification and results of the ASGE 2010 and ESGE 2019.

### CBD stones or sludge on ERCP

In 155 of the 707 patients, no CBD stones or sludge were visualized during ERCP. This resulted in a negative ERCP rate of 22%. In the 485 patients who underwent a strict work-up according to the ASGE 2019 guidelines, the negative ERCP rate was comparable (20%;  $n = 88$ ) (Fig. 1). 81 (12%) patients developed ERCP-related adverse events: post-ERCP pancreatitis ( $n = 54$ ), bleeding ( $n = 21$ ), perforation ( $n = 5$ ), and cholangitis ( $n = 6$ ). The adverse events were evenly distributed between those with a negative [ $n = 21$  (14%)]

and positive ERCP ( $n = 60$  (11%);  $P = 0.36$ , Table 2). Of the 155 patients with a negative ERCP, 132 patients (85%) still received a sphincterotomy.

### Pre-ERCP imaging

Almost all patients ( $n = 689$  (98%)) underwent imaging leading to ERCP: abdominal US in 617 (87%), CT in 90 (13%), EUS in 225 (32%), MRCP in 82 (11%) patients (Table 1). The majority ( $n = 658$  (93%)) had imaging of the biliary system in the 31 days prior to the ERCP (see Appendix Table S3 and S4, which demonstrates the outcome of the additional imaging performed 0–31 days before ERCP and its effect on ERCP outcome). Of all patients who did not receive abdominal US ( $n = 90$ ), 80% (72 cases) received other imaging types (CT/MRCP/EUS). Patients with positive ERCP findings had undergone more additional imaging (EUS/MRCP) before ERCP compared to patients with negative ERCP findings (44% vs. 35%, respectively;  $P = 0.045$ ) (Table 2). The ERCP in patients stratified to the intermediate likelihood group was more often positive when EUS/MRCP was performed (82% vs 69%;  $P = 0.008$ ). The negative predictive value for EUS and MRCP was 22 and 30%, respectively. Positive predictive value for EUS and MRCP was 81 and 85%, respectively. See Appendix Figure S1 and Table S2, which demonstrates the effect of prior additional imaging for ASGE and ESGE.

### Timing of pre-ERCP imaging

EUS was performed in a significantly shorter time interval before the ERCP compared to the MRCP (median of 1 vs. 8.5 days;  $P < 0.001$ ). The median time interval between EUS and ERCP was longer in those with a negative ERCP for CBD stones (3 days) compared to patients with a positive ERCP (1 day) ( $P = 0.001$ ). Also, the proportion of CBD stone negative ERCPs increases when the time interval between EUS/MRCP and the ERCP became longer (Fig. 2). By performing pre-ERCP imaging by EUS/MRCP within 2 days more CBD stones were visualized during ERCP (87%;  $n = 139/160$ ) compared with more distant imaging (74%;  $n = 76/103$ ) (3–31 days) [odds ratio 2.35; 95% CI 1.25–4.44;  $P = 0.008$ , number needed to harm (NNH) 7.7].

### Discussion

In 22% of the 707 patients who underwent an ERCP for suspected CBD stones in our prospective multicenter cohort, no CBD sludge or stones was present. When additional pre-ERCP imaging was performed (EUS/MRCP), the chance of CBD sludge or stones during ERCP increased. Timing is of

**Table 2** Imaging and complications in patients with negative and positive ERCP

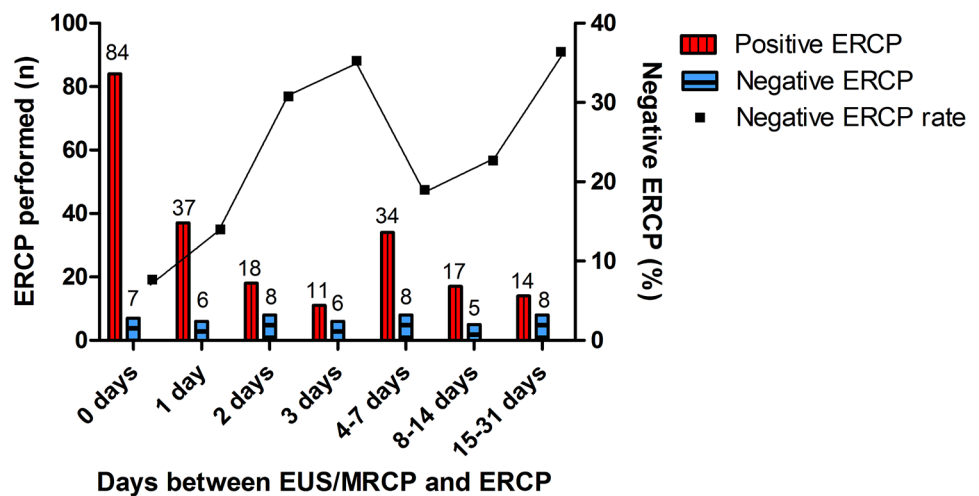
	Negative ERCP <i>N</i> =155	Positive ERCP <i>N</i> =552	<i>P</i> value
Abdominal US	136 (88%)	481 (87%)	0.84 <sup>a</sup>
Additional imaging (EUS/MRCP/CT)	49/136 (36%)	225/481 (47%)	<b>0.039<sup>a</sup></b>
No abdominal US	19 (12%)	71 (13%)	0.84 <sup>a</sup>
Additional imaging (EUS/MRCP/CT)	13/19 (68%)	59/71 (83%)	0.40 <sup>a</sup>
Abdominal US	136 (88)	481 (87)	0.84 <sup>a</sup>
Days before ERCP	2 (1–6)	2 (1–8)	0.68 <sup>b</sup>
CT-scan	20 (13%)	70 (13%)	0.94 <sup>a</sup>
Days before ERCP	7 (4–27)	5 (2–15)	0.22 <sup>b</sup>
EUS	42 (27)	183 (33)	0.15 <sup>a</sup>
Days before ERCP	3 (1–7)	1 (0–4)	<b>0.001<sup>b</sup></b>
MRCP	14 (9%)	68 (12%)	0.26 <sup>a</sup>
Days before ERCP	7 (2–22)	9 (2–28)	0.88 <sup>b</sup>
EUS and/or MRCP	54 (35%)	242 (44%)	<b>0.045<sup>a</sup></b>
Adverse events of ERCP	21 (14%)	60 (11%)	0.36 <sup>a</sup>
Pancreatitis	14 (9%)	40 (7%)	0.46 <sup>a</sup>
Bleeding	5 (3%)	16 (3%)	1.0 <sup>c</sup>
Perforation	2 (1%)	3 (<1%)	0.58 <sup>c</sup>
Cholangitis	0 (0%)	6 (1%)	0.30 <sup>c</sup>

Bold indicates  $P < 0.05$  as significant

Data are *n* (%) or median (IQR). <sup>a</sup>Pearson's Chi-Square test; <sup>b</sup>Mann–Whitney *U* test; <sup>c</sup>Fisher's Exact test

*IQR* interquartile range, *US* Ultrasound, *EUS* endoscopic ultrasonography, *MRCP* magnetic resonance cholangiopancreatography, *CT* computed tomography, *ERCP* endoscopic retrograde cholangiopancreatography

**Fig. 2** ERCP outcome in patients who underwent pre-ERCP imaging. *EUS* endoscopic ultrasonography, *MRCP* magnetic resonance cholangiopancreatography, *ERCP* endoscopic retrograde cholangiopancreatography



importance: a delay of more than two days between diagnostic imaging (EUS/ MRCP) and ERCP reduces the chance of a positive ERCP. We advocate that additional imaging by EUS or MRCP should be repeated if the time interval exceeds 2 days.

In this study, we demonstrated that EUS or MRCP prior to ERCP increases the proportion of positive ERCPS ( $P=0.045$ ), which is in line with previous studies [18–21]. We did not find this association for the individual imaging modalities. For MRCPs, this might be as result of the low

number of performed MRCPs (82 cases, 12%) and the long time interval between MRCP and ERCP (median of 7 days (positive) and 9 days (negative)). There might be room for improvement since approximately one third (36%) of the patients categorized to the intermediate likelihood group according to ASGE 2019 did not receive an EUS or MRCP. Hence, we would like to emphasize the importance of additional imaging in patients categorized in the intermediate likelihood group for CBD stones when implementing ASGE and ESGE 2019 guidelines (see Appendix Table S2).

In addition, timing of pre-ERCP imaging plays an important role with regard to the probability of CBD stone/sludge at ERCP. A shorter interval between EUS and ERCP (median of 1 vs. 3 days) and immediate prior imaging by EUS or MRCP ( $\leq 2$  days vs. 3–31 days) resulted in more positive ERCPs. However this last finding was mainly due to the contribution of the EUS procedure within 2 days. This time interval should be short because obstructing CBD stones may migrate spontaneously to the duodenum over time [22, 23]. Size of the stone might also be a factor of influence to the probability of spontaneous migration of CBD stones. However, in the case of MRCP/EUS-proven CBD stones, waiting for spontaneously stone migration might not be the best option. Importantly, when ERCP or cholecystectomy is postponed, patients are at risk for gallstone-related complications [24, 25]. In our cohort, 2/29 patients had a CBD stone on abdominal imaging in 1–3 months before ERCP and developed a cholangitis in the time before ERCP (see Appendix Table S5, which demonstrates the outcome of imaging 32–93 days before ERCP). These biliary events could have been prevented by earlier ERCP. Furthermore, it might be beneficial to perform an EUS and ERCP in a single session as opposed to two separate endoscopic procedures with two sedation schemes and two hospital visits. However, the endoscopist has to be trained to perform both EUS and ERCP, which could be a point of attention in the training of future endoscopists. In addition, cost-effectiveness studies show that the costs of routine use of EUS/MRCP and the potential logistical inefficiency of a combined EUS with optional ERCP endoscopy program (in which time has to be reserved for ERCPs that may not be necessary after negative EUS) could be compensated by the reduction in health care expenditure because of avoidance of (unnecessary) ERCPs and ERCP-related complications [26–30].

Our study found that a post-ERCP pancreatitis occurred in 14 (9%) of the 155 patients with a negative ERCP. Better selection would have avoided these complications. More accurate patient selection can be achieved by performing pre-ERCP EUS or MRCP in case of suspected CBD stones irrespective of guideline stratification. The associated NNH for performing pre-ERCP EUS/MRCP to reduce the incidence of post-ERCP pancreatitis from 9 to 0% is 11.1 patients. To prevent all ERCP-related complications in this group (14%) the NNH is even lower (7.1 patients). There is limited data available on the rate of negative ERCPs considered acceptable to ERCPists. A survey among gastroenterologist performed in 2012 determined that a negative ERCP rate of 25% was considered acceptable [31]. Since that time there is a more wide-spread availability of EUS (and MRCP) and, therefore, we believe 25% negative ERCP rate is not acceptable these days [32].

A major aim of the revised ASGE guideline was to reduce CBD stone negative ERCPs by enlarging the intermediate

likelihood group through excluding patients from the former high likelihood group [5]. In our cohort, we observed similar rates of stratification to the high likelihood groups (62 and 56% in the ASGE 2010 and 2019, respectively), compared to other studies who did not [13, 14]. A reason might be that we stratified patients later in their disease course and, therefore, they reach the higher threshold for the bilirubin levels as established in 2019 criteria [4, 5]. Nevertheless, our proportion of negative ERCPs for high likelihood patients (21%) is in line with previous studies (17–34%) [10, 13, 14, 33, 34]. It is possible that the relatively large proportion of our cohort (42%, 296 cases) who underwent pre-ERCP EUS/MRCP imaging accounts for the observation that our overall negative ERCP rate of 22% is relatively low compared to previous studies with overall rates between 11 and 62% [10–14, 33, 35].

For any diagnostic study to potentially impact future clinical practice, results should be obtained in a representative population and setting. This multicenter study closely mimics daily practice and contains a large number of patients of both university and large teaching hospitals. We believe that our results are generalizable to daily practice and are relevant to clinicians managing patients with suspected CBD stones.

We acknowledge several potential limitations of this analysis. First, in the original multicenter randomized trial, patients who underwent pre-ERCP imaging and had no presumptive evidence of sludge or stones in the CBD, did not proceed to ERCP were not included in the current study. This might have introduced selection bias in the patients stratified, especially to the intermediate likelihood group. Second, there was no uniform timing for risk classification, because the study protocol did not include a recommended work-up for a patient. Standardized work-up was not feasible due to the diversity within the population of in- and outpatient performed ERCP and the related decision-making toward ERCP. This may have influenced the distribution of patients among the risk categories, but reflects the heterogeneity of the general population in which ERCP is considered. Ideally, a prospective cohort of all patients with suspected sludge or stones in the CBD, referred for ERCP, needs to be considered, in which all patients should undergo work-up according to the guideline.

In conclusion, even in the current era CBD sludge or stones are absent in one out of five ERCPs performed for suspected CBD stones despite previous imaging or work-up according to ASGE 2019 guideline. EUS or MRCP before ERCP should be considered in all patients to allow optimal patient selection and avoiding potential overutilization of diagnostic ERCP. When time interval between EUS/MRCP exceeds 2 days imaging should be repeated to increase the yield of ERCP for suspected CBD stones.

**Supplementary Information** The online version contains supplementary material available at <https://doi.org/10.1007/s00464-022-09615-x>.

**Acknowledgements** The authors wish to thank all the principal investigators of the study sites involved in the FLUYT trial.

**Author contributions** CJSW, EJMG: conception and design; analysis and interpretation of the data; drafting of the article; critical revision of the article for important intellectual content; final approval of the article. ECV: drafting of the article; analysis and interpretation of the data; drafting of the article; critical revision of the article for important intellectual content; final approval of the article. ACP, NGV, AB, BJMW, HCT, DSU, JEH, MJB, PF, RCV: critical revision of the article for important intellectual content; final approval of the article. XJNMS, JPHD: drafting of the article; critical revision of the article for important intellectual content; final approval of the article.

**Funding** The study was funded by the Netherlands Organisation for Health Research and Development (ZonMw; Grant Number 837001506) and the Radboud university medical center. ZonMw had no role in study design, data collection, data analysis, data interpretation, or writing of the report.

## Declarations

**Disclosures** Christina J. Sperna Weiland, Evelien C. Verschoor, Alexander C. Poen, Xavier J.N.M. Smeets, Niels G. Venneman, Abha Bhalla, Ben J.M. Witteman, Hester C. Timmerhuis, Devica S. Umans, and Robert C. Verdonk do not have potential conflicts of interest or disclosures to report. Prof. Dr. Jeanin E. van Hooft reports grants and personal fees from Cook Medical, personal fees from Boston Scientific, Olympus and Medtronic, outside the submitted work. Prof. Dr. Marco J. Bruno reports grants and personal fees from Boston Scientific, grants and personal fees from Cook Medical, grants from Pentax Medical, 3 M, InterScope and Viatrix, outside the submitted work. Prof. Dr. Paul Fockens reports consulting fees from Cook and Olympus, outside the submitted work. Prof. Dr. Joost P.H. Drenth reports grants from Gilead, outside the submitted work. Dr. Erwin J.M. van Geenen reports grants from Viatrix and Olympus, personal fees from MTW-Endoskopie, outside the submitted work.

**Open Access** This article is licensed under a Creative Commons Attribution 4.0 International License, which permits use, sharing, adaptation, distribution and reproduction in any medium or format, as long as you give appropriate credit to the original author(s) and the source, provide a link to the Creative Commons licence, and indicate if changes were made. The images or other third party material in this article are included in the article's Creative Commons licence, unless indicated otherwise in a credit line to the material. If material is not included in the article's Creative Commons licence and your intended use is not permitted by statutory regulation or exceeds the permitted use, you will need to obtain permission directly from the copyright holder. To view a copy of this licence, visit <http://creativecommons.org/licenses/by/4.0/>.

## References

- Shaffer EA (2005) Epidemiology and risk factors for gallstone disease: has the paradigm changed in the 21st century? *Curr Gastroenterol Rep* 7:132–140. <https://doi.org/10.1007/s11894-005-0051-8>
- Everhart JE, Khare M, Hill M, Maurer KR (1999) Prevalence and ethnic differences in gallbladder disease in the United States. *Gastroenterology* 117:632–639. [https://doi.org/10.1016/S0016-5085\(99\)70456-7](https://doi.org/10.1016/S0016-5085(99)70456-7)
- Halldestam I, Kullman E, Borch K (2009) Incidence of and potential risk factors for gallstone disease in a general population sample. *Br J Surg* 96:1315–1322. <https://doi.org/10.1002/bjs.6687>
- Maple JT, Ben-Menachem T, Anderson MA, Appalaneni V, Banerjee S, Cash BD, Fisher L, Harrison ME, Fanelli RD, Fukami N, Ikenberry SO, Jain R, Khan K, Krinsky ML, Strohmeyer L, Dominitz JA (2010) The role of endoscopy in the evaluation of suspected choledocholithiasis. *Gastrointest Endosc* 71:1–9. <https://doi.org/10.1016/j.gie.2009.09.041>
- Buxbaum JL, Abbas Fehmi SM, Sultan S, Fishman DS, Qumseya BJ, Cortessis VK, Schilperoord H, Kysh L, Matsuoka L, Yachimski P, Agrawal D, Gurudu SR, Jamil LH, Jue TL, Khashab MA, Law JK, Lee JK, Naveed M, Sawhney MS, Thosani N, Yang J, Wani SB, Wani SB (2019) ASGE guideline on the role of endoscopy in the evaluation and management of choledocholithiasis. *Gastrointest Endosc* 89:1075–1105.e15. <https://doi.org/10.1016/j.gie.2018.10.001>
- Manes G, Paspatis G, Aabakken L, Anderloni A, Arvanitakis M, Ah-Soune P, Barthet M, Domagk D, Dumonceau JM, Gigot JF, Hritz I, Karamanolis G, Laghi A, Mariani A, Paraskeva K, Pohl J, Ponchon T, Swahn F, Ter Steege RWF, Tringali A, Vezakis A, Williams EJ, Van Hooft JE (2019) Endoscopic management of common bile duct stones: European society of gastrointestinal endoscopy (ESGE) guideline. *Endoscopy* 51:472–491. <https://doi.org/10.1055/a-0862-0346>
- Dumonceau J-M, Kapral C, Aabakken L, Papanikolaou IS, Tringali A, Vanbiervliet G, Beyna T, Dinis-Ribeiro M, Hritz I, Mariani A, Paspatis G, Radaelli F, Lakhtakia S, Veitch AM, van Hooft JE (2020) ERCP-related adverse events: European society of gastrointestinal endoscopy (ESGE) guideline. *Endoscopy* 52:127–149. <https://doi.org/10.1055/a-1075-4080>
- Chandrasekhara V, Khashab MA, Muthusamy VR, Acosta RD, Agrawal D, Bruining DH, Eloubeidi MA, Fanelli RD, Faulx AL, Gurudu SR, Kothari S, Lightdale JR, Qumseya BJ, Shaukat A, Wang A, Wani SB, Yang J, DeWitt JM (2017) Adverse events associated with ERCP. *Gastrointest Endosc* 85:32–47. <https://doi.org/10.1016/j.gie.2016.06.051>
- Park JK, Lee JK, Il YJ, Lee K, Park JK, Lee KH, Lee KT (2018) Long term outcome of EUS-based strategy for suspected choledocholithiasis but negative CT finding. *Scand J Gastroenterol* 53:1381–1387. <https://doi.org/10.1080/00365521.2018.1524021>
- Lee HW, Song TJ, Park DH, Lee SS, Seo DW, Lee SK, Kim MH, Jun JH, Moon JE, Song YH (2019) Diagnostic performance of the current risk-stratified approach with computed tomography for suspected choledocholithiasis and its options when negative finding. *Hepatobiliary Pancreat Dis Int* 18:366–372. <https://doi.org/10.1016/j.hbpd.2019.06.005>
- Anderloni A, Ballarè M, Pagliarulo M, Conte D, Galeazzi M, Orsello M, Andorno S, Del Piano M (2014) Prospective evaluation of early endoscopic ultrasonography for triage in suspected choledocholithiasis: results from a large single centre series. *Dig Liver Dis* 46:335–339. <https://doi.org/10.1016/j.dld.2013.11.007>
- Jagtap N, Hs Y, Tandan M, Basha J, Chavan R, Nabi Z, Kalapala R, Reddy PM, Ramchandani M, Gupta R, Lakhtakia S, Darishetty S, Rao GV, Reddy DN (2020) Clinical utility of ESGE and ASGE guidelines for prediction of suspected choledocholithiasis in patients undergoing cholecystectomy. *Endoscopy* 52:569–573. <https://doi.org/10.1055/a-1117-3451>
- Chandran A, Rashtak S, Patil P, Gottlieb A, Bernstam E, Guha S, Ramireddy S, Badillo R, DaVee RT, Kao LS, Thosani N (2020) Comparing diagnostic accuracy of current practice guidelines in predicting choledocholithiasis: outcomes from a large healthcare



- system comprising both academic and community settings. *Gastrointest Endosc*. <https://doi.org/10.1016/j.gie.2020.10.033>
14. Jacob JS, Lee ME, Chew EY, Thrift AP, Sealock RJ (2020) Evaluating the revised American society for gastrointestinal endoscopy guidelines for common bile duct stone diagnosis. *Clin Endosc* 54(2):269–274
  15. Sperna Weiland CJ et al (2021) Aggressive fluid hydration to prevent post-ERCP pancreatitis (FLUYT): a multicentre open-label randomised controlled superiority trial. *Lancet Gastroenterol Hepatol* 6(5):350–358
  16. Kiriyama S, Kozaka K, Takada T, Strasberg SM, Pitt HA, Gabata T, Hata J, Liau KH, Miura F, Horiguchi A, Liu KH, Su CH, Wada K, Jagannath P, Itoi T, Gouma DJ, Mori Y, Mukai S, Giménez ME, Huang WSW, Kim MH, Okamoto K, Belli G, Dervenis C, Chan ACW, Lau WY, Endo I, Gomi H, Yoshida M, Mayumi T, Baron TH, de Santibañes E, Teoh AYB, Hwang TL, Ker CG, Chen MF, Han HS, Yoon YS, Choi IS, Yoon DS, Higuchi R, Kitano S, Inomata M, Deziel DJ, Jonas E, Hirata K, Sumiyama Y, Inui K, Yamamoto M (2018) Tokyo guidelines 2018: diagnostic criteria and severity grading of acute cholangitis (with videos). *J Hepatobiliary Pancreat Sci* 25:17–30. <https://doi.org/10.1002/jhbp.512>
  17. Cotton PB, Lehman G, Vennes J, Geenen JE, Russell RCG, Meyers WC, Liguory C, Nickl N (1991) Endoscopic sphincterotomy complications and their management: an attempt at consensus. *Gastrointest Endosc* 37:383–393. [https://doi.org/10.1016/S0016-5107\(91\)70740-2](https://doi.org/10.1016/S0016-5107(91)70740-2)
  18. Canto MIF, Chak A, Stellato T, Sivak J (1998) Endoscopic ultrasonography versus cholangiography for the diagnosis of choledocholithiasis. *Gastrointest Endosc* 47:439–448. [https://doi.org/10.1016/S0016-5107\(98\)70242-1](https://doi.org/10.1016/S0016-5107(98)70242-1)
  19. Zidi SH, Prat F, Le Guen O, Rondeau Y, Rocher L, Fritsch J, Choury AD, Pelletier G (1999) Use of magnetic resonance cholangiography in the diagnosis of choledocholithiasis: prospective comparison with a reference imaging method. *Gut* 44:118–122. <https://doi.org/10.1136/gut.44.1.118>
  20. Karakan T, Cindoruk M, Alagozlu H, Ergun M, Dumlu S, Unal S (2009) EUS versus endoscopic retrograde cholangiography for patients with intermediate probability of bile duct stones: a prospective randomized trial. *Gastrointest Endosc* 69:244–252. <https://doi.org/10.1016/j.gie.2008.05.023>
  21. Lee YT, Chan FKL, Leung WK, Chan HLY, Wu JCY, Yung MY, Ng EKW, Lau JYW, Sung JJY (2008) Comparison of EUS and ERCP in the investigation with suspected biliary obstruction caused by choledocholithiasis: a randomized study. *Gastrointest Endosc* 67:660–668. <https://doi.org/10.1016/j.gie.2007.07.025>
  22. Van Geenen EJM, Van Der Peet DL, Mulder CJJ, Cuesta MA, Bruno MJ (2009) Recurrent acute biliary pancreatitis: the protective role of cholecystectomy and endoscopic sphincterotomy. *Surg Endosc* 23:950–956. <https://doi.org/10.1007/s00464-009-0339-0>
  23. Lefemine V, Morgan RJ (2011) Spontaneous passage of common bile duct stones in jaundiced patients. *Hepatobiliary Pancreat Dis Int* 10:209–213. [https://doi.org/10.1016/S1499-3872\(11\)60033-7](https://doi.org/10.1016/S1499-3872(11)60033-7)
  24. Da Costa DW, Bouwense SA, Schepers NJ, Besselink MG, Van Santvoort HC, Van Brunschot S, Bakker OJ, Bollen TL, Dejong CH, Van Gooor H, Boermeester MA, Bruno MJ, Van Eijck CH, Timmer R, Weusten BL, Consten EC, Brink MA, Spanier BMW, Bilgen EJS, Nieuwenhuijs VB, Hofker HS, Rosman C, Voorburg AM, Bosscha K, Van Duijvendijk P, Gerritsen JJ, Heisterkamp J, De Hingh IH, Witteman BJ, Kruij PM, Scheepers JJ, Molenaar IQ, Schaapherder AF, Manusama ER, Van Der Waaij LA, Van Unen J, Dijkgraaf MG, Van Ramshorst B, Gooszen HG, Boerma D (2015) Same-admission versus interval cholecystectomy for mild gallstone pancreatitis (PONCHO): a multicentre randomised controlled trial. *Lancet* 386:1261–1268. [https://doi.org/10.1016/S0140-6736\(15\)00274-3](https://doi.org/10.1016/S0140-6736(15)00274-3)
  25. Benjaminov F, Stein A, Lichtman G, Pomeranz I, Konikoff FM (2013) Consecutive versus separate sessions of endoscopic ultrasound (EUS) and endoscopic retrograde cholangiopancreatography (ERCP) for symptomatic choledocholithiasis. *Surg Endosc* 27:2117–2121. <https://doi.org/10.1007/s00464-012-2720-7>
  26. Ko C, Buxbaum J (2021) Do the 2019 ASGE choledocholithiasis guidelines reduce diagnostic ERCP? *Gastrointest Endosc* 93:1360–1361. <https://doi.org/10.1016/j.gie.2020.12.046>
  27. Arguedas MR, Dupont AW, Wilcox CM (2001) Where do ERCP, endoscopic ultrasound, magnetic resonance cholangiopancreatography, and intraoperative cholangiography fit in the management of acute biliary pancreatitis? A decision analysis model. *Am J Gastroenterol* 96:2892–2899. <https://doi.org/10.1111/j.1572-0241.2001.04244.x>
  28. Scheiman JM, Carlos RC, Barnett JL, Elta GH, Nostrant TT, Chey WD, Francis IR, Nandi PS (2001) Can endoscopic ultrasound or magnetic resonance cholangiopancreatography replace ERCP in patients with suspected biliary disease? A prospective trial and cost analysis. *Am J Gastroenterol* 96:2900–2904. <https://doi.org/10.1111/j.1572-0241.2001.04245.x>
  29. Buscarini E, Tansini P, Vallisa D, Zambelli A, Buscarini L (2003) EUS for suspected choledocholithiasis: do benefits outweigh costs? A prospective, controlled study. *Gastrointest Endosc* 57:510–518. <https://doi.org/10.1067/mge.2003.149>
  30. Romagnuolo J, Currie G, Center Advanced Endoscopy Center Study Group (2005) Noninvasive vs. selective invasive biliary imaging for acute biliary pancreatitis: an economic evaluation by using decision tree analysis. *Gastrointest Endosc* 61:86–97. [https://doi.org/10.1016/s0016-5107\(04\)02472-1](https://doi.org/10.1016/s0016-5107(04)02472-1)
  31. Elmunzer BJ, Debenedet AT, Volk ML, Sonnenday CJ, Waljee AK, Fontana RJ, Oza AB, Singal A, Englesbe MJ, Scheiman JM (2012) Clinical yield of diagnostic endoscopic retrograde cholangiopancreatography in orthotopic liver transplant recipients with suspected biliary complications. *Liver Transpl* 18:1479–1484. <https://doi.org/10.1002/lt.23535>
  32. Chisholm PR, Patel AH, Law RJ, Schulman AR, Bedi AO, Kwon RS, Wamsteker EJ, Anderson MA, Elta GH, Govani SM, Prabhu A (2019) Preoperative predictors of choledocholithiasis in patients presenting with acute calculous cholecystitis. *Gastrointest Endosc* 89:977–983.e2. <https://doi.org/10.1016/j.gie.2018.11.017>
  33. Magalhães J (2015) Endoscopic retrograde cholangiopancreatography for suspected choledocholithiasis: from guidelines to clinical practice. *World J Gastrointest Endosc* 7:128. <https://doi.org/10.4253/wjge.v7.i2.128>
  34. Ebrahim M, Sorensen LT, Jorgensen LN, Kalaitzakis E (2018) Current clinical algorithms for predicting common bile duct stones have only moderate accuracy. *Dig Endosc* 30:477–484. <https://doi.org/10.1111/den.12994>
  35. Rubin MIN, Thosani NC, Tanikella R, Wolf DS, Fallon MB, Lukens FJ (2013) Endoscopic retrograde cholangiopancreatography for suspected choledocholithiasis: testing the current guidelines. *Dig Liver Dis* 45:744–749. <https://doi.org/10.1016/j.dld.2013.02.005>

**Publisher's Note** Springer Nature remains neutral with regard to jurisdictional claims in published maps and institutional affiliations.