

## Erratum to: Strategies of laparoscopic thyroidectomy for treatment of substernal goiter via areola approach

Cunchuan Wang<sup>1</sup> · Peng Sun<sup>1</sup> · Jinyi Li<sup>1</sup> · Wah Yang<sup>1</sup> · Jingge Yang<sup>1</sup> · Zhiqi Feng<sup>1</sup> · Guo Cao<sup>1</sup> · Shing Lee<sup>1</sup>

Published online: 7 July 2016  
© Springer Science+Business Media New York 2016

**Erratum to: Surg Endosc**  
**DOI 10.1007/s00464-016-4814-0**

Figures 2, 3, and 4 were submitted in error. Revised Figs. 2, 3, and 4 are now included.

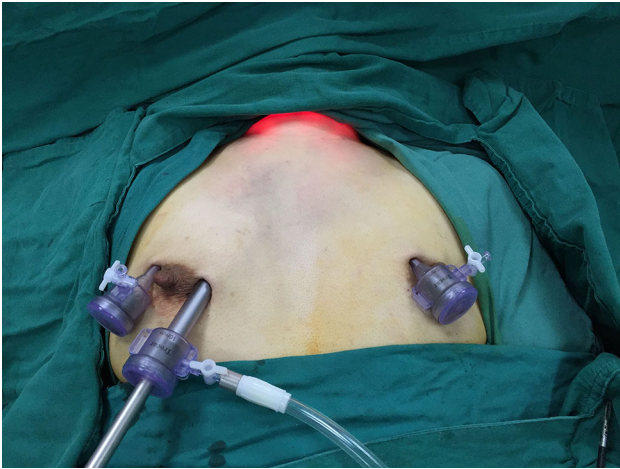---

The online version of the original article can be found under  
doi:[10.1007/s00464-016-4814-0](https://doi.org/10.1007/s00464-016-4814-0).

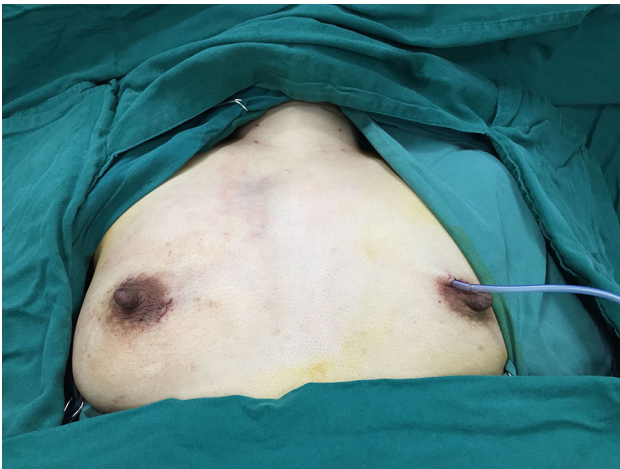
---

✉ Cunchuan Wang  
wangcunchuan@tom.com; twcc@jnu.edu.cn

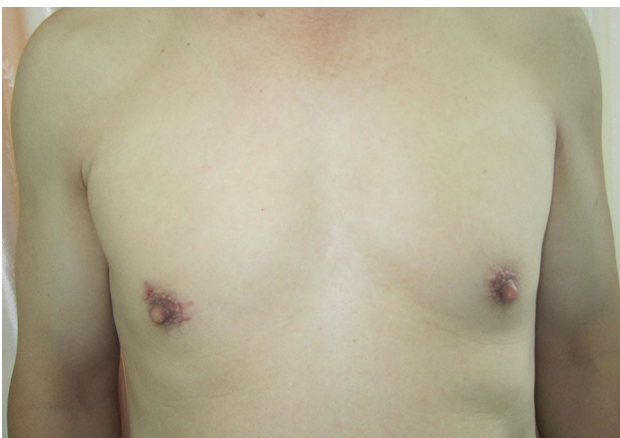<sup>1</sup> Department of General Surgery, First Affiliated Hospital of Jinan University, Guangzhou 510630, China



**Fig. 2** External view after positioning the trocars



**Fig. 3** Incisions of endoscopic thyroidectomy for treatment of substernal goiter via areola approach



**Fig. 4** Incision scars are un conspicuous and concealed (3 months after surgery)