

# *Anaplasma marginale* and *Anaplasma phagocytophilum*: Rickettsiales pathogens of veterinary and public health significance

Farhan Ahmad Atif<sup>1</sup>

Received: 1 July 2015 / Accepted: 24 August 2015 / Published online: 7 September 2015  
© Springer-Verlag Berlin Heidelberg 2015

**Abstract** *Anaplasma marginale* and *Anaplasma phagocytophilum* are the most important tick-borne bacteria of veterinary and public health significance in the family *Anaplasmataceae*. The objective of current review is to provide knowledge on ecology and epidemiology of *A. phagocytophilum* and compare major similarities and differences of *A. marginale* and *A. phagocytophilum*. Bovine anaplasmosis is globally distributed tick-borne disease of livestock with great economic importance in cattle industry. *A. phagocytophilum*, a cosmopolitan zoonotic tick transmitted pathogen of wide mammalian hosts. The infection in domestic animals is generally referred as tick-borne fever. Concurrent infections exist in ticks, domestic and wild animals in same geographic area. All age groups are susceptible, but the prevalence increases with age. Movement of susceptible domestic animals from tick free non-endemic regions to disease endemic regions is the major risk factor of bovine anaplasmosis and tick-borne fever. Recreational activities or any other high-risk tick exposure habits as well as blood transfusion are important risk factors of human granulocytic anaplasmosis. After infection, individuals remain life-long carriers. Clinical anaplasmosis is usually diagnosed upon examination of stained blood smears. Generally, detection of serum antibodies followed by molecular diagnosis is usually recommended. There are problems of sensitivity and cross-reactivity with both the *Anaplasma* species during serological tests. Tetracyclines are the drugs of choice for treatment and elimination of

anaplasmosis in animals and humans. Universal vaccine is not available for either *A. marginale* or *A. phagocytophilum*, effective against geographically diverse strains. Major control measures for bovine anaplasmosis and tick-borne fever include rearing of tick-resistant breeds, endemic stability, breeding *Anaplasma*-free herds, identification of regional vectors, domestic/wild reservoirs and control, habitat modification, biological control, chemotherapy, and vaccinations (anaplasmosis and/or tick vaccination). Minimizing the tick exposure activities, identification and control of reservoirs are important control measures for human granulocytic anaplasmosis.

**Keywords** Epidemiology · Control · *Anaplasma marginale* · *Anaplasma phagocytophilum*

## Introduction

*Anaplasma marginale* and *Anaplasma phagocytophilum* are the most important tick-borne bacteria of veterinary and public health significance. Bovine anaplasmosis (BA) caused by *A. marginale* is a globally distributed tick-borne disease with great economic importance in cattle industry including Asia, Africa, Australia, Southern Europe, and Central and South America (Jongejan and Uilenberg 2004), biologically transmitted by *Rhipicephalus* ticks and mechanically by biting flies, blood-contaminated needles, and farm equipments. *Anaplasma phagocytophilum* is an emerging globally distributed, zoonotic tick-borne pathogen of wide mammalian hosts, transmitted mainly by *Ixodes* ticks (de la Fuente et al. 2005). The infection in domestic animals is generally referred as tick-borne fever, responsible for important economic loss to cattle and sheep industry (Stuen 2007; Grøva et al. 2011). *Anaplasma phagocytophilum* is known since 200 years, but it became real research focus after first case of human

✉ Farhan Ahmad Atif  
atifvet\_2000@yahoo.com

<sup>1</sup> Department of Animal Sciences, University College of Agriculture, University of Sargodha, Sargodha 40100, Pakistan

granulocytic anaplasmosis (HGA) in 1986 (Maeda et al. 1987). These closely related bacteria share some common features such as coexistence during concurrent infection in ticks, domestic, wild ruminant reservoir hosts in same geographic region (de la Fuente et al. 2005). In terms of developing diagnostic assays, vaccines, and future research, similarities and differences of these organisms have to be considered. Limited reviews are available in this perspective. The current review focus on updated knowledge on epidemiology, ecology of *A. phagocytophilum* and broad comparison of *A. marginale* and *A. phagocytophilum* for effective prevention and control of anaplasmosis in humans and animals.

## *Anaplasma phagocytophilum*

### Morphology

*Anaplasma phagocytophilum* is alpha pleomorphic gram-negative bacterium measuring 0.4 to 1.3 or 2  $\mu\text{m}$  in size. The bacterial outer membrane is often coarse with irregular periplasmic spaces without capsule. Bacterium lacks lipopolysaccharide and peptidoglycan. This obligate intracellular bacterium, after staining with Romanowsky stain, show purple color mulberry-like microcolonies called Morulae with 1.5 to 2.5 or 6  $\mu\text{m}$  in diameter (Foggie 1951; Woldehiwet and Scott 1982; Rikihisa et al. 1997; Popov et al. 1998). The bacteria can also be stained with May-Grünwald or Wright-Giemsa stains. Three species previously belong to *Ehrlichia* were now included in genus *Anaplasma* namely *Anaplasma phagocytophilum*, earlier known as *Ehrlichia phagocytophila*, the causative agent of human granulocytic anaplasmosis; *Anaplasma bovis* (formerly known as *Ehrlichia bovis*); and *Anaplasma platys* (formerly *Ehrlichia platys*; Dumler et al. 2001; Table 1). All these aforementioned pathogens infect blood cells of their respective hosts.

### Life cycle

So far, no transovarial transmission (from adult ticks to eggs) has been reported (Woldehiwet 2010), except for moose tick (*Dermacentor albipictus*). Transovarial transmission ability of moose tick is due to atypical feeding systems as compared to normal *Ixodes* infection cycle (Baldrige et al. 2009). A reservoir host is required to keep *A. phagocytophilum* in nature. Life cycle starts with blood meal after tick bite to infected mammals. *A. phagocytophilum* survives and maintain in larva/nymph to adult developmental stages of ticks and transmit this to mammals during the next blood meal (Telford et al. 1996; Ogden et al. 1998; Zhi et al. 2002).

### Clinical signs

Tick-borne fever is mostly seen in sheep and cattle, but it can also be demonstrated in goats, reindeer, and deer. In sheep, clinical signs include high fever, inappetence, dullness, sudden drop in milk yield, reduced weight gain, coughing, abortion, stillbirth and low fertility in sheep, and reduced semen quality in rams (CFSPH 2013). Dairy cattle upon its return from pasture usually becomes infected with variable severity of illness including dullness, anorexia, reduced milk production, respiratory distress, coughing, abortions, and stillbirth are common. The important finding that mild cases recover within 14 days and death is unusual outcome (Tuomi 1967; Taylor and Kenny 1980; Stuen et al. 1992; Grøva et al. 2011; CFSPH 2013). The *Anaplasma phagocytophilum*-suspected cases are usually subject to secondary infection with tick pyemia, pasteurellosis, and septicemic listeriosis. Anaplasmosis in equines is called as equine granulocytic anaplasmosis. Horses with more than 3 years of age develop severe disease including fever, anorexia, depression, petechial hemorrhages, icterus, ataxia, and distal limb edema and may have severe myopathy. Fever and lethargy is most commonly seen in canine granulocytic anaplasmosis. Infection in cats is called as feline granulocytic anaplasmosis, and cats show generalized nonspecific signs include fever, dullness, and anorexia (CFSPH 2013). In humans (human granulocytic anaplasmosis (HGA)), the major clinical signs include fever, headache, myalgias, and chills. Leucopenia, thrombocytopenia and/or anemia and elevated liver enzymes are usual hematological and biochemical finding in humans and all animals species (common in dog, cat, and humans) (Bakken et al. 1994; Aguerorosenfeld et al. 1996). Clinical signs 2–3 weeks after tick bite is suggestive of HGA. The HGA cannot be diagnosed only on the basis of clinical signs. Severe clinical signs include prolonged fever, septic shock-like illness, respiratory distress, acute renal failure, gastrointestinal tract bleeding, rhabdomyolysis, and secondary infections (AABB 2009).

The pathogenesis of HGA is inadequately understood. Little amount of bacteria in infected animal and human's peripheral blood indicate the presence of proinflammatory cytokines. In human patients, increased concentrations of serum gamma interferon and interleukin-10 protein have been detected during acute infection as compared to restorative or patients with no clinical signs (Dumler et al. 2000). This suggests that human monocytes, rather human neutrophils, are responsible for proinflammatory cytokine production.

### Epidemiology

**Geographic distribution** *Anaplasma phagocytophilum* is endemic or potentially endemic in 42 countries of the world with an overall case fatality of 5 % (Berger 2014). This has been detected throughout Europe, America (North and South), Asia

**Table 1** Classification of genus *Anaplasma*, *Ehrlichia*, and *Neorickettsia* of family Anaplasmataceae

<b>Kingdom:</b> Bacteria, <b>Phylum:</b> Proteobacteria, <b>Class:</b> Alpha Proteobacteria, <b>Order:</b> Rickettsiales, <b>Family:</b> Anaplasmataceae, <b>Genus:</b> <i>Anaplasma</i> , <i>Ehrlichia</i> , <i>Neorickettsia</i>				
Genus:	<i>Anaplasma</i>	<i>Host</i>	<i>Ehrlichia</i>	<i>Neorickettsia</i>
Species	<i>A. marginale</i>	Cattle	<i>E. canis</i>	<i>N. risticii</i>
	<i>A. centrale</i>	Cattle	<i>E. chaffeensis</i>	<i>N. semmetsu</i>
	<i>A. bovis</i>	Cattle	<i>E. ewingii</i>	
	<i>A. ovis</i>	Sheep, goat	<i>E. muris</i>	
	<i>A. platys</i>	Dogs	<i>E. ruminantium</i>	
	<i>Aegyptianella pullorum</i>	Birds		
	<i>A. phagocytophilum</i>	Wide host range: ruminants, small mammals, horses, birds, and humans		

*Candidatus Neoehrlichia mikurensis*<sup>a</sup>, previously known as *Candidatus Ehrlichia walkertii*

Dumler et al. 2001; Andersson and Raberg 2011

<sup>a</sup>This organism still needs to be classified in appropriate genus (Jahfari et al. 2012)

(Pakistan, India, Korea, and Japan) and Africa (Kawahara et al. 2006; Kang et al. 2013; M'ghirbi et al. 2012; Djiba et al. 2013; Stuen et al. 2013a; Borthakur et al. 2014; Razzaq et al. 2015; Pantchev et al. 2015). Human seroprevalence in disease endemic area of Wisconsin and New York (USA) is 15–36 %, whereas seroprevalence in Europe range from 1 and 20 % depending upon immunity, tick exposure, and age of the patients (CDC 2013). Majority of the human cases of infection in USA occur in June–July.

**Hosts** Sheep and cattle are the main hosts but infection has been detected in goat, horse, donkey, dog, cat, and wild ruminants. Definite reservoir hosts for *A. phagocytophilum* in animals and humans are not known to date. Identification of reservoirs is important for epidemiological standpoint. However, humans are the dead end host. *Anaplasma phagocytophilum* is most frequently been found in roe deer, red deer, and fallow deer, and the highest prevalence *A. phagocytophilum* is reported in roe deer and red deer ranging from 12 to 85 % (Hulínská et al. 2004; Zeman and Pecha 2008; Scharf et al. 2011; Overzier et al. 2013).

The pathogen has been detected in white tailed deer, sika deer, Korean water deer, wild boar (*Sus scrofa*), Alpine ibex (*Capra ibex*), chamois (*Rupicapra rupicapra*), mouflon (*Ovis musimon*), European bison (*Bison bonasus*), mule deer (*Odocoileus hemionus hemionus*), reindeer (*Rangifer tarandus*), elk (*Cervus elaphus nannodes*), llama (*Lama glama*), alpaca (*Vicugna pacos*), Suri alpaca (*Vicugna pacos*), Swedish moose (*Alces alces*), and birds (Tinkler et al. 2012; Stuen et al. 2013a; Malmsten et al. 2014); **small mammals:** dusky-footed wood rats (*Neotoma fuscipes*) (Rikihisa 2003), white-footed mice (*Peromyscus leucopus*) (Keesing et al. 2012), vole (*Clethrionomys gapperi*), Eastern chipmunk (*Tamias striatus*), squirrel (*Spermophilus lateralis*), Virginia opossum (*Didelphis virginiana*), striped skunk (*Mephitis*

*mephitis*); **insectivorous mammals:** hedgehog (*Erinaceus europaeus*), shrew; reptiles and snakes: northern alligator lizard (*Elgaria coeruleus*), Pacific gopher snake (*Pituophis catenifer*); **others:** cotton tail rabbit (*Sylvilagus floridanus*), gray fox (*Urocyon cinereoargenteus*), raccoon (*Procyon lotor*), timber wolf (*Canis lupus occidentalis*), American black bears (*Ursus americanus*) (Drazenovich et al. 2006), European brown bear (*Ursus arctos arctos*) (Víchová et al. 2010). In cattle, *A. phagocytophilum* is usually associated during concurrent infection with *Borrelia burgdorferi* and/or *A. marginale* (Hofmann-Lehmann et al. 2004; Berger 2014). Individuals recovered from acute disease develop persistent infection. This is a complex process having cyclic episodes of lowering and peak bacteremia phases, under the influence of host immunity. Persistently infected individuals serve as reservoir for maintenance and further spread of infection.

**Breed resistance** Little information is available on the breed resistance of tick-borne fever and granulocytic fevers of domestic and wild animals. As for bovine anaplasmosis, there is individual variance in susceptibility to ticks and tick-borne fever. Likewise, Old Norse sheep is naturally resistant to tick-borne infections than other Norwegian breeds (Stuen 2003; Stuen et al. 2011; Granquist et al. 2010b).

**Risk factors** Young domestic animals purchased from tick-free area and moved to tick-infested areas is the major risk factor of tick-borne fever (Tuomi 1967). It has been seen in some regions that the higher prevalence of roe deer and white tailed deer resulted in higher prevalence of anaplasmosis (Stuen et al. 2013a). Risk factors for human anaplasmosis include high-risk outdoor activities (such as hiking and gardening) and immunocompromised individuals (cancer treatments, prior organ transplants, HIV infection), and people after blood transfusion are at higher risk.

**Transmission** Ticks play a key role in multiplication, persistence, and pathogen transmission to mammalian hosts (Hodžić et al. 1998; Katavolos et al. 1998). The RNA interference (RNAi) technique identified that Salp16, a salivary gland protein of *I. scapularis* tick, is required for infectivity of salivary glands and further transmission (Ramakrishnan et al. 2005; Sukumaran et al. 2006). *Ixodes ricinus* is the main vector of *A. phagocytophilum* throughout Europe. Additionally, the pathogen has been detected with molecular methods in *I. persulcatus* from Latvia, Russia, and Estonia, as well as in *Dermacentor reticulatus*, *Haemaphysalis concinna*, and *I. ventralis* ticks (Santos et al. 2004; Masuzawa et al. 2008; Paulauskas et al. 2012; Tomanovic et al. 2013).

Bacterium is usually transmitted by *I. pacificus* (Western black-legged tick) in Western USA, but *Dermacentor variabilis* and *D. occidentalis* has also been reported from California (Holden et al. 2003; Lane et al. 2010; Rejmanek et al. 2011); by *I. scapularis* (deer tick or black-legged tick) (Lovrich et al. 2011; Roellig and Fang 2012) in Eastern USA; by *I. scapularis* and *Amblyomma americanum* in Florida (USA); by *I. spinipalpis* in North Colorado (USA) (Zeidner et al. 2000); by *I. scapularis* and *D. albipictus* in Canada (Baldrige et al. 2009; Krakowetz et al. 2014); by *I. persulcatus*, *I. nipponensis*, *I. ovatus*, *Dermacentor silvarum*, *Haemaphysalis megaspinosa*, *H. douglasii*, *H. longicornis*, and *H. japonica* in Asia (China, Japan, Korea, Russia); by *I. ricinus* and *Hyalomma (Hy.) marginatum*, *Hy. detritum* in North Africa (Algeria, Tunisia, and Morocco) (Sarih et al. 2005; M'ghirbi et al. 2012); and by *Hyalomma marginatum*, *Rhipicephalus turanicus*, and *Boophilus kohlsi* in Israel (Keysary et al. 2007).

As mentioned above, various studies indicate presence of *A. phagocytophilum* in different ticks, but the vector competence of only few American and European ticks have to date been proved yet for *I. ricinus*, *I. scapularis*, *I. pacificus*, and *I. spinipalpis* (Woldehiwet 2010). There is a lot more research scope for the identification of competent vectors and reservoir hosts. The prevalence of *A. phagocytophilum* in *I. scapularis* (<1–50 %) and *I. pacificus* (~1–10 %) in the USA has been reported, whereas *I. persulcatus* had <1 to 21.6 % in Asia (Stuenkel et al. 2013a). Prevalence in questing *I. ricinus* ticks in Europe range from 0.7 and 14.5 % (Hartelt et al. 2008; Rizzoli et al. 2014). The DNA of *A. phagocytophilum* has also been detected in Asia in *I. ovatus*, *I. nipponensis*, *D. silvarum*, *Haemaphysalis (H.) megaspinosa*, *H. douglasii*, *H. longicornis*, and *H. japonica* tick species. Furthermore, this pathogen has also been demonstrated in questing *I. dentatus*, *Amblyomma americanum*, *Dermacentor variabilis*, and *D. occidentalis* ticks (Goethert and Telford 2003).

Mechanical transmission by blood-sucking deer ked (*Lipoptena cervi*) from red deer (*Cervus elaphus*), roe deer (*Capreolus capreolus*), and fallow deer (*Dama dama*) have been reported using PCR (Vichová et al. 2011). Similarly,

there are reports of transplacental (lambs and calves), perinatal, blood transfusions, and nosocomial associated transmissions (Bakken et al. 1996; Horowitz et al. 1998; Dhand et al. 2007; Zhang et al. 2008; Annen et al. 2012; Henniger et al. 2013; Reppert et al. 2013). These modes of transmissions are further complicating the epidemiology of TBF and HGA.

## Strains

*Anaplasma phagocytophilum* have higher degree of genetic diversity, variation in pathogenicity, and host tropisms (Baráková et al. 2014). Higher degree of disparity exists in the prevalence of variants within and among hosts as well as between variants of different regions (Foley et al. 2008; Morissette et al. 2009). Genetic variability have been studied using *16S rRNA*, major surface protein coding genes (*msh4*), *groEL* heat-shock protein, *msh2/p44*, and *ankA* genes (Granquist et al. 2010c; Silaghi et al. 2011a, b).

Strains isolated from human patients can cause clinical disease in horses. This may be considered as valuable animal model for HGA (Madigan et al. 1995). American strain from horse was not infectious for ruminants (Stannard et al. 1969), whereas a European strain isolated from cattle did not show any clinical signs in horses (Pusterla et al. 1998). Rodents do not play a major role in the Europe whereas the white-footed mouse (*Peromyscus leucopus*) is the important reservoir of human pathogenic strain (Ap-ha) (Massung et al. 2003). The Ap-ha is pathogenic to humans; ruminants and mice can be experimentally infected, whereas the Ap-variant 1 is non-pathogenic to humans and mice, conversely infectious to deer and goats (Massung et al. 2003, 2005, 2006; Tate et al. 2005).

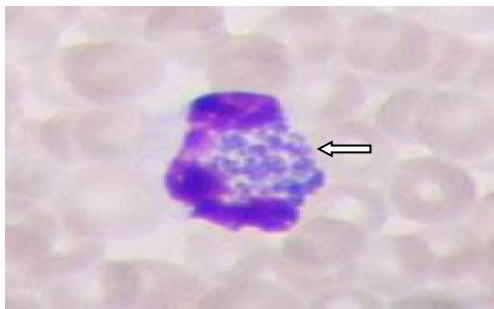
Several distinct ecological clusters have been established. While the latest reports based on multilocus sequencing mentioned that roe deer do not contribute in Europe for human infection but suspected to be the reservoir of Norwegian sheep strain belonging to different enzootic cycle (Stuenkel et al. 2010; Huhn et al. 2014). However, another study established link of human pathogenic strains to ungulates (Baráková et al. 2014). A potential human pathogenic strain of *A. phagocytophilum* in Europe has been connected to wild boars (Silaghi et al. 2014).

Four major ecotypes were identified. Ecotype-I has widest host range. Up till now, all human cases grouped in ecotype-I have the widest host range (including domesticated animals, red deer, wild boar, and urban hedgehogs) and further expanded incorporating *I. ricinus* ticks or urban vertebrates. Ecotype-II was associated with roe deer and some rodents, and ecotype-III included only rodents. Birds seem to have a different enzootic cycle and grouped in ecotype-IV. The study based on population genetic parameters; revealed that ecotype-I expressed the major expansion due to either increase in the population of *I. ricinus* ticks or in the domestic vertebrate hosts or both (Jahfari et al. 2014).

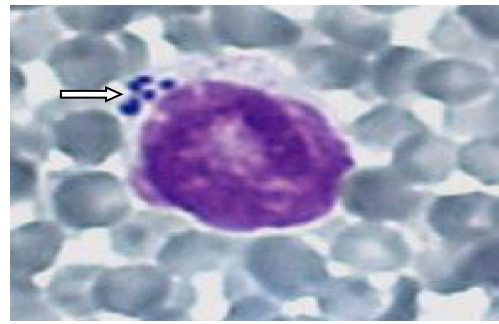


## Diagnosis

Clinical signs rarely aid in diagnosis. Usually, laboratory tests are required for confirmatory diagnosis. Blue intracytoplasmic inclusion microcolonies (morulae) can be usually seen in granulocytes, especially monocytes and neutrophils in peripheral blood-stained smear during acute phase of the infection (Figs. 1, 2, and 3). Hematological and biochemical parameters show anemia, leucopenia, thrombocytopenia, and increase of aspartate aminotransferase and alanine aminotransferase enzymes, 5–21 days after infected tick bite (Bakken and Dumler 2008). Confirmation of *Anaplasma* can be done either by electron microscopy of blood/organs smears, cell culture or immunohistochemistry. Common serological techniques for sero-diagnosis of *A. phagocytophilum* include indirect immunofluorescent antibody (IFA) test, ELISA, complement fixation test, and counter-current immunoelectrophoresis test. Commercially available “SNAP®4Dx®” ELISA test is good for rapid in-house detection of *A. phagocytophilum* antibodies in dog serum. The kit has been used successfully on sheep and horse sera (Granquist et al. 2010a; Hansen et al. 2010). Moreover, “MegaFLUO® ANAPLASMA phagocytophilum” is an indirect semiquantitative immunofluorescent test commercially available for the detection of *A. phagocytophilum* IgG antibodies in horse and dog serum or plasma. Fourfold rise of IgG antibodies in paired human samples within 2–4-week interval for immunofluorescence assay (IFA) is the gold standard test for HGA (CDC 2013). Various PCR techniques including conventional, nested, and real-time have been developed for the detection of *A. phagocytophilum* infection in blood and tissue samples targeting *16S rRNA*, *msh4*, *groEL*, *ankA*, and *p44* genes (Chen et al. 1994; Courtney et al. 2004; Alberti et al. 2005). Four to five times enlarged spleen with subscapular bleeding is the most important post-mortem finding of sheep, roe deer, and reindeer (Gordon et al. 1932; Øverås et al. 1993; Stuen 2003).



**Fig. 1** *Anaplasma phagocytophilum* (Morulae) in neutrophil of Giemsa-stained blood smear of new born calf (Henniger et al. 2013). Magnification 10×100



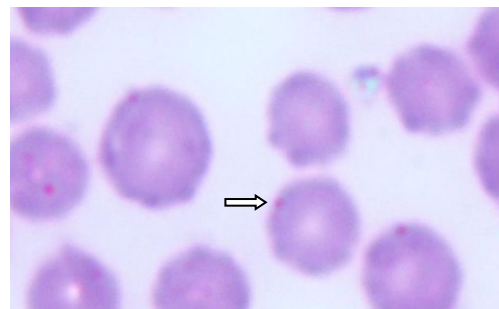
**Fig. 2** *Anaplasma phagocytophilum* (Morulae) in lymphocyte of Giemsa-stained blood smear of new born calf (Henniger et al. 2013). Magnification 10×100

## Treatment

Tetracycline is the drug of choice although levofloxacin, a fluoroquinolone, also showed *vivo* activity in cell culture in a human patient with history of chronic obstructive disease at the dose rate of 500 mg daily intravenous every 6 h for the first 24 h and oral 500 mg for 6 days (a total of 13 days treatment) but failed to control relapse of infection (Wormser et al. 2006).

Doxycycline, oral at the dose rate of 100 mg twice daily for 7–14 days, proved effective for adults in treating clinical human granulocytic anaplasmosis, and clinical recovery was noticed within 24 h using tetracycline at the dose rate of 500 mg/kg four times per day orally for 14 days (Goodman et al. 1996). Similarly, doxycycline hyclate 4.2 mg sustained release proved 100 % effective in preventing anaplasmosis as well as *B. burgdorferi* infection in mice (Zeidner et al. 2008). In pregnant women and patients with intolerant or allergy to tetracycline, rifampin at 10 mg/kg/day oral or chloramphenicol may be given (Goodman et al. 1996).

Long-acting oxytetracycline had proved effective for treatment and elimination of *Anaplasma phagocytophilum* in lambs at the dose rate of 20 and 10 mg/kg body weight intramuscular (Stuen and Bergstrom 2001). Similarly, this drug is also effective against other ruminants and horses. Doxycycline showed efficacy against canine and feline anaplasmosis in cat, dog, and captive timber wolf (CFSPH 2013).



**Fig. 3** *Anaplasma marginale* (arrow) in Giemsa-stained blood smears of dairy cow (*Bos indicus*). Magnification 10×100

## Prevention

Various antigens have been recommended as vaccine candidates, but the main problem associated with development of effective vaccine is the existence of different variants, selection of suitable conserved antigen, lack of cross-protection studies, and antigenic variation against diverse genotypes (Stuen et al. 2013a). Recently, an important development in vaccine development is the identification of three invasion proteins OmpA, Asp14, and Aip A that are involved in infection process. The antibodies against these proteins most effectively blocked the *A. phagocytophilum* infection of host cells. The binding domains of these proteins could be used to develop vaccine (Seidman et al. 2015).

## Control

Vaccine for *A. phagocytophilum* is not yet available. But, anti-tick vaccines would be a good option to control infection. Use of tick vaccines are environment-friendly, reduce tick load, decrease the incidence of tick-borne diseases (bovine anaplasmosis, babesiosis, and theileriosis), and minimize acaricide use (Graf et al. 2004; de la Fuente et al. 2006, 2011). Understanding vector-pathogen interactions would be an important tool for the control of tick and tick-borne pathogens. Immunization of animal reservoirs, high-risk animals, and human population would help in the control of anaplasmosis. Tick vaccines based on tick proteins interfere with tick vector competence such as SILK (Hajdušek et al. 2013; Zivkovic et al. 2010) and TROSPA (Hajdušek et al. 2013; Antunes et al. 2012). *Rhipicephalus (R.) microplus* tick proteins (BM86/BM95) have proved effective in reducing cattle tick infestations (Willadsen 2006; de la Fuente et al. 2007). Labuda et al. (2006) found that tick vaccine containing tick cement protein 64P of *Rhipicephalus appendiculatus* protected mice against *Ixodes ricinus* tick infestation and tick-associated encephalitis virus (TBEV). Subolesin (SUB) protein have resulted in lower *R. microplus* infestations and reduced levels of *A. marginale* and *B. bigemina* blood pathogens (de la Fuente et al. 2011; Merino et al. 2013). Tick proteins such as Q38, SILK, and SUB when used as vaccine reduced tick infestation and oviposition of *R. microplus* ticks (Merino et al. 2013).

Subolesin and akirin proteins are conserved among different vector species which might serve as a candidate for universal vaccine against various vector species, vector-borne diseases, and pathogen infection (de la Fuente et al. 2013). The vaccine that target both pathogen and vector for the prevention of ticks and anaplasmosis is a good option as in case of bovine anaplasmosis. Recently, Torina and associates (2014), developed vector-pathogen vaccine using both tick subolesin and *Anaplasma marginale* MSP1a proteins together. This resulted in lower tick infestation percentage and lower

weight of female *Boophilus microplus* ticks and reduced *A. marginale* infection in cattle (Torina et al. 2014).

## Similarities and differences

**Differences** *Anaplasma marginale* and *A. phagocytophilum* are closely related bacteria that invade different host cell types. Only ruminants are prone to *A. marginale* infection, whereas *A. phagocytophilum* is a hetero-genetic, zoonotic pathogen with diverse host range including domestic and wild animals, rodents, reptiles, birds, and humans infecting neutrophils, monocytes, or endothelial cells (Foggie 1951; Rikihisa 2011). Bovine anaplasmosis caused by *A. marginale* characterized by fever, severe anemia, jaundice, pale mucous membranes, brownish urine, abortion, decreased milk production, hyperexcitability, weight loss, and mortality without hemoglobinemia and hemoglobinuria during acute phase of the infection (Richey and Palmer 1990). Hemolytic anemia is the major hematological finding. Conversely, *A. phagocytophilum* infections generate sudden onset of fever accompanied by secondary infection which is the common sequel of tick-borne fever and HGA in contrast to bovine anaplasmosis. Characteristic microcolonies of the bacterium called Morulae develop in peripheral blood of granulocytes (especially neutrophils) and monocytes and their precursors in the bone marrow (Foggie 1951).

*Anaplasma phagocytophilum* can be cultured in *Ixodes scapularis* tick cells ISE6 and IDE8, as well as human promyelocytic cell line HL-60, and where *A. marginale* cannot propagate in continuous mammalian culture system owing to unknown cell surface receptors. The coinfection between these pathogens cannot be achieved in same tissue culture system or cell line (Munderloh et al. 2004). These organisms show different gene expression on *I. scapularis* tick cell lines (ISE6) (Zivkovic et al. 2009). Moreover, there are cellular and humoral complexities in *A. phagocytophilum* as compared to *A. marginale*.

**Similarities** *A. marginale* and *A. phagocytophilum* are closely related organisms on the basis of amino acid sequences (Aubry and Geale 2011). Concurrent infections, biological, mechanical, transplacental, and blood-contaminated/blood transfusion-associated transmission potentials are the major similarities for both *Anaplasma* species. Common treatment, prevention, elimination/chemosterilization, vaccination, tick control, breed resistance/susceptibility, selected common hosts, persistent infection, cross-reactivity, antigenic variation, super-infection, re-infection, strain diversity, host tropism or 16SrRNA gene base classification (family *Anaplasmataceae*), major surface proteins, pseudogenes, and hypothetical proteins are the common attributes of these tick-associated pathogens.

**Table 2** Comparison of *Anaplasma marginale* and *Anaplasma phagocytophilum* bacteria on epidemiology, diagnosis, treatment, prevention, and control

Character	<i>A. marginale</i>	<i>A. phagocytophilum</i>
Diseases	Bovine anaplasmosis (Kocan et al. 2010b)	Tick-borne fever (TBF) or pasture fever (cattle, sheep, goat) (Woldehiwet 2006; Stuen 2007) Canine granulocytic anaplasmosis (Alberti et al. 2005) Feline granulocytic anaplasmosis (Billeter et al. 2007) Equine granulocytic anaplasmosis (Alberti et al. 2005) Human granulocytic anaplasmosis (HGA) (Hing et al. 2014)
Common names	Yellow fever, Yellow bag, gall sickness (Whittier et al. 2009; Merck Veterinary Manual 2014)	Tick-borne fever, pasture fever (Merck Veterinary Manual 2014)
Zoonotic potential	No (Howden et al. 2010)	Yes (Hing et al. 2014)
Genome	1.2 Mb (Brayton et al. 2002)	1.47 Mb (Human) HZ strain (Rikihisa et al. 1997)
Morphology	Round inclusion bodies measuring 0.3–1.0 μm, at margins of RBCs (OIE 2012)	Morulae in monocytes, granulocytes (especially neutrophils), (1.5–2.5 μm) (Popov et al. 1998)
Geographic distribution	Worldwide, mostly tropical, subtropical and some temperate regions (OIE 2012)	Cosmopolitan (all Europe), northern hemisphere, America (North, South), Asia, Africa and Australia (individuals who visited out of country). Endemic or potentially endemic in 42 countries of the world (Berger 2014)
Incubation period	Cattle: 7–60 days (Kocan et al. 2003)	Humans: 7–14 days after infected tick bite Ruminants: 5–14 days after infected tick bite, 2–6 days Equine: 1–3 weeks Canine: 2–4 weeks (CFSPH 2013)
Hosts	Cattle, buffalo, American bison ( <i>Bison bison</i> ), mule deer, rocky mountain elk, white-tailed deer, black-tailed deer, roe deer (Aubry and Geale 2011)	Humans, domestic ruminants, roe deer, white-tailed deer, black-tailed deer, mule deer, rocky mountain elk, wild boar, rodents ticks, ruminants, rodents, equids, canids, birds, wild mammals (Stuen et al. 2013a)
Common hosts	Elk ( <i>Cervus elaphus nannodes</i> ), bison ( <i>Bison bison</i> ), (Stiller et al. 1981, 1983), white-tailed deer ( <i>Odocoileus virginianus</i> ), mule deer ( <i>Odocoileus hemionus hemionus</i> ), black-tailed deer ( <i>Odocoileus hemionus culumbianus</i> ; Aubry and Geale 2011)	Elk ( <i>Cervus elaphus nannodes</i> ), bison ( <i>Bison bison</i> ), and moose tick ( <i>Dermacentor albipictus</i> ; Stiller et al. 1981, 1983), white-tailed deer ( <i>Odocoileus virginianus</i> ), mule deer ( <i>Odocoileus hemionus hemionus</i> ), black-tailed deer ( <i>Odocoileus hemionus culumbianus</i> ; Aubry and Geale 2011)
Clinical signs	<b>Cattle:</b> Fever, severe anemia, jaundice, pale mucous membranes, brownish urine, abortion, decreased milk production, hyper-excitability, weight loss, and mortality without haemoglobinemia and haemoglobinuria during acute phase of the infection (Richey and Palmer 1990)	<b>Animals:</b> Sudden fever, agalactia, anorexia, dullness, abortion, low fertility in sheep while dogs, cats and horses show nonspecific signs. Animals subject to secondary infections (Pusterla and Braun 1997; Stuen et al. 2005). Damage of cellular and humoral immune system. <b>Humans:</b> Nonspecific flu-like signs, high fever, severe headache, malaise, and generalized myalgias (Dumler 1996)
Host cell	Erythrocytes (Rikihisa 2011) (Fig. 3)	Morulae in granulocytes (esp. neutrophils) and endothelial cells (Rikihisa 2011)
Hematological finding	Marked anemia (Atif et al. 2012a)	Anemia, leucopenia, thrombocytopenia (Henniger et al. 2013)
Serology	Competitive ELISA, card agglutination test (OIE 2012)	<b>Humans:</b> IFA, detect IgG antibodies (CDC 2013). <b>Dogs:</b> Commercially available “SNAP®4Dx”/“SNAP®4Dx® Plus Test” (this test detects two additional parasites; <i>Ehrlichia ewingii</i> and <i>A. platys</i> ) ELISA (“SNAP®4Dx”) also proved effective for diagnosis of <i>A. phagocytophilum</i> in sheep and horses <b>Horses, dogs:</b> “MegaFLUO® ANAPLASMA phagocytophilum” is an indirect semi-quantitative immunofluorescent test commercially available for the detection of <i>A. phagocytophilum</i> IgG antibodies in horse and dog serum or plasma.
Sero-diagnostic proteins	MSP 5 (Fosgate et al. 2010)	<b>TBF:</b> P44/MSP2 (Granquist et al. 2010c) <b>HGA:</b> P44/MSP2 (Granquist et al. 2010c)
Molecular target genes	<i>16S rRNA</i> , <i>groEL</i> , <i>gltA</i> , <i>msp1α</i> , <i>msp5</i> (Ybañez et al. 2013a); <i>msp1β</i> (Ashuma et al. 2013, Bilgiç et al. 2013); <i>msp4</i> (Hornok et al. 2007)	<i>16SrRNA</i> (Massung et al. 1998), <i>msp4</i> (Bown et al. 2007), <i>groEL</i> (Alberti et al. 2005), <i>p44/msp2</i> , <i>ankA</i> (Massung et al. 2000; Von Loewenich et al. 2003; Scharf et al. 2011)

**Table 2** (continued)

Character	<i>A. marginale</i>	<i>A. phagocytophilum</i>
Biochemistry	Increase total protein, total bilirubin, alanine aminotransferase (Ashuma et al. 2013)	Increase aspartate and alanine aminotransferase, lactate dehydrogenase, creatinine (Li et al. 2011)
Histopathology	Not usually performed (OIE 2012)	Not usually performed, immunohistochemistry (Lepidi et al. 2000)
Post-mortem lesions	Anaemia, jaundice, pale to yellow mucous membranes, enlarged spleen distended gall bladder and brown lymph nodes (Merck Veterinary Manual 2014)	<b>TBF (sheep):</b> Enlarged spleen (4–5 times) with subscapular bleeding (Øverås et al. 1993)
Samples for laboratory diagnosis	<b>Live animal:</b> EDTA blood for thin blood smear, serum for serodiagnosis, whole blood spots on filter paper Whatman no. 3 or 4 (Brandt 2009) <b>Dead animals:</b> Air-dried thin impression smears from the liver, heart, lungs, kidney, and from a peripheral blood vessel (OIE 2012)	Blood, serum, spleen (Malmsten et al. 2014)
Cell culture	<i>I. scapularis</i> cell lines ISE6, IDE8 (Munderloh et al. 2004; de la Fuente et al. 2007)	<i>I. scapularis</i> cell lines ISE6, IDE8, Human promyelocytic cell line, HL-60 (Munderloh et al. 1999, 2004; Woldehiwet et al. 2002; Zivkovic et al. 2009)
Diagnostic tests	Blood smear (early infection), cELISA (sero-daignosis), card agglutination test (sero-daignosis), PCR (OIE 2012), subinoculation blood in splenectomized calf is a gold standard test (Coetzee et al. 2006)	<b>Human HGA diagnostic tests sensitivity:</b> 0–7 days post-infection (PCR>blood smear>HL-60) 8–14 days post-infection (IFAT>PCR) 15–30 days post-infection (IFAT>PCR) 31–>60 days post-infection (IFAT) (Bakken and Dumler 2006)
Disease confirmation	Electron microscopy, seroconversion, PCR, subinoculation of infected blood in splenectomized calves	Electron microscopy, PCR; fourfold rise in IgG titer within 2–4-week interval (humans; CDC 2013)
Human pathogenic strains	Not pathogenic to humans	Yes, human pathogenic strains are linked to wild boar (Michalik et al. 2012)
Adhesion proteins	MSP1a (Garcia-Garcia et al. 2004)	MSP2 (Park et al. 2003)
Stain charge	Gram negative (Dumler et al. 2001)	Gram negative (Rikihisa 2011)
Proved vectors	<i>B. microphilus</i> , <i>B. annulatus</i> , <i>B. decoloratus</i> , <i>D. andersoni</i> , <i>Dermacentor albipictus</i> , <i>B. calcaratus</i> , <i>D. variabilis</i> , <i>Ixodes ricinus</i> , <i>I. scapularis</i> , <i>D. occidentalis</i> , <i>D. hunteri</i> , <i>Argas persicus</i> , <i>Ornithodoros lahorensis</i> , <i>Hyalomma excavatum</i> , <i>R. evertsi</i> , <i>H. rufipes</i> , and <i>R. simus</i> (OIE 2012)	<i>I. ricinus</i> , <i>I. scapularis</i> , <i>I. pacificus</i> , and <i>I. spinipalpis</i> (Woldehiwet 2010)
Major common vectors/pathogen detection	DNA detected in <i>I. ricinus</i> , <i>D. albipictus</i> , <i>I. scapularis</i> , <i>Dermacentor variabilis</i> , <i>D. occidentalis</i> (Goethert and Telford 2003), <i>Hyalomma asiaticum</i> (Zhang et al. 2013)	<i>I. ricinus</i> , <i>Dermacentor albipictus</i> , <i>I. scapularis</i> , <i>Dermacentor variabilis</i> , <i>D. occidentalis</i> (Stuen et al. 2013a; May and Strube 2014)
Mechanical/artific-ial transmission	Nose tongs, surgical, veterinary instruments, contaminated needle, horse fly ( <i>Tabanus</i> spp.), mosquitoes ( <i>Psorophora</i> spp.) (Kocan et al. 2010a; OIE 2012)	DNA detected in deer ked ( <i>Lipoptena cervi</i> ) (Vichová et al. 2011), <i>Syringophilidae</i> quill mites (Skoracki et al. 2006). Blood transfusion (Townsend et al. 2014; Proctor and Leiby 2015) Biting insects (Merck Veterinary Manual 2014)
Mechanical transmission (lice)	<i>Haematopinus tuberculatus</i> (da Silva et al. 2013)	Not available
Transplacental transmission	Experimental beef cow, natural cow calf (Salabarria and Pino 1988)	Cow (Henniger et al. 2013); dog (CFSPH 2013)
Transstadial/interstadial transmission ( <i>Boophilus</i> , <i>Ixodes</i> , <i>Dermacentor</i> spp.)	Yes ( <i>Boophilus annulatus</i> ) (Samish et al. 1993) <i>D. variabilis</i> and <i>D. andersoni</i> (Kocan et al. 2010b) <i>Rhipicephalus simus</i> (Walker et al. 2003)	Transstadial/interstadial transmission in <i>Ixodes ricinus</i> (Ogden et al. 2002)
Intrastadial transmission (ticks) (within the same life stage, by males)	Most common in <i>Dermacentor andersoni</i> , <i>D. variabilis</i> (Zaugg et al. 1986). <i>Rhipicephalus simus</i> (Walker et al. 2003)	Not available
Transovarial transmission (ticks)	No transovarial transmission in <i>Dermacentor</i> spp. of ticks (Kocan et al. 2004), except <i>D. albipictus</i>	No transovarial transmission in <i>Ixodes</i> ticks (Woldehiwet 2010) except <i>D. albipictus</i> (Baldrige et al. 2009)
MSP similarity	MSP2 (Chávez et al. 2012)	MSP2/P44 (Chávez et al. 2012)
Serodiagnostic proteins	MSP5 (Fosgate et al. 2010)	<b>Tick-borne fever:</b> P44 (Gaowa et al. 2014) <b>HGA:</b> P44 (Gaowa et al. 2014)
Persistent infection/carriers	Life-long (Richey 1991)	Life-long (Granquist et al. 2010b)



**Table 2** (continued)

Character	<i>A. marginale</i>	<i>A. phagocytophilum</i>
Risk factors	Variable region to regions High risk: >4 years tick-infested exotic/crossbred cattle (Atif et al. 2013) Cattle movement from non-endemic to endemic (Kocan et al. 2010a)	<b>TBF:</b> Young animals, purchased from tick free region and reared in tick infested pasture (Woldehiwet and Scott 1993). <b>HGA:</b> Rural farmers (Zhang et al. 2014). High-risk tick exposure outdoor activities (hiking, gardening), blood transfusion (Leiby and Gill 2004), and immunosuppression.
Concurrent infections	Yes (Hornok et al. 2007)	Yes, with <i>Borelia burgdorferi</i> and/or <i>A. marginale</i> and/or with other tick borne pathogens (Hornok et al. 2007)
Re-infection	Yes (Reinbold et al. 2010a)	Yes (Stuen 2003)
Super-infection	Yes (Palmer et al. 2004)	Yes (Stuen et al. 2009)
Treatment	Oxytetracycline (Atif et al. 2012b), chlortetracycline in feed) (Reinbold et al. 2010b)	<b>TBF:</b> Tetracycline or oxytetracycline hydrochloride 10 mg/kg body weight, daily (Stuen and Bergstrom 2001) <b>Horses:</b> Oxytetracycline (CFSPH 2013) <b>Dog:</b> Doxycycline (CFSPH 2013), <b>Cat:</b> Doxycycline 10 mg/kg BW intramuscular for 4 weeks (Goma et al. 2013) <b>Humans:</b> Tetracycline (doxycycline hyclate 100 mg, oral/intravenous twice daily for at least 3 days, preferred 7–14 days) (CDC 2013) and rifampin (for pregnant and tetracycline allergic patients) (Bakken and Dumler 2006)
Elimination/chemosterilization	Oxytetracycline (Atif et al. 2012b), chlortetracycline in feed (Reinbold et al. 2010b)	<b>Animals:</b> Oxytetracycline 10 mg/kg BW daily for 5 days did not eliminate infection in experimental lambs (Stuen and Bergstrom 2001) <b>Humans:</b> Tetracycline (doxycycline hyclate 100 mg, oral/intravenous twice daily for 7 to 10 days) and rifampin (for pregnant and tetracycline allergic patients) (Bakken and Dumler 2006)
Prevention	Oxytetracycline, chlortetracycline in feed (Whittier et al. 2009)	<b>TBF:</b> Long-acting oxytetracycline (Woldehiwet 2007) <b>HGA:</b> Antibiotic prophylaxis is not effective (CDC 2013). No vaccine (CFSPH 2013)
Control	Establishment of <i>Anaplasma</i> free herds, buffer zone between housing, vector and fly control, hygienic veterinary instruments and needles, chemotherapy, chemosterilization and vaccination (Aubry and Geale 2011)	<b>TBF:</b> Use of acaricides (pyrethroids), improvement of host resistance, biological control of ticks (bacteria, nematodes predatory mites and entomopathogenic fungi, spiders, ants, beetles, rodents, birds and other organisms. Habitat modification, use of acaricides (Samish and Rehacek 1999; Chandler et al. 2000; Jonsson and Piper 2007), long-acting tetracycline (Woldehiwet 2007), cleaning vegetation, control of deer population (Gilbert 2010) <b>HGA:</b> Treatment, prevention of tick bite, protective clothing, tetracycline/doxycycline (CDC 2013)
Reservoirs	<b>Cattle:</b> white-tailed deer ( <i>Odocoileus virginianus</i> ; Keel et al. 1995) and ticks (Aubry and Geale 2011)	<b>USA:</b> white-tailed deer (Massung et al. 2005). <b>Europe:</b> roe deer (Overzier et al. 2013), red deer (Stuen et al. 2013b), fallow deer (Ebani et al. 2011), dusky-footed wood rats ( <i>Neotoma fuscipes</i> ) (Rikihisa 2003). <b>Asia:</b> Sika deer (Hapunik et al. 2011), Korean water deer (Kang et al. 2013) <b>Other:</b> white-footed mice ( <i>Peromyscus leucopus</i> ), Eastern chipmunk ( <i>Tamias striatus</i> ), Eastern gray squirrel ( <i>Sciurus carolinensis</i> ), Eastern red squirrel ( <i>Tamiasciurus hudsonicus</i> ), Southern flying squirrel ( <i>Glaucomys volans</i> ), Virginia opossum ( <i>Didelphis virginiana</i> ), Striped skunk ( <i>Mephitis mephitis</i> ), Northern short-tailed shrew ( <i>Blarina brevicauda</i> ), masked shrew ( <i>Sorex cinereus</i> ), raccoon ( <i>Procyon lotor</i> ) (Keesing et al. 2012)
Vectors	<b>India, South Africa, Brazil:</b> <i>Rhipicephalus (Boophilus) microplus</i> (Guglielmone 1995; Potgieter 1996; Ghosh et al. 2007) <b>Iraq:</b> <i>B. annulatus</i> (Ameen et al. 2012)	<b>Europe:</b> <i>Ixodes ricinus</i> (Woldehiwet 2010) <b>Latvia, Russia, Estonia:</b> <i>I. persulcatus</i> (Paulauskas et al. 2012; Rar et al. 2011) <b>USA: (Western USA):</b> <i>I. pacificus</i> (Rejmanek et al. 2011)

**Table 2** (continued)

Character	<i>A. marginale</i>	<i>A. phagocytophilum</i>
	<p><b>North America:</b> <i>Dermacentor andersoni</i> (three host tick), <i>D. variabilis</i> (three host tick), <i>D. albipictus</i> (one host tick) (Aubry and Geale 2011)</p> <p><b>USA:</b> <i>Dermacentor andersoni</i>, <i>Dermacentor variabilis</i>, <i>Argas persicus</i> (da Silva 2008)</p> <p><b>North Africa:</b> <i>Ixodes ricinus</i> (da Silva 2008). <b>Central and southern Africa:</b> <i>R. simus</i> (Merck Veterinary Manual 2014).</p> <p><b>South Africa:</b> <i>Rhipicephalus microplus</i>, <i>R. evertsi evertsi</i>, <i>R. simus</i>, <i>R. decoloratus</i>, and <i>Hyalomma marginatum rufipes</i> (de Waal 2000)</p> <p><b>Zambia:</b> <i>A. variegatum</i>, <i>B. decoloratus</i>, <i>R. evertsi</i> (Makala et al. 2003). <b>Europe:</b> <i>Ixodes ricinus</i> (da Silva, 2008). <b>Hungary:</b> <i>D. reticulatus</i> (Homok et al. 2012). <b>Australia:</b> <i>Rhipicephalus</i> (<i>Boophilus</i>) <i>microplus</i> (Bock et al. 2006)</p>	<p><b>USA: (Eastern USA):</b> <i>I. scapularis</i> (Roellig and Fang 2012)</p> <p><b>Russia:</b> <i>I. persulcatus</i> (Rar et al. 2011)</p> <p><b>China:</b> <i>I. persulcatus</i>, <i>Dermacentor silvarum</i> (Cao et al. 2006), <i>H. longicornis</i>, <i>H. concinna</i> (Jiang et al. 2011)</p> <p><b>Japan:</b> <i>I. persulcatus</i>, <i>Haemaphysalis megaspinoso</i>, <i>I. ovatus</i>, <i>H. douglasii</i> (Wuritu et al. 2009; Yoshimoto et al. 2010; Ybañez et al. 2012, 2013a, b)</p> <p><b>Korea:</b> <i>H. longicornis</i>, <i>I. nipponensis</i> (Chae et al. 2008)</p> <p><b>North Africa: (Algeria, Tunisia and Morocco):</b> <i>I. ricinus</i> and <i>Hyalomma marginatum</i>, <i>Hy. Detritum</i>, <i>I. spinipalpis</i> (Sarih et al. 2005; M'ghirbi et al. 2012)</p>

IFA indirect immunofluorescence assay

Concurrent infection with other tick-borne pathogens (*marginale* and/or *Borrelia burgdorferi*) in animals and tick vectors have been reported (Berger 2014; de la Fuente et al. 2005). Both pathogens have the ability to produce novel antigens in the presence of other strains (super-infection). Antigenic variants develop specific antibodies after each rickettsemic peak by *msp2/p44*. Re-infection is also the attribute of these organisms by their respective heterologous strains (Stuen et al. 2009; Futse et al. 2008; Vallejo Esquerra et al. 2014).

Molecular analysis of 16SrRNA gene of *A. marginale* and *A. phagocytophilum* showed that both the organisms transform major surface proteins variants during persistent infection in host and tick vectors. During each rickettsemic peak, *msp2* antigenic gene variants are formed that have specific host antibody responses. Extensive antigenic variations of *msp2* gene of outer surface membrane of *A. marginale* influenced by host immune system during persistence in host and tick vectors during developmental cycle. Antigenic variations and cross-protection are the challenges for vaccine development (Kocan et al. 2010b).

The P44 protein of *A. phagocytophilum* is homologous to *msp2* belong to multigene family of *A. marginale* evolved due to combinatorial gene conversion with the establishment of condensed pseudogenes (Brayton et al. 2002). These two organisms are similar on the basis of diverse antigenic surface proteins in their small genome and generate specific antibody response. There are six major surface antigenic proteins including *msp1α*, *msp1β*, *msp2*, *msp3*, *msp4*, and *msp5*, whereas *msp1α* and *msp1β* are distinctive in *A. marginale*.

A dominant antibody response is established against 40-kDa outer membrane protein (MSP2/P44) of *Anaplasma phagocytophilum*, same as expressed in *A. marginale*

infections (Ijdo et al. 1997). Expression of immunodominant antigenic major surface proteins (MSPs) share homology with *Anaplasma marginale* MSP2 and MSP4 (Lin et al. 2004; Vidotto et al. 2006). The MSP4 exhibits host-specific properties and involved in host-pathogen interaction, and because of this property, MSP4 bear selective pressure by the host immune system. Thus, a high degree of genetic heterogeneity is seen among *A. phagocytophilum* strains (Massung et al. 2003; de la Fuente et al. 2005). The *msp4* gene sequences may not give phylo-geographic information but can be used for *A. phagocytophilum* strain differentiation from humans, ruminants, and nonruminant domestic animals.

The *msp5* gene is conserve in all the Rickettsiales, this is highly stable among all *Anaplasma* species as well as isolates from the USA (Palmer et al. 2004). This is the cause of cross reactivity of *Anaplasma marginale* with *A. phagocytophilum* during indirect and competitive ELISA (Strik et al. 2007)

Detailed knowledge about epidemiology, ecology, vector biology and competence, risk factors and longitudinal studies for clinical manifestations, pathogenesis, and cellular and humoral responses of virulent pathogenic strains is lacking. Cell culture techniques (animal and tick) with targeted knockdown genes, transformation, multilocus sequence typing, blood meal genetic analyses, pulse field gel electrophoresis, high-throughput genome sequencing, and microbiomic and metagenomic analyses are currently available methodologies to explain population genetic structures and the evolutionary mechanism. Upcoming studies should therefore focus on the association between diverse genetic strains in different reservoir hosts and ticks by blood meal analysis and genetic fingerprinting to unstitch the biology, phylo-geographic distribution for better estimation of risk factors, and disease management.

## Conclusion

All age groups are susceptible to bovine anaplasmosis and tick-borne fever, but prevalence increases with age. Movement of susceptible domestic animals from tick-free non-endemic regions to disease endemic regions is the major risk factor. Recreational or high-risk tick exposure activities and blood transfusion is an important risk factor of human granulocytic anaplasmosis. Efforts are being focused for the identification of novel antigenic parts for a universal vaccine, effective against diverse geographic stains.

It is difficult to bridge the similarities and differences between two important tick-transmitted pathogens of family *Anaplasmataceae* (Table 2). *A. phagocytophilum* is relatively a new pathogen which got international research focus after the first human case in 1986. Both the organisms share a reasonable degree of commonality. The advances in epidemiological, molecular, and genetic engineering approaches in cell culture, vector ecology, clinical, experimental, immunological, and longitudinal studies may be utilized for both organisms being the member of family *Anaplasmataceae* keeping in view the differences in pathogenicity, host tropism, and strain diversity for ticks, humans, and domestic and wild animals. Moreover, the whole plasmid (4.5 kb) was successfully inserted in the chromosome of *Anaplasma marginale* by single homologous crossover (Felsheim et al. 2010). Similarly, this technique should be applied to transform *Anaplasma phagocytophilum* as earlier performed for *A. marginale* for better understanding the infection biology for effective prevention and control of this pathogen as well.

**Acknowledgments** I am grateful to Dr. Georg Gerhard Duscher from Institute of Parasitology, Department of Pathobiology, University of Veterinary Medicine, Vienna, Austria, for critical review and valuable comments for this review paper.

## References

- AABB (2009) American Association of Blood Banks. Up to date transfusion, 49: 169-71S. Available at <http://www.aabb.org/tm/eid/Documents/anaplasma-phagocytophilum.pdf>. Accessed 21 April 2015
- Aguero-Rosenfeld ME, Horowitz HW, Wormser GP, McKenna DF, Nowakowski J, Munoz J et al (1996) Human granulocytic ehrlichiosis: a case series from a medical center in New York State. *Ann Intern Med* 125:904–908
- Alberti A, Zobba R, Chessa B, Addis MF, Sparagano O, Pinna Parpagliam ML et al (2005) Equine and canine *Anaplasma phagocytophilum* strains isolated on the island of Sardinia (Italy) are phylogenetically related to pathogenic strains from the United States. *Appl Environ Microbiol* 71:6418–6422. doi:10.1128/AEM.71.10.6418-6422.2005
- Ameen KAH, Abdullah BA, Abdul Razaq RA (2012) Seroprevalence of *Babesia bigemina* and *Anaplasma marginale* in domestic animals in Erbil, Iraq. *Iraqi J Vet Sci* 26:109–114
- Andersson M, Raberg L (2011) Wild rodents and novel human pathogen *Candidatus Neoehrlichia mikurensis*, Southern Sweden. *Emerg Infect Dis* 17:17168
- Annen K, Friedman K, Eshoa C, Horowitz M, Gottschall J, Straus T (2012) Two cases of transfusion-transmitted *Anaplasma phagocytophilum*. *Am J Clin Pathol* 137:562–565
- Antunes S, Galindo RC, Almazan C, Rudenko N, Golovchenko M, Grubhoffer L et al (2012) Functional genomics studies of *Rhipicephalus (Boophilus) annulatus* ticks in response to infection with the cattle protozoan parasite, *Babesia bigemina*. *Int J Parasitol* 42:187–195. doi:10.1016/j.ijpara.2011.12.003
- Ashuma A, Sharma, Singla LD, Kaur P et al (2013) Prevalence and haemato-biochemical profile of *Anaplasma marginale* infection in dairy animals of Punjab (India). *Asian Pac J Trop Med* 6:139–144
- Atif FA, Khan MS, Iqbal HJ, Roheen T (2012a) Prevalence of tick-borne diseases in Punjab (Pakistan) and hematological profile of *Anaplasma marginale* infection in indigenous and crossbred cattle. *Pak J Sci* 64:11–15
- Atif FA, Khan MS, Khan MA, Ashraf M, Avais M (2012b) Chemotherapeutic efficacy of oxytetracycline, enrofloxacin and imidocarb for the elimination of persistent *Anaplasma marginale* infection in naturally infected Sahiwal cattle. *Pak J Zool* 44:449–456
- Atif FA, Khan MS, Muhammad F, Ahmad B (2013) Sero-epidemiological study of *Anaplasma marginale* among cattle. *J Anim Plant Sci* 23:740–744
- Aubry P, Geale DW (2011) A review of bovine anaplasmosis. *Transbound Emerg Dis* 58:1–30
- Bakken JS, Dumler JS (2006) Clinical diagnosis and treatment of human granulocytic anaplasmosis. *Ann NY Acad Sci* 1078:236–247
- Bakken JS, Dumler JS (2008) Human granulocytic anaplasmosis. *Infect Dis Clin N Am* 22:433–448. doi:10.1016/j.idc.2008.03.011
- Bakken JS, Dumler JS, Chen SM, Eckman MR et al (1994) Human granulocytic ehrlichiosis in the upper Midwest United States. A new species emerging? *JAMA-J Am Med Assoc* 272:212–218
- Bakken JS, Krueth J, Lund T, Malkovitch D et al (1996) Exposure to deer blood may be a cause of human granulocytic ehrlichiosis. *Clin Infect Dis* 23:198
- Baldridge GD, Scoles GA, Burkhardt NY, Schloeder B et al (2009) Transovarial transmission of Francisella-like endosymbionts and *Anaplasma phagocytophilum* variants in *Dermacentor albipictus* (Acari: Ixodidae). *J Med Entomol* 46:625–632
- Baráková I, Derdáková M, Carpi G, Rosso F, Collini M, Tagliapietra V, Ramponi C, Hauffe HC, Rizzoli A (2014) Genetic and ecologic variability among *Anaplasma phagocytophilum* strains, Northern Italy. *Emerg Infect Dis* 20:1082–1085
- Berger S (2014) Anaplasmosis: global Status. Gideon Informatics, Inc., Los Angeles, California, USA. [www.gideononline.com](http://www.gideononline.com). Accessed 21 April 2015
- Bilgiç HB, Karagenç T, Simuunza M, Shiels B, Tait A, Eren H, Weir W (2013) Development of a multiplex PCR assay for simultaneous detection of *Theileria annulata*, *Babesia bovis* and *Anaplasma marginale* in cattle. *Exp Parasitol* 133:222–9
- Billeter SA, Spencer JA, Griffin B, Dykstra CC et al (2007) Prevalence of *Anaplasma phagocytophilum* in domestic felines in the United States. *Vet Parasitol* 147:194–198
- Bock RE, de Vos AJ, Molloy JB (2006) Tick-borne diseases of Cattle. Australian and New Zealand standard diagnostic procedures. [www.scahls.org.au/Procedures/Documents/.../tick\\_borne\\_diseases.pdf](http://www.scahls.org.au/Procedures/Documents/.../tick_borne_diseases.pdf). Accessed 03 February 2015
- Borthakur SK, Deka DK, Bhattacharjee K, Sarmah PC (2014) Seroprevalence of canine dirofilariosis, granulocytic anaplasmosis and lyme borreliosis of public health importance in dogs from India's North East. *Vet World* 7:665–667
- Bown KJ, Lambin X, Ogden NH, Petrovec M, Shaw SE, Woldehiwet Z, Birtles RJ (2007) High-resolution genetic fingerprinting of European strains of *Anaplasma phagocytophilum* by use of

- multilocus variable-number tandem-repeat analysis. *J Clin Microbiol* 45:1771–1776
- Brandt J (2009) EAZWV transmissible disease fact sheet no. 68. Royal Zoological Society of Antwerp, Belgium. [http://eaza.portal.isis.org/activities/tdfactsheet/068%20Anaplasmosis%20\(Bovine\).doc.pdf](http://eaza.portal.isis.org/activities/tdfactsheet/068%20Anaplasmosis%20(Bovine).doc.pdf). Accessed on 25 January 2015
- Brayton KA, Palmer GH, Lundgren A, Yi J, Barbet AF (2002) Antigenic variation of *Anaplasma marginale* msp2 occurs by combinatorial gene conversion. *Mol Microbiol* 43:1151–1159
- Cao WC, Zhan L, He J, Foley JE, de Vlas SJ et al (2006) Natural *Anaplasma phagocytophilum* infection of ticks and rodents from a forest area of Jilin Province, China. *Am J Trop Med Hyg* 75:664–668
- Center for Food Security and Public Health, CFSPH (2013) Institute for International Cooperation in Animal Biologics, Ehrlichiosis and Anaplasmosis: zoonotic species Iowa state university, college of veterinary medicine. <http://www.cfsph.iastate.edu/Factsheets/pdfs/ehrlichiosis.pdf>. Accessed 27 December 2014
- Centers for Disease Control and Prevention (CDC) (2013) Statistics and epidemiology of anaplasmosis. <http://www.cdc.gov/anaplasmosis/>. Accessed 21 April 2015
- Chae JS, Yu DH, Shringi S, Klein TA et al (2008) Microbial pathogens in ticks, rodents and a shrew in northern Gyeonggi-do near the DMZ, Korea. *J Vet Sci* 9:285–293
- Chandler D, Davidson G, Pell JK, Ball BV, Shaw K (2000) Fungal bio-control of Acari. *Biocontrol Sci Tech* 10:357–384. doi:10.1080/09583150050114972
- Chávez AS, Felsheim RF, Kurtti TJ, Ku PS, Brayton KA, Munderloh UG (2012) Expression patterns of *Anaplasma marginale* Msp2 variants change in response to growth in cattle, and tick cells versus mammalian cells. *PLoS One* 7(4):e36012. doi:10.1371/journal.pone.0036012
- Chen SM, Dumler JS, Bakken JS, Walker DH (1994) Identification of a granulocytic *Ehrlichia* species as the etiologic agent of human disease. *J Clin Microbiol* 32:589–595
- Coetzee JF, Apley MD, Kocan KM (2006) Comparison of the efficacy of enrofloxacin, imidocarb, and oxytetracycline for clearance of persistent *Anaplasma marginale* infections in cattle. *Vet Ther* 7:347–360
- Courtney JW, Kostelnik LM, Zeidner NS, Massung RF (2004) Multiplex real-time PCR for detection of *Anaplasma phagocytophilum* and *Borrelia burgdorferi*. *J Clin Microbiol* 42:3164–3168. doi:10.1128/JCM.42.7.3164-3168.2004
- da Silva VNRB (2008) Surveillance of vector-borne diseases in cattle with special emphasis on bluetongue disease in Switzerland. Ph.D dissertation. Philosophisch-Naturwissenschaftlichen Fakultät der Universität Basel
- da Silva AS, Lopes LS, Diaz JD, Tonin AA et al (2013) Lice outbreak in buffaloes: evidence of *Anaplasma marginale* transmission by sucking lice *Haematopinus tuberculatus*. *J Parasitol* 99:546–547
- de la Fuente J, Almazán C, Van Den Bussche RA, Bowman J et al (2005) Characterization of genetic diversity in *Dermacentor andersoni* (Acari: Ixodidae) with body size and weight polymorphism. *Exp Parasitol* 10:16–26
- de la Fuente J, Almazán C, Blouin EF, Naranjo V, Kocan KM (2006) Reduction of tick infections with *Anaplasma marginale* and *A. phagocytophilum* by targeting the tick protective antigen subolesin. *Parasitol Res* 100:85–91
- de la Fuente J, Blouin EF, Manzano-Roman R, Naranjo V et al (2007) Functional genomic studies of tick cells in response to infection with the cattle pathogen, *Anaplasma marginale*. *Genomics* 90:712–722
- de la Fuente J, Moreno-Cid JA, Canales M, Villar M et al (2011) Targeting arthropod subolesin/akirin for the development of a universal vaccine for control of vector infestations and pathogen transmission. *Vet Parasitol* 181:17–22. doi:10.1016/j.vetpar.2011.04.018
- de la Fuente J, Moreno-Cid JA, Galindo RC, Almazán C et al (2013) Subolesin/Akirin vaccines for the control of arthropod vectors and vector borne pathogens. *Transbound Emerg Dis* 60(Suppl 2):172–178. doi:10.1111/tbed.12146
- de Waal DT (2000) Anaplasmosis control and diagnosis in South Africa. *Ann NY Acad Sci* 916:474–483
- Dhand A, Nadelman RB, Aguero-Rosenfeld M, Haddad FA, Stokes DP et al (2007) Human granulocytic anaplasmosis during pregnancy: case series and literature review. *Clin Infect Dis* 45:589–593
- Djiba ML, Mediannikov O, Mbengue M, Thiongane Y et al (2013) Survey of Anaplasmataceae bacteria in sheep from Senegal. *Trop Anim Health Prod* 45:1557–1561
- Draznovich NL, Brown RN, Foley JE (2006) Use of real-time quantitative PCR targeting the msp2 protein gene to identify cryptic *Anaplasma phagocytophilum* infections in wildlife and domestic animals. *Vector Borne Zoonotic Dis* 6:83–90
- Dumler JS (1996) Human ehrlichiosis: clinical, laboratory, epidemiologic, and pathologic considerations. In: Kazár J, Toman R (eds) *Rickettsiae and Rickettsial Diseases*. Veda, Bratislava, pp 287–302
- Dumler JS, Triggiani ER, Bakken JS, Aguero-Rosenfeld ME, Wormser GP (2000) Serum cytokine responses during acute human granulocytic ehrlichiosis. *Clin Diagn Lab Immunol* 7:6–8
- Dumler JS, Barbet AF, Bekker CP, Dasch GA et al (2001) Recognition of genera in the families *Rickettsiaceae* and *Anaplasmataceae* in order *Rickettsiales*: unification of some species of *Ehrlichia* with *Anaplasma*, *Cowdria* with *Ehrlichia* and *Ehrlichia* with *Neorickettsia* description of six new species combinations and designation of *Ehrlichia equi* and “HGE agent” as subjective synonyms of *Ehrlichia phagocytophila*. *Int J Syst Evol Microbiol* 51:2145–2165
- Ebani VV, Verin R, Fratini F, Poli A, Cerri D (2011) Molecular survey of *Anaplasma phagocytophilum* and *Ehrlichia canis* in red foxes (*Vulpes vulpes*) from central Italy. *J Wildl Dis* 47:699–703
- Felsheim RF, Chávez AS, Palmer GH, Crosby L, Barbet AF, Kurtti TJ, Munderloh UG (2010) Transformation of *Anaplasma marginale*. *Vet Parasitol* 167:167–174. doi:10.1016/j.vetpar.2009.09.018
- Foggie A (1951) Studies on the infectious agent of tick-borne fever in sheep. *J Pathol Bacteriol* 63:1–15
- Foley J, Nieto NC, Madigan J, Sykes J (2008) Possible differential host tropism in *Anaplasma phagocytophilum* strains in the Western United States. *Ann NY Acad Sci* 1149:94–97
- Fosgate GT, Urdaz-Rodríguez JH, Dunbar MD, Rae DO, Donovan GA, Melendez P, Dobek GL, Alleman AR (2010) Diagnostic accuracy of methods for detecting *Anaplasma marginale* infection in lactating dairy cattle of Puerto Rico. *J Vet Diagn Investig* 22:192–199
- Futse JE, Brayton KA, Dark MJ, Knowles DP, Palmer GH (2008) Super infection as a driver of genomic diversification in antigenically variant pathogens. *Proc Natl Acad Sci* 105:2123–2127
- Gaowa, Yoshikawa Y, Ohashi N, Wu D, Kawamori F, Ikegaya A, Watanabe T, Saitoh K, Takechi D, Murakami Y, Shichi D, Aso K, Ando S (2014) *Anaplasma phagocytophilum* antibodies in humans, Japan, 2010–2011. *Emerg Infect Dis* 20:508–509. doi:10.3201/eid2003.131337
- García-García JC, de la Fuente J, Blouin EF, Johnson TJ, Halbur T, Onet VC, Saliki JT, Kocan KM (2004) Differential expression of the msp1 alpha gene of *Anaplasma marginale* occurs in bovine erythrocytes and tick cells. *Vet Microbiol* 98:261–272
- Ghosh S, Azhahianambia P, Yadav MP (2007) Upcoming and future strategies of tick control: a review. *J Vector Borne Dis* 44:79–89
- Gilbert L (2010) Altitudinal patterns of tick and host abundance: a potential role for climate change in regulating tick-borne diseases? *Oecologia* 162:217–225
- Goethert HK, Telford SR 3rd (2003) Enzootic transmission of the agent of human granulocytic ehrlichiosis among cotton tail rabbits. *Am J Trop Med Hyg* 68:633–637
- Goodman JL, Nelson C, Vitale B, Madigan JE, Dumler JS, Kurtti TJ et al (1996) Direct cultivation of the causative agent of human



- granulocytic ehrlichiosis. *N Engl J Med* 334:209–215. doi:10.1056/NEJM199601253340401
- Gordon WS, Brownlee A, Wilson DR, MacLeod J (1932) “Tick-borne fever” (A hitherto undescribed disease of sheep). *J Comp Pathol Ther* 45:301–307. doi:10.1016/S0368-1742(32)80025-1
- Gorna M, Adaszek L, Policht K, Skrzypczak M, Winiarczyk S (2013) Detection of *Anaplasma phagocytophilum* in a cat. *Vet Med* 58:39–43
- Graf JF, Gogolewski R, Leach-Bing N, Sabatini GA et al (2004) Tick control: an industry point of view. *Parasitology* 129:S427–S442
- Granquist EG, Aleksandersen M, Bergstrom K, Dumler SJ et al (2010a) A morphological and molecular study of *Anaplasma phagocytophilum* transmission events at the time of *Ixodes ricinus* tick bite. *Acta Vet Scand* 52:43. doi:10.1186/1751-0147-52-4
- Granquist EG, Bardsen K, Bergstrom K, Stuen S (2010b) Variant -and individual dependent nature of persistent *Anaplasma phagocytophilum* infection. *Acta Vet Scand* 52:25. doi:10.1186/1751-0147-52-25
- Granquist EG, Stuen S, Crosby L, Lundgren AM et al (2010c) Variant-specific and diminishing immune responses towards the highly variable MSP2 (P44) outer membrane protein of *Anaplasma phagocytophilum* during persistent infection in lambs. *Vet Immunol Immunopathol* 133:117–124
- Grøva L, Olesen I, Steinshamn H, Stuen S (2011) Prevalence of *Anaplasma phagocytophilum* infection and effect on lamb growth. *Acta Vet Scand* 53:30
- Guglielmone AA (1995) Epidemiology of babesiosis and anaplasmosis in South and Central America. *Vet Parasitol* 57:109–119
- Hajdušek O, Šima R, Ayllón N, Jalovecká M et al (2013) Interaction of the tick immune system with transmitted pathogens. *Front Cell Infect Microbiol* 3:26. doi:10.3389/fcimb.2013.00026
- Hansen MG, Christoffersen M, Thuesen LR, Petersen MR, Bojesen AM (2010) Seroprevalence of *Borrelia burgdorferi* sensu lato and *Anaplasma phagocytophilum* in Danish horses. *Acta Vet Scand* 52:3. doi:10.1186/1751-0147-52-3
- Hapunik J, Vichova B, Karbowiak G, Wita I et al (2011) Wild and farm breeding cervids infections with *Anaplasma phagocytophilum*. *Ann Agric Environ Med* 18:73–77
- Hartelt K, Pluta S, Oehme R, Kimmig P (2008) Spread of ticks and tick-borne diseases in Germany due to global warming. *Parasitol Res* 103(Suppl 1):S109–S116. doi:10.1007/s00436-008-1059-4
- Henniger T, Henniger P, Grossmann T, Distl O, Ganter M et al (2013) Congenital infection with *Anaplasma phagocytophilum* in a calf in northern Germany. *Acta Vet Scand* 55:38. doi:10.1186/1751-0147-55-38
- Hing M, Woestyn S, Van Bosterhaut B, Desbonnet Y et al (2014) Diagnosis of human granulocytic anaplasmosis in Belgium by combining molecular and serological methods. *New Microbes New Infect* 2:177–178. doi:10.1002/nmi2.65
- Hodzic E, Fish D, Maretzki CM, de Silva AM et al (1998) Acquisition and transmission of the agent of human granulocytic ehrlichiosis by *Ixodes scapularis* ticks. *J Clin Microbiol* 36:3574–3578
- Hofmann-Lehmann R, Meli ML, Dreher UM, Gonczi E et al (2004) Concurrent infections with vector-borne pathogens associated with fatal hemolytic anemia in a cattle herd in Switzerland. *J Clin Microbiol* 42:3775–3780
- Holden K, Boothby JT, Anand S, Massung RF (2003) Detection of *Borrelia burgdorferi*, *Ehrlichia chaffeensis*, and *Anaplasma phagocytophilum* in ticks (Acari: Ixodidae) from a coastal region of California. *J Med Entomol* 40:534–539
- Hornok S, Elek V, de la Fuente J, Naranjo V et al (2007) First serological and molecular evidence on the endemicity of *Anaplasma ovis* and *A. marginale* in Hungary. *Vet Microbiol* 122:316–322
- Hornok S, Micsutka A, Fernández de Mera IG, Meli ML et al (2012) Fatal bovine anaplasmosis in a herd with new genotypes of *Anaplasma marginale*, *A. ovis* and concurrent haemoplasmosis. *Res Vet Sci* 92:30–35. doi:10.1016/j.rvsc.2010.10.011
- Horowitz HW, Kilchevsky E, Haber S, Aguero-Rosenfeldt M, Kranwinkel R, James EK et al (1998) Perinatal transmission of the agent of human granulocytic ehrlichiosis. *N Engl J Med* 339:375–378. doi:10.1056/NEJM199808063390604
- Howden KJ, Geale DW, Paré J, Golsteyn-Thomas EJ, Gajadhar AA (2010) An update on bovine anaplasmosis (*Anaplasma marginale*) in Canada. *Can Vet J* 51:837–840
- Huhn C, Winter C, Wolfsperger T, Wüppenhorst N et al (2014) Analysis of the population structure of *Anaplasma phagocytophilum* using multilocus sequence typing. *PLoS One* 9(4):e93725. doi:10.1371/journal.pone.0093725
- Hulínská D, Langšová K, Pejčoch M, Pavlásek I (2004) Detection of *Anaplasma phagocytophilum* in animals by real-time polymerase chain reaction. *APMIS* 112:239–247. doi:10.1111/j.1600-0463.2004.apm11204-0503.x
- Ijdo JW, Zhang Y, Hodzic E, Magnarelli LA et al (1997) The early humoral response in human granulocytic ehrlichiosis. *J Infect Dis* 176: 687–692
- Jahfari S, Fonville M, Hengeveld P, Reusken C et al (2012) Prevalence of *Neoehrlichia mikurensis* in ticks and rodents from North-west Europe. *Parasit Vector* 5:74. doi:10.1186/1756-3305-5-74
- Jahfari S, Coipan EC, Fonville M, van Leeuwen AD et al (2014) Circulation of four *Anaplasma phagocytophilum* ecotypes in Europe. *Parasit Vector* 7:365. doi:10.1186/1756-3305-7-365
- Jiang JF, Jiang BG, Yu JH, Zhang WY et al (2011) *Anaplasma phagocytophilum* infection in ticks, China-Russia border. *Emerg Infect Dis* 17:932–934
- Jongejan F, Uilenberg G (2004) The global importance of ticks. *Parasitology* 129(Suppl):S3–S14
- Jonsson NN, Piper EK (2007) Integrated control programs for ticks on cattle. *UQ Printery, Australia*, p 163
- Kang JG, Kim HC, Choi CY, Nam HY, Chae HY, Chong ST et al (2013) Molecular detection of *Anaplasma*, *Bartonella*, and *Borrelia* species in ticks collected from migratory birds from Hong-do Island, Republic of Korea. *Vector Borne Zoonotic Dis* 13:215–225. doi:10.1089/vbz.2012.1149
- Katavolos P, Armstrong PM, Dawson JE, Telford SR 3rd (1998) Duration of tick attachment required for transmission of granulocytic ehrlichiosis. *J Infect Dis* 177:1422–1425
- Kawahara M, Rikihisa Y, Lin Q, Isogai E et al (2006) Novel genetic variants of *Anaplasma phagocytophilum*, *Anaplasma bovis*, *Anaplasma centrale*, and a novel *Ehrlichia* sp. in wild deer and ticks on two major islands in Japan. *Appl Environ Microbiol* 72:1102–1109
- Keel MK, Goff WL, Davidson WR (1995) An assessment of the role of white-tailed deer in the epizootiology of anaplasmosis in the south-eastern United States. *J Wildl Dis* 31:378–385
- Keesing F, Hersh MH, Tibbetts M, McHenry DJ, Duerr S, Brunner J, Killilea M, LoGiudice K, Schmidt KA, Ostfeld RS (2012) Reservoir Competence of Vertebrate Hosts for *Anaplasma phagocytophilum*. *Emerg Infect Dis* 18:2013–2016. doi:10.3201/eid1812.120919
- Keysary A, Massung RF, Inbar M, Wallach AD et al (2007) Molecular evidence for *Anaplasma phagocytophilum* in Israel. *Emerg Infect Dis* 13:1411–1412
- Kocan KM, de la Fuente J, Guglielmone AA, Melendez RD (2003) Antigens and alternatives for control of *Anaplasma marginale* infection in cattle. *Clin Microbiol Rev* 16:698–712
- Kocan KM, de la Fuente J, Blouin EF, Garcia-Garcia JC (2004) *Anaplasma marginale* (Rickettsiales: Anaplasmataceae): recent advances in defining host-pathogen adaptations of a tick-borne rickettsia. *Parasitology* 129(Suppl):S285–S300
- Kocan KM, de la Fuente J, Blouin EF, Coetzee JF, Ewing SA (2010a) The natural history of *Anaplasma marginale*. *Vet Parasitol* 167:95–107. doi:10.1016/j.vetpar.2009.09.012

- Kocan KM, de la Fuente J, Step DL, Blouin EF et al (2010b) Current challenges of the management and epidemiology of bovine anaplasmosis. *Bovine Pract* 44:93–102
- Krakowetz CN, Dibernardo A, Lindsay LR, Chilton NB (2014). Two *Anaplasma phagocytophilum* strains in *Ixodes scapularis* ticks, Canada. [www.cdc.gov/eid/article/20/12/14-0172-techapp1.pdf](http://www.cdc.gov/eid/article/20/12/14-0172-techapp1.pdf). Accessed 21 April 2015
- Labuda M, Trimmell AR, Ličková M, Kazimírová M et al (2006) An antivector vaccine protects against a lethal vector-borne pathogen. *PLoS Pathog* 2(4):e27. doi:10.1371/journal.ppat.0020027
- Lane RS, Mun J, Peribáñez MA, Fedorova N (2010) Differences in prevalence of *Borrelia burgdorferi* and *Anaplasma* spp. infection among host-seeking *Dermacentor occidentalis*, *Ixodes pacificus*, and *Ornithodoros coriaceus* ticks in northwestern California. *Ticks Tick Borne Dis* 1:159–167. doi:10.1016/j.ttbdis.2010.09.004
- Leiby DA, Gill JE (2004) Transfusion-transmitted tick-borne infections: a cornucopia of threats. *Transfus Med Rev* 18:293–306
- Lepidi H, Bunnell JE, Martin ME, Madigan JE et al (2000) Comparative pathology, and immunohistology associated with clinical illness after *Ehrlichia phagocytophila*-group infections. *Am J Trop Med Hyg* 62:29–37
- Li H, Zhou Y, Wang W, Guo D et al (2011) The clinical characteristics and outcomes of patients with human granulocytic anaplasmosis in China. *Int J Infect Dis* 15:e859–e866. doi:10.1016/j.ijid.2011.09.008
- Lin Q, Rikihisa Y, Felek X, Wang S et al (2004) *Anaplasma phagocytophilum* has a functional *mosp2* gene that is distinct from p44. *Infect Immun* 72:3883–3889
- Lovrich SD, Jobe DA, Kowalski TJ, Policepatil SM, Callister SM (2011) Expansion of the midwestern focus for human granulocytic anaplasmosis into the region surrounding LaCrosse, Wisconsin. *J Clin Microbiol* 49:3855–3859. doi:10.1128/JCM.05025-11
- Madigan JE, Richter PJ Jr, Kinsey RB, Barlough JE, Bakken JS, Dumler JS (1995) Transmission and passage in horses of the agent of human granulocytic ehrlichiosis. *J Infect Dis* 172:1141–1144
- Maeda K, Markowitz N, Hawley RC et al (1987) Human infection with *Ehrlichia canis*, a leukocytic rickettsia. *N Engl J Med* 316:853–856
- Makala LH, Mangani P, Fujisaki K, Nagasawa H (2003) The current status of major tick borne diseases in Zambia. *Vet Res* 34:27–45
- Malmsten J, Widén DG, Rydevik G, Yon L et al (2014) Temporal and spatial variation in *Anaplasma phagocytophilum* infection in Swedish moose (*Alces alces*). *Epidemiol Infect* 142:1205–1213. doi:10.1017/S0950268813002094
- Massung RF, Slater K, Owens JH, Nicholson WL et al. (1998) Nested PCR assay for detection of granulocytic ehrlichiae. *J Clin Microbiol* 1090–1095
- Massung RF, Owens JH, Ross D, Reed KD et al (2000) Sequence analysis of the ank gene of granulocytic ehrlichiae. *J Clin Microbiol* 38:2917–2922
- Massung RF, Priestley RA, Miller NJ, Mather TN et al (2003) Inability of a variant strain of *Anaplasma phagocytophilum* to infect mice. *J Infect Dis* 188:1757–1763
- Massung RF, Courtney JW, Hiratzka SL, Pitzer VE et al (2005) *Anaplasma phagocytophilum* in white-tailed deer. *Emerg Infect Dis* 11:1604–1606
- Massung RF, Mather TN, Levin ML (2006) Reservoir competency of goats for the Ap-variant 1 strain of *Anaplasma phagocytophilum*. *Infect Immun* 74:1373–1375
- Masuzawa T, Kharitononkov IG, Okamoto Y, Fukui T, Ohashi N (2008) Prevalence of *Anaplasma phagocytophilum* and its coinfection with *Borrelia afzelii* in *Ixodes ricinus* and *Ixodes persulcatus* ticks in habiting Tver Province (Russia) - asympatric region for both tick species. *J Med Microbiol* 57:986–991. doi:10.1099/jmm.0.47721-0
- May K, Strube C (2014) Prevalence of Rickettsiales (*Anaplasma phagocytophilum* and *Rickettsia* spp.) in hard ticks (*Ixodes ricinus*) in the city of Hamburg, Germany. *Parasitol Res* 113:2169–2175. doi:10.1007/s00436-014-3869-x
- Merino O, Antunes S, Mosqueda J, Moreno-Cid JA et al (2013) Vaccination with proteins involved in tick-pathogen interactions reduces vector infestations and pathogen infection. *Vaccine* 31:5889–5896. doi:10.1016/j.vaccine.2013.09.037
- M'ghirbi Y, Yaïch H, Ghorbel A, Bouattour A (2012) *Anaplasma phagocytophilum* in horses and ticks in Tunisia. *Parasit Vector* 5:180. doi:10.1186/1756-3305-5-180
- Michalik J, Stańczak J, Cieniuch S, Racewicz M et al (2012) Wild boars as hosts of human-pathogenic *Anaplasma Phagocytophilum* variants. *Emerg Infect Dis* 18:209–1001. doi:10.3201/eid1806.110997
- Morissette E, Massung RF, Foley JE, Alleman AR et al (2009) Diversity of *Anaplasma phagocytophilum* Strains, USA. *Emerg Infect Dis* 15:928–931
- Munderloh UG, Jauron SD, Fingerle V, Leitritz L et al (1999) Invasion and intracellular development of the human granulocytic ehrlichiosis agent in tick cell culture. *J Clin Microbiol* 37:2518–2524
- Munderloh UG, Lynch MJ, Herron MJ, Palmer AT, Kurtti TJ, Nelson RD et al (2004) Infection of endothelial cells with *Anaplasma marginale* and *A. phagocytophilum*. *Vet Microbiol* 101:53–64. doi:10.1016/j.vetmic.2004.02.011
- Ogden NH, Bown K, Horrocks BK, Woldehiwet Z, Bennett M (1998) Granulocytic Ehrlichia infection in ixodid ticks and mammals in woodlands and uplands of the U.K. *Med Vet Entomol* 12:423–429
- Ogden NH, Casey ANJ, French NP, Bown KJ et al (2002) Natural *Ehrlichia phagocytophila* transmission coefficients from sheep 'carriers' to *Ixodes ricinus* ticks vary with the numbers of feeding ticks. *Parasitology* 124:127–136
- OIE (2012) World Organization for Animal Health. OIE terrestrial manual, Section 2.4. Bovinae, In: Chapter 2.4.1. Bovine anaplasmosis; Paris, France, pp 589–600
- Øverås J, Lund A, Ulvund MJ, Waldeland H (1993) Tick-borne fever as a possible predisposing factor in septicemic pasteurellosis in lambs. *Vet Rec* 133:398
- Overzier E, Pfister K, Herb I, Mahling M et al (2013) Detection of tick-borne pathogens in roe deer (*Capreolus capreolus*), questing ticks (*Ixodes ricinus*) and ticks infesting roe deer in southern Germany. *Ticks Tick Borne Dis* 4:320–328. doi:10.1016/j.ttbdis.2013.01.004
- Palmer GH, Knowles DP, Rodríguez JL, Gnad DP et al (2004) Stochastic transmission of multiple genotypically distinct *Anaplasma marginale* strain in a herd with high prevalence of *Anaplasma* infection. *J Clin Microbiol* 42:5381–5384
- Pantchev N, Pluta S, Huisinga E, Nather S, Scheufelen M, Vrhovec MG, Schweinitz A, Hampel H, Straubinger RK (2015) Tick-borne diseases (Borreliosis, Anaplasmosis, Babesiosis) in German and Austrian dogs: Status quo and review of distribution, transmission, clinical findings, diagnostics and prophylaxis. *Parasitol Res* 114(Suppl 1):19–54. doi:10.1007/s00436-015-4513-0
- Park J, Choi KS, Dumler JS (2003) Major surface protein 2 of *Anaplasma phagocytophilum* facilitates adherence to granulocytes. *Infect Immun* 71:4018–4025. doi:10.1128/IAI.71.7.4018-4025.2003
- Paulauskas A, Radzijeuskaja J, Rosef O (2012) Molecular detection and characterization of *Anaplasma phagocytophilum* strains. *Comp Immunol Microbiol Infect Dis* 35:187–195. doi:10.1016/j.cimid.2012.01.001
- Popov VL, Han VC, Chen SM, Dumler JS et al (1998) Ultrastructural differentiation of the genogroups in the genus *Ehrlichia*. *J Med Microbiol* 47:235–251
- Potgieter FT (1996) Epidemiology of ticks and tick-borne diseases in eastern, central and southern Africa. In: Epidemiology of ticks and tick-borne diseases in South Africa: future research needs and priorities. Proceedings of a workshop held in Harare, 12–13 March, 1996. [http://www.ilri.org/infoserv/Webpub/fulldocs/Google\\_Inputs/9291460168.pdf](http://www.ilri.org/infoserv/Webpub/fulldocs/Google_Inputs/9291460168.pdf). Accessed 22 April 2015

- Proctor MC, Leiby DA (2015) Do leukoreduction filters passively reduce the transmission risk of human granulocytic anaplasmosis? *Transfusion* 55:1242–8. doi:10.1111/trf.12976
- Pusterla N, Braun U (1997) Clinical findings in cows after experimental infection with *Ehrlichia phagocytophila*. *Zentralbl Veterinarmed A* 44:385–390
- Pusterla N, Lutz H, Braun U (1998) Experimental infection of four horses with *Ehrlichia phagocytophila*. *Vet Rec* 143:303–305
- Ramakrishnan VG, Aljamali MN, Sauer JR, Essenberg RC (2005) Application of RNA interference in tick salivary gland research. *J Biomol Tech* 16:297–305
- Rar VA, Epikhina TI, Livanova NN, Panov VV et al (2011) Genetic variability of *Anaplasma phagocytophilum* in *Ixodes persulcatus* ticks and small mammals in the Asian part of Russia. *Vector Borne Zoonotic Dis* 11:1013–1021. doi:10.1089/vbz.2010.0266
- Razzaq F, Khosa T, Ahmad S, Hussain M et al (2015) Prevalence of *Anaplasma phagocytophilum* in horses from Southern Punjab (Pakistan). *Trop Biomed* 32:233–239
- Reinbold JB, Coetzee JF, Sirigreddy KR, Ganta RR (2010a) Detection of *Anaplasma marginale* and *Anaplasma phagocytophilum* in bovine peripheral blood samples by duplex real-time reverse transcriptase-polymerase chain reaction assay. *J Clin Microbiol* 48:2424–2432. doi:10.1128/JCM.02405-09
- Reinbold JB, Coetzee JF, Hollis LC, Nickell JS et al (2010b) The efficacy of three chlortetracycline regimens in the treatment of persistent *Anaplasma marginale* infection. *Vet Microbiol* 145:69–75
- Rejmanek D, Nieto NC, Barash N, Foley JE (2011) Temporal patterns of tick-borne granulocytic anaplasmosis in California. *Ticks Tick Borne Dis* 2:81–87. doi:10.1016/j.ttbdis.2010.12.003
- Reppert E, Galindo RC, Breshears MA, Kocan KM et al (2013) Demonstration of transplacental transmission of a human isolate of *Anaplasma phagocytophilum* in an experimentally infected sheep. *Transbound Emerg Dis* 60:93–96. doi:10.1111/tbed.12120
- Richey EJ (1991) Bovine anaplasmosis. Proceedings of the 24th Annual Conference of the American Association of Bovine Practitioners, Orlando, FL, pp 3–11
- Richey EJ, Palmer GH (1990) Bovine anaplasmosis. *Compend Contin Educ Pract Vet* 12:1661–1668
- Rikihisa Y (2003) Mechanisms to create a safe haven by members of the family Anaplasmataceae. *Ann NY Acad Sci* 990:548–555
- Rikihisa Y (2011) Mechanisms of obligatory intracellular infection with *Anaplasma phagocytophilum*. *Clin Microbiol Rev* 24:469–489
- Rikihisa Y, Zhi N, Wormser GP, Wen B et al (1997) Ultrastructural and antigenic characterization of a granulocytic ehrlichiosis agent directly isolated and stably cultivated from a patient in New York State. *J Infect Dis* 175:210–213
- Rizzoli A, Silaghi C, Obiegala A, Rudolf I et al (2014) *Ixodes ricinus* and its transmitted pathogens in urban and peri-urban areas in Europe: new hazards and relevance for public health. *Front Public Health* 2:251. doi:10.3389/fpubh.2014.00251
- Roellig DM, Fang QQ (2012) Detection of *Anaplasma phagocytophilum* in ixodid ticks from equine-inhabited sites in the Southeastern United States. *Vector Borne Zoonotic Dis* 12:330–332. doi:10.1089/vbz.2011.0757
- Salabarría FF, Pino R (1988) Vertical transmission of *Anaplasma marginale* in cows affected in late pregnancy. *Rev Cuba Cienc Vet* 19:179–182
- Samish M, Rehacek J (1999) Pathogens and predators of ticks and their potential in biological control. *Annu Rev Entomol* 44:159–182
- Samish M, Pipano E, Hadani A (1993) Intrastadial and interstadial transmission of *Anaplasma marginale* by *Boophilus annulatus* ticks in cattle. *Am J Vet Res* 54:411–414
- Santos AS, Santos-Silva MM, Almeida VC, Bacellar F, Dumler JS (2004) Detection of *Anaplasma phagocytophilum* DNA in *Ixodes* ticks (Acari: Ixodidae) from Madeira island and Setubal district, mainland Portugal. *Emerg Infect Dis* 10:1643–1648
- Sarih M, M'ghirbi Y, Bouattour A, Gern L et al (2005) Detection and identification of Ehrlichia spp. in ticks collected in Tunisia and Morocco. *J Clin Microbiol* 43:1127–1132
- Scharf W, Schauer S, Freyburger F, Petrovec M, Schaarschmidt-Kiener D, Liebisch G et al (2011) Distinct host species correlate with *Anaplasma phagocytophilum* ankA gene clusters. *J Clin Microbiol* 49:790–796. doi:10.1128/JCM.02051-10
- Seidman D, Hebert KS, Truchan HK, Miller DP, Tegels BK, Marconi RT, Carlyon JA (2015) Essential domains of *Anaplasma phagocytophilum* invasins utilized to infect mammalian host cells. *PLoS Pathog* 11:e1004669. doi:10.1371/journal.ppat.1004669
- Silaghi C, Hamel D, Thiel C, Pfister K et al (2011a) Genetic variants of *Anaplasma phagocytophilum* in wild caprine and cervid ungulates from the Alps in Tyrol, Austria. *Vector Borne Zoonotic Dis* 11:355–362. doi:10.1089/vbz.2010.0051
- Silaghi C, Liebisch G, Pfister K (2011b) Genetic variants of *Anaplasma phagocytophilum* from 14 equine granulocytic anaplasmosis cases. *Parasit Vector* 4:161. doi:10.1186/1756-3305-4-161
- Silaghi C, Pfister K, Overzier E (2014) Molecular investigation for bacterial and protozoan tick-borne pathogens in wild boars (*Sus scrofa*) from southern Germany. *Vector Borne Zoonotic Dis* 14:371–373. doi:10.1089/vbz.2013.1495
- Skoracki M, Michalik J, Skotarczak B, Rymaszewska A, Sikora B, Hofman T, Wodecka B, Sawczuk M (2006) First detection of *Anaplasma phagocytophilum* in quill mites (Acari: Syringophilidae) parasitizing passerine birds. *Microbes Infect* 8:303–307
- Stamard AA, Gribble DH, Smith RS (1969) Equine ehrlichiosis: a disease with similarities to tick-borne fever and bovine petechial fever. *Vet Rec* 84:149–150. doi:10.1136/vr.84.6.149
- Stiller D, Leatch G, Kuttler KL (1981) *Dermacentor albipictus* (Packard): an experimental vector of bovine anaplasmosis. Proceedings of the 85th Annual Meeting of the United States Animal Health Association (USAHA), St. Louis, MO, USA, pp 65–73
- Stiller D, Johnson LW, Kuttler KL (1983) Experimental transmission of *Anaplasma marginale* Theiler by males of *Dermacentor albipictus* (Packard) and *Dermacentor occidentalis* Marx (Acari: Ixodidae). Proceedings of the 87th Annual meeting of the United States Animal Health Association (USAHA), Roanoke, VA, USA, pp 59–65
- Strik NI, Alleman AR, Barbet AF, Sorenson HL et al (2007) Characterization of *Anaplasma phagocytophilum* major surface protein 5 and the extent of its cross-reactivity with *A. marginale*. *Clin Vaccine Immunol* 14:262–268
- Stuen S (2003) *Anaplasma phagocytophilum* (formerly *Ehrlichia phagocytophila*) infection in sheep and wild ruminants in Norway. A study on clinical manifestation, distribution and persistence. Thesis, Dr. Philosophiae, Norwegian School of Veterinary Science, Oslo, Norway
- Stuen S (2007) *Anaplasma phagocytophilum* - the most widespread tick-borne infection in animals in Europe. *Vet Res Commun* 31:79–84
- Stuen S, Bergstrom K (2001) The effect of two different oxytetracycline treatments in experimental *Ehrlichia phagocytophila* infected lambs. *Acta Vet Scand* 42:339–346
- Stuen S, Hardeng F, Larsen HJ (1992) Resistance to tick-borne fever in young lambs. *Res Vet Sci* 52:211–216
- Stuen S, Oppegaard AS, Bergström K, Moum T (2005) *Anaplasma phagocytophilum* infection in North Norway. The first laboratory confirmed case. *Acta Vet Scand* 46:167–171. doi:10.1186/1751-0147-46-167
- Stuen S, Torsteinbo WO, Bergstrom K, Bardsen K (2009) Superinfection occurs in *Anaplasma phagocytophilum* infected sheep irrespective of infection phase and protection status. *Acta Vet Scand* 51:41. doi:10.1186/1751-0147-51-41



- Stuen S, Scharf W, Schauer S, Freyburger F, Bergstrom K, von Loewenich FD (2010) Experimental infection in lambs with a red deer (*Cervus elaphus*) isolate of *Anaplasma phagocytophilum*. *J Wildl Dis* 46:803–809
- Stuen S, Grøva L, Granquist E, Sandstedt K et al (2011) A comparative study of clinical manifestations, haematological and serological responses after experimental infection with *Anaplasma phagocytophilum* in two Norwegian sheep breeds. *Acta Vet Scand* 53:8
- Stuen S, Granquist EG, Silaghi C (2013a) *Anaplasma phagocytophilum*—a widespread multi-host pathogen with highly adaptive strategies. *Front Cell Infect Microbiol* 3:1–33. doi:10.3389/fcimb.2013.00031
- Stuen S, Pettersen KS, Granquist EG, Bergström K et al (2013b) *Anaplasma phagocytophilum* variants in sympatric red deer (*Cervus elaphus*) and sheep in southern Norway. *Ticks Tick Borne Dis* 4:197–201. doi:10.1016/j.ttbdis.2012.11.014
- Sukumaran B, Narasimhan S, Anderson JF, Deponte K, Marcantonio N, Krishnan MN et al (2006) An *Ixodes scapularis* protein required for survival of *Anaplasma phagocytophilum* in tick salivary glands. *J Exp Med* 203:1507–1517. doi:10.1084/jem.20060208
- Tate CM, Mead DG, Luttrell MP, Howarth EW et al (2005) Experimental infection of white-tailed deer with *Anaplasma phagocytophilum*, etiologic agent of human granulocytic anaplasmosis. *J Clin Microbiol* 43:3595–3601
- Taylor SM, Kenny J (1980) The effects of tick-borne fever (*Ehrlichia phagocytophila*) on the growth rate of fattening cattle. *Br Vet J* 136:364–370
- Telford SR 3rd, Dawson JE, Kaltavolos P, Warner CK, Kolbert CP, Persing DH (1996) Perpetuation of the agent of human granulocytic ehrlichiosis in a deer tick-rodent cycle. *Proc Natl Acad Sci U S A* 93:6209–6214. doi:10.1073/pnas.93.12.6209
- The Merck Veterinary Manual (2014) <http://www.merckvetmanual.com/mvm/index.jsp>. Accessed 25 January 2015
- Tinkler SH, Firshman AM, Sharkey LC (2012) Premature parturition, edema, and ascites in an alpaca infected with *Anaplasma phagocytophilum*. *Can Vet J* 53:1199–1202
- Tomanovic S, Chochlakis D, Radulovic Z, Milutinovic M et al (2013) Analysis of pathogen co-occurrence in host-seeking adult hard ticks from Serbia. *Exp Appl Acarol* 59:367–376. doi:10.1007/s10493-012-9597-y
- Torina A, Moreno-Cid JA, Blanda V, Fernández de Mera IG et al (2014) Control of tick infestations and pathogen prevalence in cattle and sheep farms vaccinated with the recombinant Subolesin-Major Surface Protein 1a chimeric antigen. *Parasit Vector* 7:10. doi:10.1186/1756-3305-7-10
- Townsend RL, Moritz ED, Fialkow LB, Berardi V, Stramer SL (2014) Probable transfusion-transmission of *Anaplasma phagocytophilum* by leukoreduced platelets. *Transfusion* 54:2828–2832. doi:10.1111/trf.12675
- Tuomi J (1967) Experimental studies on bovine tick-borne fever. 1. Clinical and haematological data, some properties of the causative agent, and homologous immunity. *Acta Pathol Microbiol Scand* 70:429–445
- Vallejo Esquerria E, Herndon DR, Alpirez Mendoza F, Mosqueda J, Palmer GH (2014) *Anaplasma marginale* superinfection attributable to pathogen strains with distinct genomic backgrounds. *Infect Immun* 82:5286–5292. doi:10.1128/IAI.02537-14
- Vichová B, Majláthová V, Nováková M, Straka M, Pet'ko B (2010) First molecular detection of *Anaplasma phagocytophilum* in European brown bear (*Ursus arctos*). *Vector Borne Zoonotic Dis* 10:543–545. doi:10.1089/vbz.2009.0103
- Vichová B, Majláthová V, Nováková M, Majláth I, Čurlík J, Bona M, Komjáti-Nagyová M, Pet'ko B (2011) PCR detection of re-emerging tick-borne pathogen, *Anaplasma phagocytophilum*, in deer ked (*Lipoptena cervi*) a blood-sucking ectoparasite of cervids. *Biologia* 66:1082–1086
- Vidotto MC, Kano SF, Gregori F, Headley SA, Vidotto O (2006) Phylogenetic analysis of *Anaplasma marginale* strains from Paraná state, Brazil, using the msp1 $\alpha$  and msp4 genes. *J Veterinary Med Ser B* 53:404–411. doi:10.1111/j.1439-0450.2006.00984.x
- Von Loewenich FD, Baumgarten BU, Schröppel K, Geissdörfer W et al (2003) High diversity of ankA sequences of *Anaplasma phagocytophilum* among *Ixodes ricinus* ticks in Germany. *J Clin Microbiol* 41:5033–5040. doi:10.1128/JCM.41.11.5033-5040.2003
- Walker AR, Bouattour A, Camicas JL, Estrada-Pena A et al. (2003) Ticks of domestic animals in Africa: a guide to identification of species, bioscience reports. Edinburgh, UK. pp 210
- Whittier D, Currin N, Currin JF (2009) Anaplasmosis in beef cattle. [https://pubs.ext.vt.edu/400/400-465/400-465\\_pdf.pdf](https://pubs.ext.vt.edu/400/400-465/400-465_pdf.pdf). Accessed 18 January 2015
- Willadsen P (2006) Tick control: thoughts on a research agenda. *Vet Parasitol* 138:161–168. doi:10.1016/j.vetpar.2006.01.050
- Woldehiwet Z (2006) *Anaplasma phagocytophilum* in ruminants in Europe. *Ann NY Acad Sci* 1078:446–460
- Woldehiwet Z (2007) Tick-borne diseases. In: Aitken ID (ed) *Diseases of sheep*, 4th edn. Blackwell, Oxford, pp 347–355
- Woldehiwet Z (2010) The natural history of *Anaplasma phagocytophilum*. *Vet Parasitol* 167:108–122. doi:10.1016/j.vetpar.2009.09.013
- Woldehiwet Z, Scott GR (1982) Stages in the development of *Cytoecetes phagocytophila*, the causative agent of tick-borne fever. *J Comp Pathol* 92:469–474
- Woldehiwet Z, Scott GR (1993) Tick-borne (pasture) fever. In: Woldehiwet Z, Ristic M (eds) *Rickettsial and chlamydial diseases of domestic animals*. Pergamon Press, Oxford, pp 233–254
- Woldehiwet Z, Horrocks BK, Scaife H, Ross G et al (2002) Cultivation of an ovine strain of *Ehrlichia phagocytophila* in tick cell cultures. *J Comp Pathol* 127:142–149
- Wormser GP, Dattwyler RJ, Shapiro ED, Halperin JJ, Steere AC, Klempner MS, Krause PJ, Bakken JS, Strle F, Stanek G, Bockenstedt L, Fish D, Dumler JS, Nadelman RB (2006) The clinical assessment, treatment, and prevention of Lyme disease, human granulocytic anaplasmosis, and babesiosis: clinical practice guidelines by the Infectious Diseases Society of America. *Clin Infect Dis* 43:1089–1134
- Wuritu, Ozawa Y, Gaowa, Kawamori F et al (2009) Structural analysis of a *p44/msp2* expression site of *Anaplasma phagocytophilum* in naturally infected ticks in Japan. *J Med Microbiol* 58:1638–1644. doi:10.1099/jmm.0.011775-0
- Ybañez AP, Matsumoto K, Kishimoto T, Yokoyama N, Inokuma H (2012) Dual presence of *Anaplasma phagocytophilum* and its closely related *Anaplasma* sp. in *Ixodid* ticks in Hokkaido, Japan, and their specific molecular detection. *J Vet Med Sci* 74:551–1560
- Ybañez AP, Sivakumar T, Ybañez RH, Ratilla JC et al (2013a) First molecular characterization of *Anaplasma marginale* in cattle and *Rhipicephalus (Boophilus) microplus* ticks in Cebu, Philippines. *J Vet Med Sci* 75:27–36
- Ybañez AP, Sivakumar T, Ybañez RH, Vincoy MR et al (2013b) Molecular survey of bovine vector-borne pathogens in Cebu, Philippines. *Vet Parasitol* 196:13–20. doi:10.1016/j.vetpar.2013.02.01
- Yoshimoto K, Matsuyama Y, Matsuda H, Sakamoto L et al (2010) Detection of *Anaplasma bovis* and *Anaplasma phagocytophilum* DNA from *Haemaphysalis megaspinosus* in Hokkaido, Japan. *Vet Parasitol* 168:170–172. doi:10.1016/j.vetpar.2009.10.008
- Zaugg JL, Stiller D, Coan ME, Lincoln SD (1986) Transmission of *Anaplasma marginale* Theiler by males of *Dermacentor andersoni* Stiles fed on an Idaho field-infected, chronic carrier cow. *Am J Vet Res* 47:2269–2271



- Zeidner NS, Burkot TR, Massung R, Nicholson WL et al (2000) Transmission of the agent of human granulocytic ehrlichiosis by *Ixodes spinipalpis* ticks: evidence of an enzootic cycle of dual infection with *Borrelia burgdorferi* in Northern Colorado. *J Infect Dis* 182:616–619
- Zeidner NS, Massung RF, Dolan MC, Dadey E et al (2008) A sustained-release formulation of doxycycline hyclate (Atridox) prevents simultaneous infection of *Anaplasma phagocytophilum* and *Borrelia burgdorferi* transmitted by tick bite. *J Med Microbiol* 57:463–468. doi:10.1099/jmm.0.47535-0
- Zeman P, Pecha M (2008) Segregation of genetic variants of *Anaplasma phagocytophilum* circulating among wild ruminants within a Bohemian forest (Czech Republic). *Int J Med Microbiol* 298:203–210. doi:10.1016/j.ijmm.2008.03.003
- Zhang L, Liu Y, Ni D, Li Q et al (2008) Nosocomial transmission of human granulocytic anaplasmosis in China. *JAMA, J Am Med Assoc* 300:2263–2270
- Zhang L, Wang Y, Cai D, He G, Cheng Z, Liu J, Meng K, Yang D, Wang S (2013) Detection of anaplasma marginale in Hyalomma asiaticum ticks by PCR assay. *Parasitol Res* 112:2697–702. doi:10.1007/s00436-013-3437-9
- Zhang L, Liu H, Xu B, Zhang Z et al (2014) Rural residents in China are at increased risk of exposure to tick-borne pathogens *Anaplasma phagocytophilum* and *Ehrlichia chaffeensis*. *Biomed Res Int* 2014: 313867. doi:10.1155/2014/313867
- Zhi N, Ohashi N, Tajima T, Mott J, Stich RW, Grover D et al (2002) Transcript heterogeneity of p44 multigene family in human granulocytic ehrlichiosis agent transmitted by ticks. *Infect Immun* 70: 1175–1184
- Zivkovic Z, Blouin EF, Manzano-Roman R, Almazán C (2009) *Anaplasma phagocytophilum* and *Anaplasma marginale* elicit different gene expression responses in cultured tick cells. *Comp Funct Genomics* 15:705034. doi:10.1155/2009/705034
- Zivkovic Z, Esteves E, Almazán C, Daffre S et al (2010) Differential expression of genes in salivary glands of male *Rhipicephalus (Boophilus) microplus* in response to infection with *Anaplasma marginale*. *BMC Genomics* 11:186. doi:10.1186/1471-2164-11-186