




The impact of case complexity in resident-performed cataract surgery

Sally SE Park¹ · Michael Tseng¹ · Zara Mian¹ · Jee-Young Moon² · Anurag Shrivastava^{1,3} 

Received: 13 May 2022 / Revised: 16 February 2023 / Accepted: 25 February 2023 / Published online: 16 March 2023
© The Author(s), under exclusive licence to Springer-Verlag GmbH Germany, part of Springer Nature 2023

Abstract

Purpose To evaluate the association of capsular dye and/or a pupil expansion device (PED) usage on the rate of major complication in resident-performed cataract extraction.

Methods Resident cataract surgeries between 2016 and 2019 were included. The primary outcomes were anterior or posterior vitrectomy (AVx and PPVx). Cases were grouped by the use of a PED and/or capsular staining along with additional preoperative risk factors.

Results Of the 1,348 cases, 371 (27.5%) documented capsular staining (“Dye-only”), 91 (6.8%) required pupil expansion (“PED-only”), and 100 (7.4%) used both capsular stain and a PED (“Both”). The remainder of cases ($n=786$, 58.3%) were classified as “Routine.” Compared to the “Routine” group, “PED-only” and “Both” had significantly higher odds of an AVx (OR=2.90, 95% CI 1.27–6.19, $P=0.01$) and/or a PPVx (OR=2.33, 95% CI 1.07–5.12, $P=0.04$). Among the PPVx cases, the “PED-only” group has significantly higher odds than “Routine” and “Dye-only” (OR=4.64, 95% CI 1.68–12.79, $P=0.01$; and OR=6.48, 95% CI 1.7–25.0, $P=0.005$, respectively). In case-control analysis, vision, intraocular pressure, anterior chamber depth, axial length, cataract type, or severity had no significant overall association with complication. When compared to nuclear sclerotic cataract, posterior subcapsular (OR=7.86, 95% CI 1.46–42.47, $P=0.017$) and white/mature cataracts (OR=3.05, 95% CI 1.1–8.43, $P=0.032$) had increased odds of complication.

Conclusion Resident-performed cataract surgery frequently required capsular staining and/or a PED, and intuitively, these cases had a higher *overall* complication rate compared to routine cases. However, the use of a PED independently was associated with significantly higher odds of a major complication requiring an unplanned vitrectomy independent of predisposing factors.

Key messages

What is known

- Pupil expansion devices (PEDs) are commonly used to assist in cases with poor anatomic visualization to minimize complications.

What is New

- In resident-performed cataract surgeries, cases requiring PEDs were found to be associated with higher odds of complications requiring vitrectomy.
- Compared to nuclear sclerotic cataracts, posterior subcapsular and white/mature cataracts had higher odds of a surgical complication requiring a vitrectomy.
- This study provides further evidence of the necessity of increased vigilance when operating on eyes with complex anatomy in a training environment.

This study is presented at the 2021 ASCRS Annual Meeting, Las Vegas, NV (July 23–27, 2021).

✉ Anurag Shrivastava
ashrivas@montefiore.org

Extended author information available on the last page of the article

Keywords Resident · Cataract · Phacoemulsification · Intraoperative complications

Introduction

Cataract extraction is one of the most performed outpatient procedures performed in the USA, with low rates of intraoperative complications for experienced surgeons. In resident-performed cases, however, complications such as a posterior capsular tear (5.8–15%) and vitreous loss (2.8–10%) occur much more commonly and can be associated with varying degrees of visual compromise [1].

Beyond surgeon experience, certain patient characteristics can increase the risk of intraoperative complications. For example, limited pharmacological mydriasis, presence of a dense or white cataract, prior surgery, zonular instability, and pseudoexfoliation have all been associated with an increased risk of complication [2, 3]. Poorly dilated pupils can limit the size of the capsulorhexis, increase the risk of iris injury, and reduce visualization for phacoemulsification and lens implantation. Compromised visualization of the red reflex from a mature cataract or vitreous hemorrhage can impact the construction of a continuous curvilinear capsulorhexis resulting in zonular compromise, vitreous loss, and ultimately the potential for intraocular lens decentration, requiring additional vitrectomy [4–6].

Capsular dye and pupil expansion devices (PED) are used to assist the visualization of critical anatomical structures. Cases that require these additional manipulations have been shown to be associated with a higher risk of having intraoperative complications. In a study by Narendran et al. [4], poor pupillary dilation and capsular visualization were associated with an increased odds of posterior capsule rupture and vitreous loss of 1.45 and 2.46, respectively.

This study aims to not only evaluate the overall complication rates for our most novice surgeons but furthermore to analyze the association of the use of capsular stain and/or a pupillary expansion device (PED) on the odds of a major complication requiring additional surgical intervention. Furthermore, preoperative risk factors, such as anterior chamber depth, axial length, vision, intraocular pressure, cataract type, and severity, were analyzed to determine any associations with a major surgical complication.

Methods

A systematic retrospective chart review of 1,348 consecutive operative reports of resident-performed cataract surgeries at the Montefiore Medical Center, Bronx, NY,

from *complete* academic years between July 2016 and June 2019 was performed. Cases from July 2019 to the present were excluded given elective surgical shutdowns during the spring of 2020 due to the COVID-19 pandemic. International Review Board approval was obtained from the Albert Einstein College of Medicine, and the study complied with both the Declaration of Helsinki and the Health Insurance Portability and Accountability Act. Surgeons were senior residents from the Montefiore ophthalmology residency training program, and all cases were attended by full-time teaching faculty from the department.

The primary outcome measures recorded from the operative chart review were a necessity for advanced major interventions such as anterior vitrectomy (AVx) and pars plana vitrectomy (PPVx) and the use of a PED or capsular dye. Types of PED included Malyugin Ring™ (MicroSurgical Technology, Redmond, WA, USA) or iris hooks (Flexible Iris Retractors, Alcon, Fort Worth, TX). 0.06% trypan blue ophthalmic solution (VisionBlue, Dutch Ophthalmic, Zuidland, Netherlands) is used as the capsular dye. Cases were subgrouped for analysis and referred to as “Routine” if *neither* capsular dye nor a PED was used, “Dye-only” if *only* capsular dye was used, “PED-only” if *only* a PED was used, or “Both” if *both* a pupil expansion device and capsular dye were used.

Routine cases were performed under IV sedation and topical anesthesia using intracameral preservative free 1% lidocaine. Surgeons utilized both cohesive and dispersive viscoelastics (DuoVisc™), and phacoemulsification was performed utilizing the Centurion™ platform (Alcon Laboratories, Ft Worth, Texas), followed by implantation of an intraocular lens in the capsular bag. For cases requiring vitrectomy, surgeons opted to place a lens in the ciliary sulcus and anterior chamber or leave the eye aphakic depending on the complication. The complication rate for each group (“Routine,” “Dye-only,” “PED-only,” and “Both”) was calculated, and statistical analysis was performed utilizing R3.6.2 (Microsoft, Redmond, WA). The “Routine” group was utilized as the reference group for a two-sided Fisher’s exact test with a calculation of the odds ratio with a 95% confidence interval, with a *P* value less than 0.05 considered significant.

For patients with PED usage (i.e., “PED-only” and “Both” groups), the following additional preoperative characteristics were collected (Tables 1 and 2): presence of diabetes mellitus, past history of ocular trauma, use of alpha antagonists (i.e., tamsulosin), corneal guttae, phacodonesis, pseudoexfoliative material, anatomical narrow angle, and level of pharmacological dilation at the time of surgical evaluation.

Table 1 Preoperative patient characteristics in patients requiring pupil dilation devices (i.e., “PED-only” and “Both” groups): presence of diabetes, trauma, alpha blocker use, guttae, phacodonesis, pseudoexfoliation syndrome, and anatomical narrow angle

| | Diabetes <i>n</i> (%) | Trauma <i>n</i> (%) | Alpha blocker <i>n</i> (%) | Guttae <i>n</i> (%) | Phacodonesis <i>n</i> (%) | Pseudoexfoliation <i>n</i> (%) | Anatomical narrow angle <i>n</i> (%) |
|-------------|--------------------------|------------------------|-------------------------------|------------------------|------------------------------|-----------------------------------|---|
| Present | 118 (61.8%) | 4 (2.1%) | 56 (29.3%) | 9 (4.7%) | 4 (2.1%) | 5 (2.6%) | 19 (9.9%) |
| Not present | 73 (38.2%) | 187 (97.9%) | 135 (70.7%) | 182 (95.3%) | 187 (97.9%) | 186 (97.4%) | 171 (90.1%) |

Table 2 Preoperative patient characteristics in patients requiring pupil dilation devices (i.e., “PED-only” and “Both” groups): degree of pupil dilation (*d* diameter)

| | Pupil dilation <i>n</i> (%) |
|--------------------------|--------------------------------|
| Poor ($d \leq 5$) | 71 (37.2%) |
| Moderate ($5 < d < 7$) | 65 (34.0%) |
| Good ($7 \leq d$) | 55 (28.8%) |

In addition, a case-control analysis (“Vitrectomy” vs. “No-Vitrectomy”) was performed in a subset of cases ($n=197$) to evaluate the impact of preoperative characteristics (anterior chamber depth, axial length) and exam findings (lens type/severity, intraocular pressure, preoperative vision) on risk of surgical complication. Given the larger sample of cases of “PED without complication” than the design ratio, we weighted the data to have a 1:1 ratio between cases and controls. A descriptive statistic was summarized using mean (SD) for continuous variable and count (%) for categorical variables, accounting for the sampling weight. A bivariate association between each risk factor and complication was examined using a weighted two-sample *t*-test and a weighted Chi-square test. We also fitted a weighted logistic regression on vitrectomy with the baseline risk factors with *P* value <0.2 in the bivariate analyses, followed by the backward model selection with Akaike information criterion (AIC). To account for heteroskedasticity, a robust SE was used in the inference.

Results

Of the 1,348 cases analyzed, 786 (58.3%) were “Routine,” 371 (27.5%) were “Dye-only,” 91 (6.8%) were “PED-only,” and 100 (7.4%) were “Both.” Complication rates for Malyugin rings and iris hooks were not statistically different, so cases using either device were grouped together as PED.

Preoperative mydriasis

Tables 1 and 2 summarize preoperative patient characteristics for those requiring PEDs (i.e., “PED-only” and “Both” groups). The majority of these patients carried the

diagnosis of diabetes mellitus ($n=118$, 61.8%). Pupillary dilation defined as poor (≤ 5 mm), or moderate (5–7 mm), was noted in 71 (37.2%) and 65 (34.0%) patients, respectively. Approximately a third ($n=56$, 29.3%) of patients had documented past or current use of an alpha blocker such as tamsulosin. Other less common characteristics include anatomical narrow angle ($n=19$, 9.9%), guttae ($n=9$, 4.7%), pseudoexfoliation ($n=5$, 2.6%), phacodonesis ($n=4$, 2.1%), and trauma ($n=4$, 2.1%).

Intraoperative complications requiring vitrectomy

A detailed analysis of the operative reports was performed to elucidate the nature of surgical complications. Of the 70 cases requiring a vitrectomy (anterior and/or pars plana), 47 cases were characterized by capsular compromise (e.g., capsular tear and anterior and/or posterior rent), 15 cases were noted to specifically mention zonular instability (e.g., zonular dehiscence, vitreous prolapse, and/or capsular tilting), and 8 cases did not specify the complication. Fourteen of the cases specifically mentioned the presence of retained lens material.

Anterior vitrectomy (AVx) only

AVx only (without combined or subsequent PPVx) was performed as an additional procedure in 2.65% ($n=20$ of 754) of “Routine” cases, 4.26% ($n=15$ of 352) of “Dye-only” cases, 4.94% ($n=4$ of 81) of “PED-only” cases, and 6.59% ($n=6$ of 91) in the cohort using “Both” devices (Fig. 1). The rates of AVx were not found to be significantly different across these groups compared to “Routine” cases ($P=0.14$) (Fig. 2).

Pars plana vitrectomy (PPVx) only

PPVx was performed in 1.59% ($n=12$ of 754) of “Routine” cases, 1.14% ($n=4$ of 352) of “Dye-only” cases, 7.41% ($n=6$ of 81) of “PED-only” cases, and 3.30% ($n=3$ of 91) of cases in the “Both” group (Fig. 1). The “PED-only” group had 4.64 times higher odds of having a PPVx compared to the “Routine” group (OR=4.64, 95% CI 1.68–12.79, $P=0.01$) (Fig. 2). The rate of PPVx was also higher in

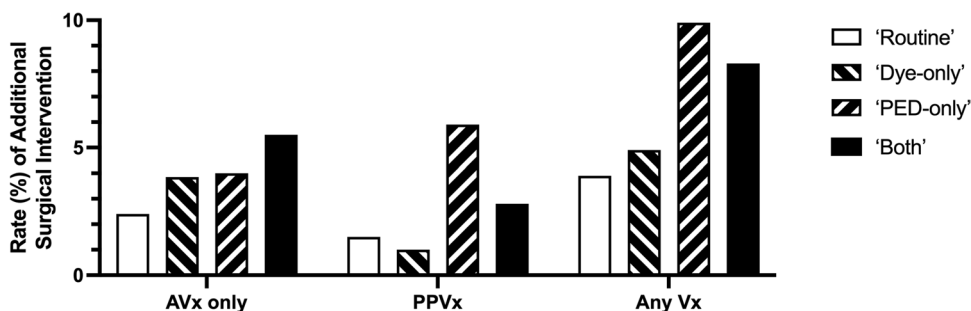
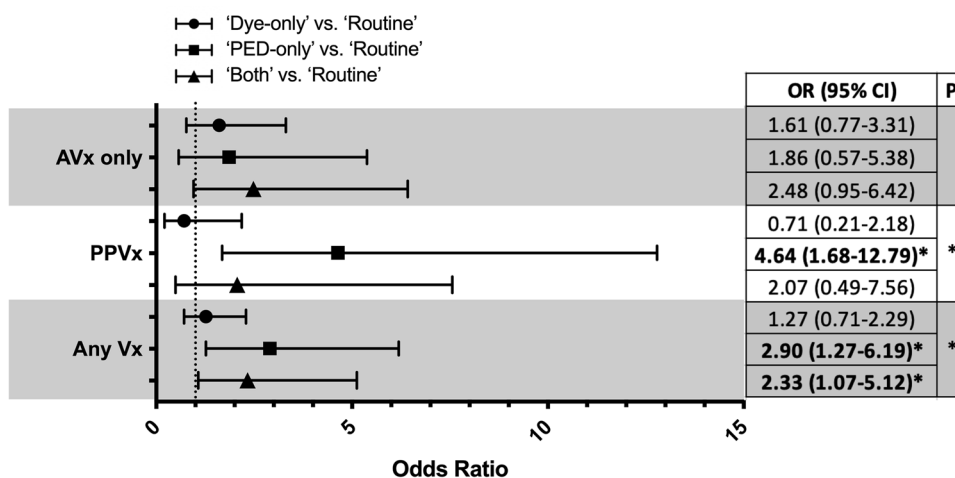


Fig. 1 Rate (%) by type of vitrectomy for each of the four groups. The highest overall vitrectomy rate (“Any Vx”) occurred in the “PED-only” group, and this difference was especially notable in the subgroup of patients that required a PPVx (“Routine,” no dye or pupil expansion

device; “Dye-only,” capsular dye; “PED-only,” pupil expansion device; “Both,” capsular dye and a pupil expansion device; “AVx,” anterior vitrectomy; “PPVx,” pars plana vitrectomy; “Vx,” vitrectomy)

Fig. 2 Odds ratio of vitrectomy (AVx and/or PPVx) for each group compared to “Routine” cases. The “PED-only” group has the highest odds of requiring a vitrectomy (“Any Vx”), which was especially notable in the subgroup of patients that required a PPVx (“Routine,” no dye or pupil expansion device; “Dye-only,” capsular dye; “PED-only,” pupil expansion device; “Both,” capsular dye and a pupil expansion device; “AVx,” anterior vitrectomy; “PPVx,” pars plana vitrectomy; “Vx,” vitrectomy)



the “PED-only” cases compared to the “Dye-only” cases (OR=6.48, $P=0.005$). The “Both” group had 0.45 times the odds of having PPVx compared to the “PED-only” group ($P=0.32$) (not graphed).

Overall vitrectomy

A vitrectomy (AVx and/or PPVx) was performed in 4.24% ($n=32$ of 754) of “Routine” cases, 5.40% ($n=19$ of 352) of “Dye-only” cases, 12.35% ($n=10$ of 81) of “PED-only” cases, and 9.89% ($n=9$ of 91) of cases in the “Both” group (Fig. 1). Compared to “Routine” cases, the “PED-only” group had 2.90 times higher odds of requiring a vitrectomy (95% CI 1.27–6.19, $P=0.01$), and cases from the “Both” group had 2.33 times higher odds (OR=2.33, 95% CI 1.07–5.12, $P=0.04$) (Fig. 2).

Table 3 Comparison of clinical findings for cases that required an anterior and/or pars plana vitrectomy (“Vitrectomy”) and routine cases (“No-Vitrectomy”). VA visual acuity, IOP intraocular pressure, short-term postoperative day 1, long-term after the postoperative period. * $P<0.05$

| | “Vitrectomy” | “No-Vitrectomy” | P value |
|---------------------------|--------------|-----------------|---------|
| Preoperative VA (log-MAR) | 1.1 ± 0.8 | 0.9 ± 0.8 | 0.160 |
| Short-term ΔVA (log-MAR) | 0.4 ± 0.8 | -0.3 ± 0.7 | 6.8e-7* |
| Long-term ΔVA (log-MAR) | -0.4 ± 0.7 | -0.6 ± 0.7 | 0.124 |
| Preoperative IOP (mmHg) | 17.7 ± 3.6 | 17.8 ± 3.4 | 0.921 |
| Short-term ΔIOP (mmHg) | 5.1 ± 8.9 | 2.4 ± 5 | 0.032* |
| Long-term ΔIOP (mmHg) | 0.1 ± 5.4 | -1.6 ± 4.6 | 0.048* |

* $P<0.05$

Visual acuity and intraocular pressure

A comparison of the preoperative visual acuity (VA) and intraocular pressure (IOP) was performed for the group that had a complication (“Vitreotomy”) to those without (“No-Vitreotomy”) (Table 3). At postoperative day 1, the “Vitreotomy” group experienced a decline in average visual acuity (an average change of 0.4 ± 0.8 log-MAR), whereas the “No-Vitreotomy” group had a slight improvement in visual acuity (an average change of -0.3 ± 0.7 logMAR) ($P=6.8e-7$). However, this effect was not significant ($P=0.124$) for long-term change in visual acuity after the immediate postoperative period. The “Vitreotomy” group had statistically significant differences in both short- and long-term changes in postoperative IOP. At postoperative day 1, the “Vitreotomy” group had an average increase in IOP of 5.1 ± 8.9 mmHg,

compared to an average increase of 2.4 ± 5.0 mmHg in the “No-Vitreotomy” group ($P=0.032$). Beyond the immediate postoperative period, the “Vitreotomy” group had an average increase in IOP of 0.1 ± 5.4 mmHg, compared to an average reduction of 1.6 ± 4.6 in the “No-Vitreotomy” group ($P=0.048$).

Anatomical considerations

Anterior chamber depth (ACD) and axial length (AL), as calculated by preoperative biometry, in addition to cataract type and severity, as documented in the preoperative note, were furthermore assessed to determine the association with a surgical complication (Table 4). There were no statistically significant differences in AL (23.7 ± 1.6 vs. 23.4 ± 1.2 mm, respectively; $P=0.144$) and ACD (3.2 ± 0.5 and 3.1 ± 0.4 mm, respectively; $P=0.203$) between the

Table 4 Baseline risk factors and complication in case-control analysis (PED pupil expansion device, VA visual acuity, IOP intraocular pressure, NSC nuclear sclerotic cataract, CC cortical cataract, PSC posterior sclerotic cataract, W/M white/mature). * $P<0.05$. Values are weighted mean \pm SD for continuous variables and weighted count (%) for categorical variables. P value by weighted t -test for continuous variables and weighted Chi-square test for categorical variables

| | Category | Vitreotomy | No vitrectomy | P value |
|-----------------------------|----------|----------------|----------------|-----------|
| PED | | 19 (27.1%) | 10 (13.6%) | 0.047* |
| Preoperative VA (logMAR) | | 1.1 ± 0.8 | 0.9 ± 0.8 | 0.160 |
| Preoperative IOP (mmHg) | | 17.7 ± 3.6 | 17.8 ± 3.4 | 0.921 |
| Axial length (mm) | | 23.7 ± 1.6 | 23.4 ± 1.2 | 0.144 |
| Anterior chamber depth (mm) | | 3.2 ± 0.5 | 3.1 ± 0.4 | 0.203 |
| Main cataract type | | | | |
| | NSC | 34 (49.3%) | 42 (60.5%) | 0.105 |
| | CC | 5 (7.2%) | 9 (13%) | |
| | PSC | 8 (11.6%) | 2 (3.2%) | |
| | W/M | 22 (31.9%) | 16 (23.4%) | |
| NSC severity | | | | 0.118 |
| | Mild | 8 (17%) | 7 (13.7%) | |
| | Moderate | 16 (34%) | 28 (54.4%) | |
| | Severe | 23 (48.9%) | 17 (31.9%) | |
| CC severity | | | | 0.627 |
| | Mild | 8 (40%) | 7 (32.7%) | |
| | Moderate | 7 (35%) | 6 (28%) | |
| | Severe | 5 (25%) | 8 (39.3%) | |
| PSC severity | | | | 0.614 |
| | Mild | 2 (14.3%) | 3 (29%) | |
| | Moderate | 5 (35.7%) | 2 (21.7%) | |
| | Severe | 7 (50%) | 5 (49.3%) | |

* $P<0.05$

Table 5 Multiple logistic regression between complications requiring vitrectomy and main cataract type and severity (PED pupil expansion device, NSC nuclear sclerotic cataract, CC cortical cataract, PSC posterior sclerotic cataract, W/M white/mature). * $P<0.05$

| | OR (95% CI) | P value |
|---|-------------------|-----------|
| Pupil expansion device (PED) | 2.09 (1.00–4.39) | 0.051 |
| Main cataract type (nuclear sclerosis as reference) | 1 (ref) | |
| Cortical change (CC) | 1.32 (0.32–5.45) | 0.705 |
| Posterior subscapsular (PSC) | 7.86 (1.46–42.47) | 0.017* |
| White/mature | 3.05 (1.1–8.43) | 0.032* |
| NSC severity (mild-grade 1 as reference) | 1 (ref) | |
| Moderate (grades 2–3) | 0.55 (0.04–7.34) | 0.648 |
| Severe (grade 4+) | 1.56 (0.12–20.26) | 0.736 |

* $P<0.05$

“Vitreotomy” and “No-Vitreotomy” groups. The cataract type and severity did not have a significant association with vitrectomy in the univariate analysis.

Variables with $P < 0.2$ in the univariate analysis (Table 4) were further investigated in a multivariate analysis (Table 5). Compared to nuclear sclerotic cataract, posterior subcapsular and white/mature cataracts have significantly higher odds of vitrectomy (OR = 7.86, 95% CI 1.46–42.47, $P = 0.017$ and 3.05, 95% CI 1.1–8.43, $P = 0.032$, respectively) (Table 5).

Independent of these anatomical considerations, the use of a PED continued to demonstrate an association with surgical complication ($P = 0.047$ in univariate analysis; OR = 2.09, 95% CI 1–4.39, $P = 0.051$ in multivariate analysis) (Tables 4 and 5).

Discussion

Complex cataract extraction, characterized by poor pupillary dilation with or without poor capsular visualization, intuitively requires a higher level of technical skill compared to more routine procedures. There are varying reports on residents' learning curve in phacoemulsification in terms of the rates of intraoperative and postoperative complications with increasing training experiences. Some studies [7, 8] found no difference, while others [9–14] reported that complication rates decline with increasing surgical experience. Aaronson et al. [10] reviewing 14,520 cataract surgeries reported that complication rates (posterior capsule rupture and/or loss of capsular bag support) decline with increasing surgical experience, also among residents over time. Randlewood et al. [15] found that residents continue to improve their surgical competency (complication rates and phacoemulsification efficiency) significantly well beyond the first 80 resident phacoemulsification cases.

Our resident cohort had no prior experience performing cataract extraction before their training. Resident-performed cases are attended by experienced surgeons who teach the procedure by providing graduated autonomy and real-time assistance and guidance on a step-by-step basis. As it is not possible to retroactively assess the relative involvement of the attending surgeon from the medical record alone, a longitudinal assessment of resident complications throughout their training was not a focus of this analysis.

Our analysis demonstrated an overall vitrectomy rate for resident surgeons of 5.5% (range 4.24–12.35%), similar to prior reports in the literature (range 4.04–15%) [9, 16, 17]. Furthermore, we found the rates of a major complication requiring an unplanned vitrectomy to be higher for complex cases requiring pupil expansion, independent of other potential anatomical factors. There were no statistically significant differences in axial length ($P = 0.144$), anterior chamber depth ($P = 0.203$), main cataract types or severity ($P = 0.015$

for type, $P = 0.118$ for NSC severity, $P = 0.627$ for CC severity, $P = 0.614$ for PSC severity) between the “Vitreotomy” and “No-Vitreotomy” groups. In the multivariate analysis, patients with mainly posterior subcapsular and white/mature cataracts had higher odds of surgical complications compared to patients with mainly nuclear sclerotic cataracts, consistent with several other studies [4, 9, 18].

There are additionally varying reports in the literature on the rate of intraoperative complications in patients with limited pupillary dilation [4, 9, 18–20]. The largest study reviewing 55,567 cases performed by 406 surgeons (*of all experience levels*) in the UK reported an adjusted odds ratio of 1.45 (95% CI 1.10–1.91; $P = 0.0231$) for complications in patients with small pupils compared to those with medium and large pupils [4]. Our data similarly demonstrated an increased odds of a major complication, namely, vitreous loss, when a pupil expansion device was used; cases requiring a PED had a higher odd (OR = 4.64, $P = 0.01$) of requiring an unplanned PPVx compared to routine cases. It is important to note that these complications occurred despite the usage of PED, as our analysis was designed to analyze the association and not necessarily causation. Although the use of PED improves visualization and limits iris prolapse, these eyes may have additional factors (e.g., case duration, anterior chamber stability, and anesthesia considerations) that increase the likelihood of complication beyond the additional technical skills required for placement and removal.

Pseudoexfoliation syndrome is known to complicate cataract surgeries due to poor mydriasis, weak zonular support, and high intraocular pressure [21, 22]. Interestingly, many recent studies have found lack of significant association of pseudoexfoliation syndrome and vitreous complications [18, 23, 24]. This indicates that not all patients with pseudoexfoliation syndromes are at a high risk, and further preoperative evaluation of these patients may be warranted for assessment of their operative risk; one such suggestion is a new clinical classification for predicting the zonular strength based on the maximum pupillary dilation [25].

Our findings are echoed by Williams et al. [26], which reviewed 5,772 eyes that underwent phacoemulsification (including 4,905 non-complex, 500 complex without iris manipulation, and 367 complex with manipulation). Williams et al. [26] found that the incidence of any intraoperative complication in complex cases, regardless of iris manipulation, is significantly higher than in the non-complex phacoemulsification ($P < 0.0001$). However, when comparing intraoperative complications in complex cases with and without iris manipulation, there were no statistically significant differences in rates of posterior capsule rupture, vitreous loss, retained lens, and zonular dialysis ($P = 0.623$, 0.692, 0.622, and 0.457, respectively). In addition, the authors found that only complex cases with iris manipulation led to increased rates of postoperative inflammation

(OR=2.3; $P=0.005$) and IOP spikes of more than 10 mmHg ($P=0.001$); they suggest that direct iris manipulation, as opposed to just the case complexity, is associated with postoperative inflammation and IOP spikes [26].

Additional vitrectomy rates were not statistically different between the two types of PED analyzed (Malyugin rings and iris hooks); this finding is supported by Nderitu and Ursell [20] who found that despite longer operating time, iris hooks are as safe and effective as Malyugin rings with similar intraoperative complications. However, they also reported there was a significantly increased risk of postoperative complication (anterior uveitis, corneal edema, etc.) with the use of the Malyugin ring (6.7%) compared to routine cases (2.6%), or cases utilizing iris hooks (1.1%) [20].

There is a great deal of variability in the criteria for use of capsular dye, as many contributing factors can dictate the use of these devices (supervising attending preferences, microscope parameters, resident experience levels, etc.). It is indeed the case that even highly trained surgeons utilize capsular dye to improve visualization in routine cases, and the use of dye should not necessarily be interpreted as an absolute indicator of case complexity. When we compared “Routine” cases to “Dye-only,” there were no significant differences in the odds of an AVx and/or a PPVx, indicating that the use of dye did not have an impact on complication rate. When comparing “PED-only” cases to both the “Routine” and “Dye-only” groups, there were significantly higher odds of vitreous loss requiring a PPVx (OR=4.64, $P=0.01$ and OR=6.48, $P=0.005$, respectively). The higher odds ratio noted here when comparing the “PED-only” to the “Dye-only” group suggests that the use of a PED without capsular dye purports a higher risk of a complication; however, when we analyzed complication rates for the “PED-only” and “Both” groups, there were no statistically significant differences in vitrectomy rates. These results demonstrate that the routine use of capsular dye does not have a definitive impact on complication rate, and surgeons (of all levels of expertise) should use capsular dye based on individual case requirements and preferences. We can furthermore infer that the complications associated with the use of a PED were not related to diminished anterior capsule visualization and were secondary to any number of the other potential complicating factors (Tables 1, 2, 4, and 5) that limit anterior chamber stability and visualization. Regardless, resident-performed cases where pupil expansion was required had significantly higher odds of complication, and it is critical for supervising attendings and perioperative services to be appropriately prepared for potential complications given the magnitude of this association.

A major limitation of this study is related to the retrospective nature of the chart review. However, we believe operative reports consistently describe when major complications such as vitreous loss and lens subluxation occur,

and the rates of complications reported are representative of actual surgical events. Regardless, the details of why and how a complication occurred are variably described, and it is important not to ascribe causality from an association without a carefully designed prospective analysis to evaluate that specific question. Higher complication rates due to capsular compromise and zonular instability occur in cases where PEDs are utilized, but not necessarily as a direct result of their use. An additional limitation results from variable levels of resident participation in surgery, which is often not recorded in the operative report. A more comprehensive analysis with a larger sample is warranted to further assess the impact of the various factors that increase case complexity to help further minimize vision-threatening complications.

Acknowledgements Data collection assisted by Uzo Davis Anugo MD, David Lu MD, Tim Truong MD, and Jessie Wang MD.

Funding This study was funded by Albert Einstein College of Medicine, Ronald M. Burde Ophthalmic Education Fund, Montefiore Center for Ophthalmic Innovation, and Manhattan Eye and Ear Ophthalmology Alumni Foundation.

Declarations

Ethics approval This article does not contain any studies with animals performed by any of the authors.

Conflict of interest Dr. Shrivastava is a consultant (Alcon, Abbvie), data safety monitor (IQVIA), and researcher (Abbvie, Nicox).

References


1. Tzamalīs A, Lamprogiannis L, Chalvatzis N, Symeonidis C, Dimitrakos S, Tsinopoulos I (2015) Training of resident ophthalmologists in cataract surgery: a comparative study of two approaches. *J Ophthalmol* 2015:932043. <https://doi.org/10.1155/2015/932043>
2. Han JV, Patel DV, Wallace HB, Kim BZ, Sherwin T, McGhee CNJ (2019) Auckland Cataract Study III: refining preoperative assessment with cataract risk stratification to reduce intraoperative complications. *Am J Ophthalmol* 197:114–120. <https://doi.org/10.1016/j.ajo.2018.09.026>
3. Nderitu P, Ursell P (2018) Updated cataract surgery complexity stratification score for trainee ophthalmic surgeons. *J Cataract Refract Surg* 44:709–717. <https://doi.org/10.1016/j.jcrs.2018.04.036>
4. Narendran N, Jaycock P, Johnston RL, Taylor H, Adams M, Tole DM, Asaria RH, Galloway P, Sparrow JM (2009) The Cataract National Dataset electronic multicentre audit of 55,567 operations: risk stratification for posterior capsule rupture and vitreous loss. *Eye (Lond)* 23:31–37. <https://doi.org/10.1038/sj.eye.6703049>
5. Dada VK, Sharma N, Sudan R, Sethi H, Dada T, Pangtey MS (2004) Anterior capsule staining for capsulorhexis in cases of white cataract: comparative clinical study. *J Cataract Refract Surg* 30:326–333. [https://doi.org/10.1016/S0886-3350\(03\)00573-X](https://doi.org/10.1016/S0886-3350(03)00573-X)
6. Goldman JM, Karp CL (2007) Adjunct devices for managing challenging cases in cataract surgery: capsular staining and ophthalmic

- viscosurgical devices. *Curr Opin Ophthalmol* 18:52–57. <https://doi.org/10.1097/ICU.0b013e3280121b24>
7. Fong CS, Mitchell P, de Loryn T, Rochtchina E, Hong T, Cugati S, Wang JJ (2012) Long-term outcomes of phacoemulsification cataract surgery performed by trainees and consultants in an Australian cohort. *Clin Exp Ophthalmol* 40:597–603. <https://doi.org/10.1111/j.1442-9071.2012.02759.x>
 8. Woodfield AS, Gower EW, Cassard SD, Ramanathan S (2011) Intraoperative phacoemulsification complication rates of second- and third-year ophthalmology residents a 5-year comparison. *Ophthalmology* 118:954–958. <https://doi.org/10.1016/j.ophtha.2010.08.047>
 9. Rutar T, Porco TC, Naseri A (2009) Risk factors for intraoperative complications in resident-performed phacoemulsification surgery. *Ophthalmology* 116:431–436. <https://doi.org/10.1016/j.ophtha.2008.10.028>
 10. Aaronson A, Viljanen A, Kanclerz P, Grzybowski A, Tuuminen R (2020) Cataract complications study: an analysis of adverse effects among 14,520 eyes in relation to surgical experience. *Ann Transl Med* 8:1541. <https://doi.org/10.21037/atm-20-845>
 11. Ellis EM, Lee JE, Saunders L, Haw WW, Granet DB, Heichel CW (2018) Complication rates of resident-performed cataract surgery: impact of early introduction of cataract surgery training. *J Cataract Refract Surg* 44:1109–1115. <https://doi.org/10.1016/j.jcrs.2018.06.022>
 12. Kaplowitz K, Yazdanie M, Abazari A (2018) A review of teaching methods and outcomes of resident phacoemulsification. *Surv Ophthalmol* 63:257–267. <https://doi.org/10.1016/j.survophthal.2017.09.006>
 13. Bai H, Yao L, Wang H (2020) Clinical investigation into posterior capsule rupture in phacoemulsification operations performed by surgery trainees. *J Ophthalmol* 2020:1317249. <https://doi.org/10.1155/2020/1317249>
 14. Melega MV, Pessoa Cavalcanti Lira R, da Silva IC, Ferreira BG, Assis Filho HLG, Martini AAF, Dos Reis R, Arieta CEL, Alves M (2020) Comparing resident outcomes in cataract surgery at different levels of experience. *Clin Ophthalmol* 14:4523–4531. <https://doi.org/10.2147/OPHTH.S285967>
 15. Randleman JB, Wolfe JD, Woodward M, Lynn MJ, Cherwek DH, Srivastava SK (2007) The resident surgeon phacoemulsification learning curve. *Arch Ophthalmol* 125:1215–1219. <https://doi.org/10.1001/archophth.125.9.1215>
 16. Oliveira-Ferreira C, Leuzinger-Dias M, Tavares Ferreira J, Macedo JP, Falcao-Reis F (2020) Cataract phacoemulsification performed by resident trainees and staff surgeons: intraoperative complications and early postoperative intraocular pressure elevation. *J Cataract Refract Surg* 46:555–561. <https://doi.org/10.1097/j.jcrs.000000000000105>
 17. Saifee M, Zhu I, Lin Y, Oldenburg CE, Ramanathan S (2020) Effect of full-time vs volunteer faculty supervision on resident cataract surgery complications. *J Cataract Refract Surg* 46:700–704. <https://doi.org/10.1097/j.jcrs.000000000000145>
 18. Blomquist PH, Morales ME, Tong L, Ahn C (2012) Risk factors for vitreous complications in resident-performed phacoemulsification surgery. *J Cataract Refract Surg* 38:208–214. <https://doi.org/10.1016/j.jcrs.2011.10.001>
 19. Kim JY, Ali R, Cremers SL, Yun SC, Henderson BA (2009) Incidence of intraoperative complications in cataract surgery performed by left-handed residents. *J Cataract Refract Surg* 35:1019–1025. <https://doi.org/10.1016/j.jcrs.2009.01.025>
 20. Nderitu P, Ursell P (2019) Iris hooks versus a pupil expansion ring: operating times, complications, and visual acuity outcomes in small pupil cases. *J Cataract Refract Surg* 45:167–173. <https://doi.org/10.1016/j.jcrs.2018.08.038>
 21. Shingleton BJ, Crandall AS, Ahmed II (2009) Pseudoexfoliation and the cataract surgeon: preoperative, intraoperative, and postoperative issues related to intraocular pressure, cataract, and intraocular lenses. *J Cataract Refract Surg* 35:1101–1120. <https://doi.org/10.1016/j.jcrs.2009.03.011>
 22. Ariga M, Nivean M, Utkarsha P (2013) Pseudoexfoliation syndrome. *J Curr Glaucoma Pract* 7:118–120. <https://doi.org/10.5005/jp-journals-10008-1148>
 23. Nagashima RJ (2004) Decreased incidence of capsule complications and vitreous loss during phacoemulsification in eyes with pseudoexfoliation syndrome. *J Cataract Refract Surg* 30:127–131. [https://doi.org/10.1016/S0886-3350\(03\)00465-6](https://doi.org/10.1016/S0886-3350(03)00465-6)
 24. Hyams M, Mathalone N, Herskovitz M, Hod Y, Israeli D, Geyer O (2005) Intraoperative complications of phacoemulsification in eyes with and without pseudoexfoliation. *J Cataract Refract Surg* 31:1002–1005. <https://doi.org/10.1016/j.jcrs.2004.09.051>
 25. Nath M, Odayappan A, Tripathy K, Krishnamurthy P, Nachiappan S (2021) Predicting zonular strength based on maximum pupillary mydriasis in patients with pseudoexfoliation syndrome. *Med Hypotheses* 146:110402. <https://doi.org/10.1016/j.mehy.2020.110402>
 26. Williams ER, Patnaik JL, Miller DC, Lynch AM, Davidson RS, Kahook MY, Seibold LK (2021) Iris manipulation during phacoemulsification: intraoperative and postoperative complications. *Int J Ophthalmol* 14:676–683. <https://doi.org/10.18240/ijo.2021.05.06>

Publisher's note Springer Nature remains neutral with regard to jurisdictional claims in published maps and institutional affiliations.

Springer Nature or its licensor (e.g. a society or other partner) holds exclusive rights to this article under a publishing agreement with the author(s) or other rightsholder(s); author self-archiving of the accepted manuscript version of this article is solely governed by the terms of such publishing agreement and applicable law.

Authors and Affiliations

Sally SE Park¹ · Michael Tseng¹ · Zara Mian¹ · Jee-Young Moon² · Anurag Shrivastava^{1,3} 

✉ Anurag Shrivastava
ashrivast@montefiore.org

¹ Department of Ophthalmology and Visual Sciences, Montefiore Medical Center, Bronx, NY, USA

² Department of Epidemiology & Population Health, Albert Einstein College of Medicine, Bronx, NY, USA

³ Albert Einstein College of Medicine, Montefiore Medical Center, 3332 Rochambeau Ave, 3rd Floor, Bronx, NY 10467, USA