



# Macular vessel density reduction in patients recovered from COVID-19: a longitudinal optical coherence tomography angiography study

Mojtaba Abrishami<sup>1,2</sup> · Kiana Hassanpour<sup>3</sup> · SeyedehMaryam Hosseini<sup>1</sup> · Zahra Emamverdian<sup>1</sup> · Mohammad-Reza Ansari-Astaneh<sup>1</sup> · Ghodsieh Zamani<sup>1</sup> · Bahareh Gharib<sup>1</sup> · Majid Abrishami<sup>1</sup>

Received: 10 June 2021 / Revised: 16 September 2021 / Accepted: 23 September 2021 / Published online: 12 October 2021  
© The Author(s), under exclusive licence to Springer-Verlag GmbH Germany, part of Springer Nature 2021

## Abstract

**Background/aims** To quantify the longitudinal changes of the macular microvasculature and the foveal avascular zone (FAZ) parameters in patients recovered from coronavirus disease-2019 (COVID-19) using optical coherence tomography angiography (OCTA) analysis.

**Methods** This observational, longitudinal study was performed on patients recovered from COVID-19. The OCTA images were recorded at baseline and after 1 and 3 months at the follow-up examination. Vessel density (VD) of the retinal superficial (SCP) and deep capillary plexus (DCP), as well as the area of the FAZ of patients who had recovered from COVID-19, were measured.

**Results** In total, 36 eyes of 18 patients (62.2% female) with a mean age of  $34.5 \pm 7.5$  years old were included. Regarding SCP, while the VDs of the whole image, fovea, and parafovea were comparable at different time points, the mean VDs in inferior hemifield, as well as superior and inferior regions of parafovea, underwent significant reductions at month 3, compared to the baseline. In DCP, the mean of VD in the whole image was  $54.3 \pm 2.7$  at the first visit which significantly decreased to  $52.1 \pm 3.8$  ( $P=0.003$ ) and  $51.4 \pm 2.7$  ( $P=0.001$ ) after 1 and 3 months, respectively. The VDs in all regions of parafovea and parafovea revealed a significant reduction after 1 and 3 months, compared to the first visit. The mean FAZ area was  $0.27 \pm 0.08$  mm<sup>2</sup>,  $0.26 \pm 0.08$  mm<sup>2</sup>, and  $0.27 \pm 0.08$  mm<sup>2</sup> at the baseline, month 1, and month 3, respectively ( $P>0.05$ ).

**Conclusion** Based on the results, the patients who had recovered from COVID-19 had a progressive decrease of VD at the follow-up visit 3 months after COVID-19 infection.

## Key messages

- Vessel density in superficial and deep retinal capillary plexuses in the macular perifoveal and parafoveal regions is reduced in patients with a history of Coronavirus disease 2019 (COVID-19).
- The patients who recovered from COVID-19 had a progressive decrease of VD at the follow-up visit three months after the COVID-19 infection.
- The foveal avascular zone did not reveal significant changes in the present study.
- COVID-19 may affect the endothelial cells in various organs including retinal vessels

**Keywords** Coronavirus disease 2019 (COVID-19) · Optical coherence tomography angiography (OCTA) · Macula · Retina · Severe acute respiratory syndrome coronavirus 2 (SARS-CoV-2)

## Introduction

In December 2019, severe acute respiratory syndrome corona virus 2 (SARS-CoV-2), a recently discovered member of the Coronaviridae family, was found in Wuhan, China,

✉ Mojtaba Abrishami  
mojtaba\_abrishami@yahoo.com

Extended author information available on the last page of the article

and quickly spread to other countries which led to a worldwide pandemic [1]. Coronavirus disease 2019 (COVID-19) is primarily an infection in the lower respiratory tract that is transmitted especially through respiratory droplets and physical contact. It can cause pneumonia and multi-organ failure which can be fatal in patients at severe stages of the disease [1].

The virus binds to the epithelial cells in the upper respiratory tract and subsequently propagates and migrates down the respiratory tract; afterward, it replicates [2]. It triggers the innate immune response via its main receptor, angiotensin-converting enzyme (ACE) 2 [3]. The ACE2 receptors are present in various types of cells in the body, such as cell membranes of type II alveolar cells in the lung and enterocytes of the small intestine, the arterial and venous endothelial cells, and arterial smooth muscle cells of most organs [3]. The ACE and ACE2 have been seen in the choroid and different cell types of the retina, including Müller cells, ganglion cells, retinal vascular endothelial cells, and photoreceptor cells [4].

Results of previous studies about the ocular manifestations of COVID-19 primarily report anterior segment presentations, such as conjunctival congestion, chemosis, conjunctivitis, clear ocular secretions, conjunctival follicles, and tender preauricular lymphadenopathy [5, 6]. Subsequently, although it is rare, posterior segment, uveitic, and neuro-ophthalmic manifestations have been reported [7–11]. In our previous cross-sectional case–control research project, we found a decrease in the macular vascular density of the recovered COVID-19 patients [12]. Other later reports also support these optical coherence tomography angiography (OCTA) findings of COVID-19 patients [13–16].

This longitudinal study aimed to examine patients with a history of SARS-CoV-2 infection by OCTA analysis to evaluate the retinal microvasculature. The purpose of the present research was to measure the vessel density (VD) of the retinal capillary plexuses and the area of the foveal avascular zone (FAZ) at the follow-up visit after 3 months.

## Materials and methods

### Study participants

This longitudinal study was carried out at the Khatam Eye Hospital, the referral eye center of Mashhad University of Medical Sciences (MUMS), Mashhad, Iran. The inclusion criteria were a definite history of COVID-19 confirmed by the positive test result of a nasopharyngeal swab sample with real-time reverse transcription-polymerase chain reaction (RT-PCR) and a history of recovery from the systemic symptoms for at least 1 week. Detailed ocular and systemic histories of all the participants were collected. All

the patients included in this study were the personnel of the Khatam Eye Hospital who had recovered from COVID-19. They volunteered to go through ophthalmological examination and OCTA analysis in all three follow-up visits for the objectives of the present study.

The exclusion criteria were any history of refractive or intraocular surgery, history of diabetes mellitus, glaucoma, migraine, breastfeeding, current pregnancy, clinically apparent retinal disease, or auto-immune diseases. Those who had a history of hospitalization or systemic corticosteroid treatment for COVID-19 were not included. Furthermore, patients with a spherical refractive error greater than 5 diopters and a cylindrical refractive error of more than 2 diopters were also excluded. Any evidence of ocular media opacity preventing high-quality imaging or reduced OCTA scan quality (i.e., quality scan index less than 7/10) were also not included in the analysis. In addition, those with the best-corrected visual acuity less than 20/20 were also excluded from the protocol.

Personnel who were infected with COVID-19 and returned to their workplace 2 weeks after the completion of the symptomatic period were included in the study during the first week after their return. Patients were also imaged using the same machine 1 and 3 months after their return. All imaging was performed between 11 AM and 2 PM to avoid diurnal changes in VD and by one operator. Patients who did not complete the follow-up imaging were excluded from the study.

### Image acquisition and analysis

All the OCTA scans were performed with the AngioVue system (RTVue XR Avanti, Optovue, Fremont, CA, USA; Software version 2018.0.0.14). The centration of the fovea was checked for all images. All measurements were performed using the automated default segmentation with the preset settings for the superficial retinal capillary plexus (SCP) and the deep retinal capillary plexus (DCP); afterward, all segmentations were checked manually. We used the AngioRetina protocols of 3 × 3-mm scan (304 lines × 304 lines A-scans) and 6 × 6 mm scan (400 lines × 400 lines A-scans) using the AngioVue 3D Projection Artifact Removal technique.

All images were centered on the fovea and displayed a quality scan index of at least 7/10. All images with a quality scan index of less than seven were not included in the study. All images in the study were carefully reviewed by the two retina specialists (MA and MRAA) to ensure their adequate quality and resolution. Moreover, the images with significant motion artifacts that interfered with vessel density analysis, according to both the first author (MoA), were not included.

For the 3 × 3-mm scans, measurements of the fovea avascular zone (FAZ) (namely FAZ area, the perimeter

circumference of the FAZ [PERIM], and foveal vessel density [FD]) and the vascular density (VD) of the fovea and parafovea at the level of the SCP and DCP were recorded. The VDs in perifoveal regions were extracted from the 6×6-mm AngioAnalytic report. A circle with an inner diameter of 1 mm and an outer diameter of 3 mm was considered the parafoveal area. Accordingly, a circle with a diameter of 6 mm and an inner diameter of 3 mm was considered a perifoveal region. Two retina specialists checked all the images for segmentation errors (MA and SMH).

### Statistical analysis

To present the data, descriptive statistics were used, including mean, median, standard deviation (SD), and range. The normal distribution of variables was tested using the Shapiro–Wilk test and normality plots and homogeneity of variances were examined by Levene's test. To compare changes within the study subjects generalized estimating equation analyses were performed. It should be mentioned that a *p*-value of 0.05 was considered statistically significant. All statistical analyses were performed using the SPSS software for Windows (version 25).

### Ethical considerations

The study was performed based on the tenets of the Declaration of Helsinki. Accordingly, written informed consent was obtained from all participants before enrollment and the study was ethically approved by the Regional Committee on Medical Ethics at Mashhad University of Medical Sciences (IR.MUMS.MEDICAL.REC.1399.402).

### Results

In total, 36 eyes of 18 patients were entered into the present study. The mean age of the participants was  $34.5 \pm 7.5$  years old (median = 34, range: 24–51) and 61.1% ( $n = 11$ ) of the participants were female.

Means (median, range) of scan quality indices were 8.4 (8, 7–9), 8.3 (8, 7–9), and 8.5 (9, 7–9) at the first visit, and after 1 and 3 months, respectively. There was no statistically significant difference between the scan qualities (*p*-value = 0.27), and segmentation errors were found in none of the images included in the final analysis. In SCP, the mean VD (%) (3×3-mm scan) of the whole image ( $\pm$ SD) was  $46.5 \pm 3.4$  at the first visit and decreased to  $45.8 \pm 3.1$  and  $45.7 \pm 3.3$  after 1 and 3 months, respectively ( $P > 0.05$ ).

The corresponding values for the foveal VD (%) were  $18.7 \pm 3.4$ ,  $18.5 \pm 5.2$ , and  $18.3 \pm 5.3$ , respectively. In the whole image of fovea and parafovea, VDs remained comparable between different visits while VD of perifoveal inferior

hemifield significantly decreased from  $51.2 \pm 2.6$  at the first visit to  $49.8 \pm 2.9$  after 3 months (*p*-value = 0.024). Similar significant reduction patterns were observed in perifoveal superior and inferior regions between the baseline and the third months (Table 1).

In DCP, the mean of VD (%) in the whole image (3×3) was  $54.3 \pm 2.7$  at the first visit and significantly decreased to  $52.1 \pm 3.8$  ( $P = 0.003$ ) and  $51.4 \pm 2.7$  ( $P = 0.001$ ) after 1 and 3 months, respectively. The corresponding values for the DCP VD of fovea (%) were  $35.4 \pm 6.0$ ,  $34.8 \pm 6.2$ , and  $34.5 \pm 6.1$  at the abovementioned visits, respectively ( $P = 0.054$ ). Regarding the parafovea (3×3) and perifovea (6×6), VDs in all regions revealed a significant reduction after 1 and 3 months, compared to the first visit (Table 2).

The mean FAZ area was  $0.27 \pm 0.08$  mm<sup>2</sup>,  $0.26 \pm 0.08$  mm<sup>2</sup>, and  $0.27 \pm 0.08$  mm<sup>2</sup> at the first visit and after 1 and 3 months, respectively, which were not statistically significant (Table 3). Correspondingly, the mean of PERIM (perimeter circumference of the FAZ) was  $2.07 \pm 0.3$  mm,  $2.04 \pm 0.33$  mm, and  $2.06 \pm 0.35$  mm at the aforementioned visits, respectively. The FAZ and PERIM were comparable at different time intervals (Fig. 1).

### Discussion

In this longitudinal study, the vascular density of the retinal capillary microvasculature in a cohort of relatively young recovered COVID-19 patients in a midterm follow-up was compared using the OCTA. The severity of COVID-19 was relatively mild, and none of the patients needed hospitalization. The mean values of macular SCP VD and DCP VD significantly decreased in the COVID-19 cohort during the follow-up, more prominently in the DCP while the FAZ area change was not statistically significant.

The SARS-CoV-2 virus was detected in the tears of symptomatic and asymptomatic patients and also in the retina of the deceased patients [17–19]. In previous reports of ocular tropism of coronaviruses, many ocular diseases have been attributed to diseases caused by the family Coronaviridae [20]. Reports of pulmonary and extrapulmonary microvascular injury and thrombosis in patients with severe COVID-19 infection would seem to underline the significance of assessing the retinal vascular involvement with this disease [21].

Endotheliopathy due to direct endothelial infection with SARS-CoV-2 and the indirect damage caused by inflammation have also reported extrapulmonary presentations of COVID-19 [22]. Nevertheless, the expression of ACE and ACE2 in various cell types of the retina, choroid, and different vessel types [4] have been reported far before the emergence of COVID-19. Hence, these findings indicate the possibility of retinal implications of the SARS-CoV-2 infection through a wide variety of mechanisms.

Multiple hypotheses are explaining the reduced VD in patients with COVID-19. First, the direct invasion of the virus to the endothelial cells of blood vessels could cause microangiopathy in multiple organs. In a postmortem analysis, endotheliitis was found in several organs as a direct consequence of viral involvement, with evidence of the presence of viral inclusion structures, accompanying the host inflammatory response [23]. Second, it has been previously shown that retinal VD increases in response to hypoxemia and inversely decreases as a result of hyperoxemia [24, 25].

The use of supplemental oxygen in the acute phase of the disease has been considered a possible mechanism. However, the continuous reduction observed in the present study diminished the role of hyperoxemia proposed in previous reports [16]. Another plausible mechanism is the inflammatory-mediated responses to COVID-19 infection. Inflammation can cause overexpression of adhesion molecules on the endothelial cells through inflammatory cytokines. Endothelial dysfunction is the ultimate outcome of the interaction between proinflammatory cytokines and endothelial cells [26].

In the first case-series report of retinal changes in patients with COVID-19, Marinho et al. reported cotton-wool spots and microhemorrhages in four patients which suggest an

inner retinal ischemic process [27], although the OCT findings were questioned later [28]. However, funduscopy retinal hemorrhages and ischemic retinal presentations were also reported later [29–31].

In the present research, the SCP VD and DCP VD significantly decreased in a longitudinal midterm follow-up, and the changes were more pronounced in DCP. It is well-known that COVID-19 can cause widespread microangiopathy in several extrapulmonary organs, including the brain [32], intestine [33], heart [34], and kidneys [35]. Therefore, microvascular angiopathy and subsequent changes in the blood flow of the retina are not surprising findings.

The findings of the present study are in line with those of the previous research performed on the retinal microvascular changes in patients with COVID-19. In recent case-control studies, using Optovue AngioVue OCTA machine, alterations of retinal microvasculature are found subsequent to COVID-19 infections, compared to healthy control groups [12, 13]. Moreover, in a case-control study performed on patients with mild, moderate, and severe COVID-19 and normal controls, patients with moderate and severe disease had decreased macular VD on OCTA, compared to control subjects or even those who were asymptomatic or paucisymptomatic [16].

**Table 1** Vascular density of the superficial capillary plexuses in the foveal, parafoveal, and perifoveal regions in recovered patients with COVID-19 at baseline, after 1 and 3 months

SCP VD (%)	Baseline		1st month		3rd months		P-value	P-value <sup>¥</sup>
	Mean ± SD	Range	Mean ± SD	Range	Mean ± SD	Range		
Whole image	46.5 ± 3.4	37.5–55.9	45.8 ± 3.1	38.5–51.3	45.7 ± 3.3	36.3–52.3	0.29	
Superior hemifield	46.4 ± 3.4	37.2–56.6	45.6 ± 3.2	38.1–53.5	45.3 ± 3.2	36.7–52.3	0.23	
Inferior hemifield	46.7 ± 3.5	37.9–55.2	46.0 ± 3.2	38.8–51.5	46.1 ± 3.5	35.6–52.3	0.28	
Fovea	18.7 ± 3.4	8.1–37.4	18.5 ± 5.2	9.6–28.9	18.3 ± 5.3	9.6–27.5	0.44	
Parafovea	49.1 ± 3.6	38.9–58.3	48.3 ± 3.3	39.5–54.9	48.3 ± 3.3	39.6–55.1	0.32	
Superior hemifield	48.8 ± 3.6	37.6–58.6	48.0 ± 3.5	39.3–57.1	47.8 ± 3.2	40.7–55.1	0.32	
Inferior hemifield	49.4 ± 3.7	40.2–58.1	48.7 ± 3.5	39.7–54.4	48.8 ± 3.6	38.4–55.2	0.31	
Temporal	48 ± 3.7	38.8–57.9	47.0 ± 2.9	40.0–55.1	47.3 ± 3.3	39.7–54.2	0.28	
Superior	50.1 ± 3.9	36.6–58.9	49.5 ± 4.2	40.0–60.6	49.0 ± 3.3	40.8–56.4	0.49	
Nasal	47.7 ± 4.2	38.6–59.1	47.1 ± 3.6	38.3–54.1	47.1 ± 3.7	37.4–54.7	0.45	
Inferior	50.7 ± 3.6	41.7–57.5	49.8 ± 4.0	39.7–55.8	49.8 ± 3.9	38.3–56.0	0.35	
Perifovea	51.2 ± 2.4	45.4–55.5	50.6 ± 2.8	44.6–54.9	49.8 ± 2.7	43.1–55.0	0.061	
Superior hemifield	51.2 ± 2.4	44.7–55.0	50.4 ± 2.7	45.8–55.9	49.8 ± 2.8	44.5–55.3	0.061	
Inferior hemifield	51.2 ± 2.6	44.7–56.0	50.7 ± 3.2	43.2–56.4	49.8 ± 2.9	41.8–54.7	<b>0.025*</b>	1.3 (0.024)
Temporal	47.0 ± 3.3	36.7–51.6	46.1 ± 3.6	38.9–51.1	46.0 ± 3.4	38.5–51.7	0.13	
Superior	51.9 ± 2.4	45.4–55.9	50.8 ± 2.6	46.3–56.9	49.8 ± 4.5	37.1–58.5	<b>0.01*</b>	1.3 (0.012)
Nasal	54.7 ± 2.2	51.2–58.9	54.1 ± 3.0	47.4–59.9	53.3 ± 2.6	45.8–58.6	0.07	
Inferior	51.3 ± 2.8	40.3–65.1	51.2 ± 3.2	43.0–56.3	46.0 ± 3.0	41.9–55.0	<b>0.026*</b>	1.3 (0.027)

The bold entries reflect significant *p* values

SD, standard deviation

<sup>¥</sup>Based on generalized estimating equation analysis unadjusted for the baseline

<sup>¥</sup>Pairwise comparisons were corrected for multiple measurements with Bonferroni technique

\*Statistically significant results

**Table 2** Vascular density of the deep capillary plexuses in the foveal, parafoveal, and perifoveal regions in recovered patients with COVID-19 at baseline, after 1 and 3 months

DCP VD (%)	Baseline		1st month		3rd months		P-value <sup>γ</sup>	P-value <sup>¥</sup>
	Mean ± SD	Range	Mean ± SD	Range	Mean ± SD	Range		
Whole image	54.3 ± 2.7	48.4–59.7	52.1 ± 3.8	41.3–56.3	51.4 ± 2.7	45.5–56.1	<b>0.001**</b>	1.2 (0.003) 1.3 (0.001)
Superior hemifield	54.5 ± 2.9	48.1–61.5	52.1 ± 3.7	41.8–57.1	51.3 ± 2.8	44.4–56.9	<b>&lt; 0.001**</b>	1.2 (0.001) 1.3 (0.003)
Inferior hemifield	54.1 ± 2.7	46.8–57.9	52.2 ± 3.2	40.5–56.2	51.4 ± 2.7	45.6–56.6	<b>0.002*</b>	1.2 (0.004) 1.3 (0.008)
Fovea	35.4 ± 6.0	23.2–47.1	34.8 ± 6.2	21.9–47.0	34.5 ± 6.1	22.3–48.7	0.054	
Parafovea	56.5 ± 2.8	50.9–62.7	54.3 ± 3.5	44.2–58.9	53.6 ± 2.4	47.6–58.2	<b>0.001**</b>	1.2 (0.001) 1.3 (0.003)
Superior hemifield	56.6 ± 3.0	50.1–65	54.3 ± 3.5	45.1–59.4	53.7 ± 2.5	47.6–58.8	<b>&lt; 0.001**</b>	1.2 (0.005) 1.3 (0.002)
Inferior hemifield	56.3 ± 2.9	49.8–63	54.2 ± 3.7	43.2–58.5	53.6 ± 2.5	47.5–57.9	<b>0.001**</b>	1.2 (0.001) 1.3 (0.004)
Temporal	56.4 ± 2.7	51.4–63.6	54.3 ± 3.3	45.7–58.9	53.6 ± 2.5	48.8–58.8	<b>0.001**</b>	1.2 (0.006) 1.3 (0.003)
Superior	56.8 ± 3.1	49.4–65	54.1 ± 3.5	44.6–59.1	53.2 ± 2.5	47.8–58.2	<b>&lt; 0.001**</b>	1.2 (0.001) 1.3 (< 0.001)
Nasal	56.4 ± 2.9	49.7–61.8	57.3 ± 3.8	43.2–59.3	54.2 ± 2.6	46.2–59.7	<b>0.001**</b>	1.2 (0.01) 1.3 (0.001)
Inferior	56.6 ± 5	50.2–61.3	54.2 ± 3.9	42.7–59.2	52.7 ± 4.5	45.9–57.6	<b>0.008*</b>	1.2 (0.016) 1.3 (0.023)
Perifovea	56.8 ± 6.3	39.1–65	53.7 ± 6.6	35.7–62.9	50.6 ± 5.5	39.1–61.0	<b>&lt; 0.001**</b>	1.2 (< 0.001) 1.3 (< 0.001)
Superior hemifield	57.0 ± 6.5	37.2–64.6	51.9 ± 6.1	37.1–60.6	49.5 ± 5.4	38.3–60.9	<b>&lt; 0.001**</b>	1.2 (< 0.001) 1.3 (< 0.001)
Inferior hemifield	56.5 ± 6.3	41.0–65.5	53.9 ± 6.6	34.6–63.5	50.6 ± 5.6	38.8–60.7	<b>&lt; 0.001**</b>	1.2 (< 0.001) 1.3 (< 0.001)
Temporal	58.7 ± 5.6	43.2–64.5	56.0 ± 6.2	39.2–63.5	54.2 ± 5.3	42.8–62.9	<b>&lt; 0.001**</b>	1.2 (< 0.001) 1.3 (< 0.001)
Superior	57.3 ± 7.4	35.4–65.4	53.2 ± 7.5	34.8–63.6	49.9 ± 6.4	35.8–61.5	<b>&lt; 0.001**</b>	1.2 (< 0.001) 1.3 (< 0.001)
Nasal	54.6 ± 6.9	35.4–66	51.5 ± 6.6	35.8–61.7	47.6 ± 5.4	36–60.7	<b>&lt; 0.001**</b>	1.2 (0.002) 1.3 (< 0.001)
Inferior	56.4 ± 6.9	40.3–65.1	54.2 ± 7.2	33.1–63.9	50.8 ± 6.0	38.8–61.4	<b>&lt; 0.001**</b>	1.2 (0.002) 1.3 (< 0.001)

The bold entries reflect significant *p* values

SD, standard deviation; DCP, deep capillary plexus; VD, vessel density

<sup>γ</sup>Based on generalized estimating equation analysis unadjusted for the baseline

\* and \*\*Statistically significant results

<sup>¥</sup>Pairwise comparisons were corrected for multiple measurements with Bonferroni technique

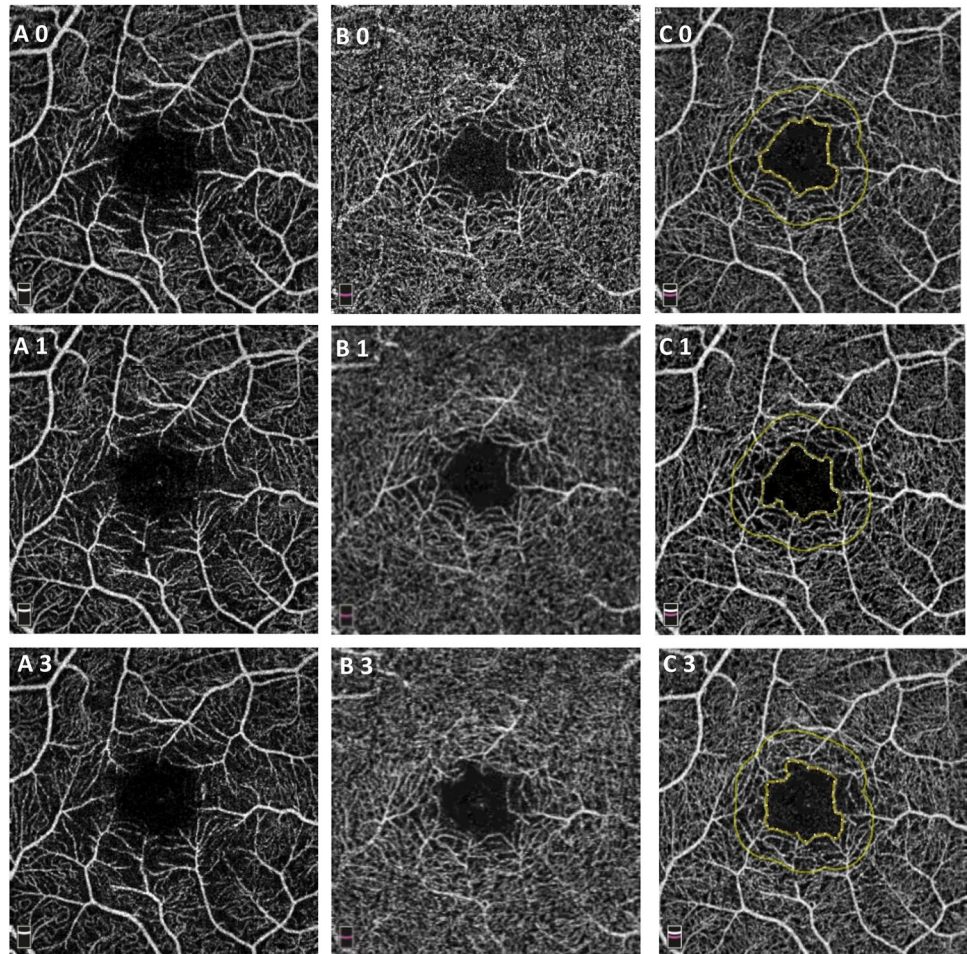
**Table 3** Measurements of the fovea avascular zone (FAZ) (including FAZ area, the perimeter circumference of the FAZ (PERIM), and foveal vessel density (FD)) in recovered patients with COVID-19 at baseline, after 1 and 3 months

	Baseline		1st month		3rd months		P-value <sup>γ</sup>
	Mean ± SD	Range	Mean ± SD	Range	Mean ± SD	Range	
FAZ (mm <sup>2</sup> )	0.27 ± 0.08	0.09–0.43	0.26 ± 0.08	0.09–0.44	0.27 ± 0.08	0.09–0.44	0.53
PERIM (mm)	2.07 ± 0.3	1.29–2.67	2.04 ± 0.33	1.29–2.87	2.06 ± 0.35	1.20–2.94	0.73
FD (%)	50.7 ± 4.2	41.5–57.1	49.91 ± 3.57	44.3–56.5	50.6 ± 3.19	45.0–56.4	0.80

FAZ fovea avascular zone, PERIM, perimeter circumference of the FAZ, FD foveal vessel density

<sup>γ</sup>Based on generalized estimating equation analysis unadjusted for the baseline

**Fig. 1** Representative OCTA images of the right eye of a 24-year-old lady at baseline, 1 and 3 months after COVID-19 initiation denoted by 0, 1, and 3. Columns A, B, and C represent superficial capillary plexus (SCP), deep capillary plexus (DCP), and foveal avascular zone (FAZ), respectively. FAZ, FD, and PERIM were 0.35 mm<sup>2</sup>, 2.57 mm, and 45.96% at baseline and reached 0.34 mm<sup>2</sup>, 2.67 mm, and 45.01% after 1 month. The corresponding values after 3 months were 0.41 mm<sup>2</sup>, 2.8 mm, and 46.9%



The results of the present study demonstrated the possibility of subclinical vascular alterations in individuals who have recovered from COVID-19 infection. Moreover, the findings were found to be associated with the severity of the COVID-19. Therefore, it is important to monitor these retinal microvasculature changes to ascertain their longitudinal course. In a longitudinal investigation, which was scarce to our knowledge, it was found that the decremental changes continue.

Notably, the persistence of these microangiopathic changes over 3 months is the most important finding of the present study. To explain the persistent changes over 3 months, several possible mechanisms could be considered, including persistent direct invasion of the virus, persistent microvascular changes, and midterm consequences of inflammation. In another study performed by Qin and associates [36], some neurological changes in the brain were persistent after 3 months in patients who had recovered from COVID-19 with no neurological manifestations upon the onset of the disease. In accordance with our findings, reduction of VDs in foveal SCP persisted after a 6-month follow-up in a study by Bilbao-Malave and associates [37].

However, the authors reported the larger superficial FAZ area in COVID-19 cohort after 6 months. The difference with our results could be attributed to the older population and severe disease in the mentioned study [37]. Furthermore, the FAZ area is reported in total SCP and DCP in the present study. Minimal changes in superficial FAZ might not be discovered in our study.

An alternative explanation for the persistence of microvascular changes could be the reperfusion after an ischemic event [38]. In patients with paracentral acute middle maculopathy [39] and experimental ischemia rat models [40], the reperfusion caused a reduction in the macular VD. COVID-19 could cause endothelial dysfunction, a shift towards the vasoconstrictive phase, and subsequent ischemic changes in the acute phase, followed by the reperfusion that could continue the reduction of VDs.

In the present study, the DCP was more prominently involved, compared to SCP. In our previous report [12], VDs in both SCP and DCP were lower than healthy controls. However, in the present study, the DCP showed more prominent changes in the COVID-19 cohort, compared to the first visit. Therefore, it could be implied that changes in DCP persist for

a longer duration. It has been previously reported that DCP is more susceptible to pathological injuries possibly due to a lower vascular endothelial resistance [41]. In patients with diabetic retinopathy [42], or systemic lupus erythematosus [39], DCP is earlier and more extensively affected, respectively. Besides the possible lower hemodynamic stability of capillaries in DCP, the close relationship between the neuronal unit might make this plexus more susceptible to injuries [43]. It has also mentioned that DCP is affected in patients with COVID-19 or vaccinated against COVID-19, as acute macular neuroretinopathy, the same as other systemic diseases with vascular impairment, like diabetes mellitus [44–46]. It should be noted that the SARS-CoV-2 virus has a tendency towards neuronal tissues [47].

This study had some limitations; first, the sample size was not large enough ( $n = 18$ ), and better results could be achieved by a larger scale OCTA longitudinal analysis and also by evaluating the symptomatic phase of the disease. Second, while this study strictly applied to a cohort of relatively young patients who had mild severity of the disease and visual acuity of 20/20, the evaluation does not represent the changes that may appear in patients in severe stages of the disease or patients who may have underlying systemic comorbidities, like diabetes mellitus. Our cohort might be considered non-random since it consisted of nurses and physicians. The short follow-up of the patients is another limitation of the present study. However, the OCTA longitudinal analysis of 18 similarly imaged patients with RT-PCR-confirmed COVID-19 is novel and can underline the significance of constant monitoring to detect the ocular and retinal complications secondary to COVID-19 as the pandemic develops.

In conclusion, the results of the present research displayed significant retinal vascular changes in patients with a history of COVID-19, such as reduced vessel density in the SCP and DCP in the perifoveal and parafoveal regions in a longitudinal cohort of patients. Further research should be carried out on the possible involvement of the retina by COVID-19 on larger scales to represent the increasing number of people with COVID-19 around the world. The involvement of retinal blood vessels can also indicate similar changes in the vascular system of other organs during COVID-19 infection.

**Acknowledgements** The authors would like to express their gratitude to Maryam Kadkhoda BSc, Sepideh Nazari Noghahi MSc, Roghaye Kahani BSc, and Roya Gholamzadeh BSc, retinal imaging operators of Khatam-al-Anbia Eye Hospital, Mashhad, Iran. It is a pleasure for us to also acknowledge the kind supports of Capt. Mehdi Jafarzade.

**Author contribution** Mojtaba Abrishami, S Maryam Hosseini, and Majid Abrishami contributed to the study conception, methodology, and design. Material preparation and data collection were performed by Mojtaba Abrishami, Zahra Emamverdian, Mohammad-Reza Ansari-Astaneh, and Ghodsieh Zamani. Statistical analysis was performed by Kiana Hassanpour and Bahareh Gharib. The first draft of the

manuscript was written by Kiana Hassanpour and Mojtaba Abrishami. All authors commented on previous versions of the manuscript. All authors read and approved the final manuscript.

**Funding** This research project received financial support of the Vice-Chancellor of Research of Mashhad University of Medical Sciences (code:990823). The funding organization had no role in the design or conduct of this research.

**Data availability** The datasets generated and analyzed during the current study are available from the corresponding author on reasonable request.

## Declarations

**Ethics approval** The study protocol adhered to the tenets of the Declaration of Helsinki. All participants provided written informed consent before enrollment, and the ethical aspects of the study were approved by the Regional Committee on Medical Ethics at Mashhad University of Medical Sciences, Mashhad, Iran (IR.MUMS.MEDICAL.REC.1399.402).

**Conflict of interest** The authors declare no competing interests.

## References

1. Singh SP, Pritam M, Pandey B et al (2021) Microstructure, pathophysiology, and potential therapeutics of COVID-19: a comprehensive review. *J Med Virol* 93:275–299
2. Wiersinga WJ, Rhodes A, Cheng AC et al (2020) Pathophysiology, transmission, diagnosis, and treatment of coronavirus disease 2019 (COVID-19): a review. *JAMA* 324:782–793
3. Gheblawi M, Wang K, Viveiros A et al (2020) Angiotensin-converting enzyme 2: SARS-CoV-2 receptor and regulator of the renin-angiotensin system: celebrating the 20th anniversary of the discovery of ACE2. *Circ Res* 126:1456–1474
4. Choudhary R, Kapoor MS, Singh A et al (2017) Therapeutic targets of renin-angiotensin system in ocular disorders. *Journal of current ophthalmology* 29:7–16
5. Abrishami M, Tohidinezhad F, Daneshvar R et al (2020) Ocular manifestations of hospitalized patients with COVID-19 in north-east of Iran. *Ocul Immunol Inflamm* 28:739–744
6. Olson DJ, Ghosh A, Zhang AY (2020) Ophthalmic manifestations of coronavirus disease 2019 and ocular side effects of investigational pharmacologic agents. *Curr Opin Ophthalmol* 31:403–415
7. Abrishami M, Daneshvar R, Emamverdian Z et al (2021) Optic nerve head parameters and peripapillary retinal nerve fiber layer thickness in patients with coronavirus disease 2019. *Ocular Immunol Inflamm*: 1–4. <https://doi.org/10.1080/09273948.2020.1850800>
8. Conrady CD, Faia LJ, Gregg KS et al (2021) Coronavirus-19-associated retinopathy. *Ocular Immunol Inflamm*: 1–2. <https://doi.org/10.1080/09273948.2020.1850800>
9. Hosseini SM, Abrishami M, Zamani G et al (2021) Acute bilateral neuroretinitis and panuveitis in a patient with coronavirus disease 2019: a case report. *Ocular Immunol Inflamm*: 1–4. <https://doi.org/10.1080/09273948.2021.1894457>
10. Ortiz-Seller A, Martínez Costa L, Hernández-Pons A et al (2020) Ophthalmic and neuro-ophthalmic manifestations of coronavirus disease 2019 (COVID-19). *Ocul Immunol Inflamm* 28:1285–1289
11. Tisdale AK, Chwalisz BK (2020) Neuro-ophthalmic manifestations of coronavirus disease 19. *Curr Opin Ophthalmol* 31:489–494

12. Abrishami M, Emamverdian Z, Shoeibi N et al (2021) Optical coherence tomography angiography analysis of the retina in patients recovered from COVID-19: a case-control study. *Can J Ophthalmol* 56:24–30
13. González-Zamora J, Bilbao-Malavé V, Gándara E et al (2021) Retinal microvascular impairment in COVID-19 bilateral pneumonia assessed by optical coherence tomography angiography. *Biomedicines* 9:247
14. Hazar L, Karahan M, Vural E et al (2021) Macular vessel density in patients recovered from COVID 19. *Photodiagn Photodyn Ther* 34:102267
15. Turker IC, Dogan CU, Guven D et al (2021) Optical coherence tomography angiography findings in patients with COVID-19. *Can J Ophthalmol* 56(2):83–87
16. Zapata MÁ, Banderas García S, Sánchez-Moltalvá A et al (2020) Retinal microvascular abnormalities in patients after COVID-19 depending on disease severity [published online ahead of print, 2020 Dec 16]. *Br J Ophthalmol*. 2020;bjophthalmol-2020-317953. <https://doi.org/10.1136/bjophthalmol-2020-317953>
17. Casagrande M, Fitzek A, Püschel K et al (2020) Detection of SARS-CoV-2 in human retinal biopsies of deceased COVID-19 patients. *Ocul Immunol Inflamm* 28:721–725
18. Casagrande M, Fitzek A, Spitzer M et al (2020) Detection of SARS-CoV-2 genomic and subgenomic RNA in retina and optic nerve of patients with COVID-19. *Br J Ophthalmol* 2021;bjophthalmol-2020-318618. <https://doi.org/10.1136/bjophthalmol-2020-318618>
19. Karimi S, Arabi A, Shahraki T et al (2020) Detection of severe acute respiratory syndrome coronavirus-2 in the tears of patients with coronavirus disease 2019. *Eye* 34:1220–1223
20. Seah I, Agrawal R (2020) Can the coronavirus disease 2019 (COVID-19) affect the eyes? A review of coronaviruses and ocular implications in humans and animals. *Ocul Immunol Inflamm* 28:391–395
21. Magro C, Mulvey JJ, Berlin D et al (2020) Complement associated microvascular injury and thrombosis in the pathogenesis of severe COVID-19 infection: a report of five cases. *Transl Res* 220:1–13
22. Iba T, Connors JM, Levy JH (2020) The coagulopathy, endotheliopathy, and vasculitis of COVID-19. *Inflamm Res* 69(12):1181–1189. <https://doi.org/10.1007/s00011-020-01401-6>
23. Varga Z, Flammer AJ, Steiger P et al (2020) Endothelial cell infection and endotheliitis in COVID-19. *The Lancet* 395:1417–1418
24. Hagag AM, Pechauer AD, Liu L et al (2018) OCT angiography changes in the 3 parafoveal retinal plexuses in response to hyperoxia. *Ophthalmology Retina* 2:329–336
25. Xu H, Deng G, Jiang C et al (2016) Microcirculatory responses to hyperoxia in macular and peripapillary regions. *Invest Ophthalmol Vis Sci* 57:4464–4468
26. Nalugo M, Schulte LJ, Masood MF et al (2021) Microvascular angiopathic consequences of COVID-19. *Frontiers in Cardiovascular Medicine* 8:26
27. Marinho PM, Marcos AA, Romano AC et al (2020) Retinal findings in patients with COVID-19. *Lancet* 395:1610
28. Vavvas DG, Sarraf D, Sadda SR et al (2020) Concerns about the interpretation of OCT and fundus findings in COVID-19 patients in recent Lancet publication. *Eye (Lond)* 34(12):2153–2154. <https://doi.org/10.1038/s41433-020-1084-9>
29. Gaba WH, Ahmed D, Al Nuaimi RK et al (2020) Bilateral central retinal vein occlusion in a 40-year-old man with severe coronavirus disease 2019 (COVID-19) pneumonia. *The American Journal of Case Reports* 21:e927691-927691
30. Gascon P, Briantais A, Bertrand E et al (2020) Covid-19-associated retinopathy: a case report. *Ocul Immunol Inflamm* 28:1293–1297
31. Pereira LA, Soares LCM, Nascimento PA et al (2020) Retinal findings in hospitalised patients with severe COVID-19. *Br J Ophthalmol*. 2020;bjophthalmol-2020-317576. <https://doi.org/10.1136/bjophthalmol-2020-317576>
32. Lee M-H, Perl DP, Nair G et al (2020) Microvascular injury in the brains of patients with Covid-19. *N Engl J Med* 384:481–483. <https://doi.org/10.1056/NEJMc2033369>
33. Keshavarz P, Rafiee F, Kavandi H et al (2021) Ischemic gastrointestinal complications of COVID-19: a systematic review on imaging presentation. *Clin Imaging* 73:86–95. <https://doi.org/10.1016/j.clinimag.2020.11.054>
34. Maccio U, Zinkernagel AS, Shambat SM et al (2021) SARS-CoV-2 leads to a small vessel endotheliitis in the heart. *EBioMedicine* 63:103182. <https://doi.org/10.1016/j.ebiom.2020.103182>
35. Su H, Yang M, Wan C et al (2020) Renal histopathological analysis of 26 postmortem findings of patients with COVID-19 in China. *Kidney Int* 98:219–227. <https://doi.org/10.1016/j.kint.2020.04.003>
36. Qin Y, Wu J, Chen T et al (2021) Long-term microstructure and cerebral blood flow changes in patients recovered from COVID-19 without neurological manifestations. *J Clin Investig* 131(8):e147329
37. Bilbao-Malavé V, González-Zamora J, Saenz de Viteri M et al (2021) Persistent retinal microvascular impairment in COVID-19 bilateral pneumonia at 6-months follow-up assessed by optical coherence tomography angiography. *Biomedicines* 9:502
38. Zheng L, Gong B, Hatala DA et al (2007) Retinal ischemia and reperfusion causes capillary degeneration: similarities to diabetes. *Invest Ophthalmol Vis Sci* 48:361–367
39. Arfeen SA, Bahgat N, Adel N et al (2020) Assessment of superficial and deep retinal vessel density in systemic lupus erythematosus patients using optical coherence tomography angiography. *Graefes Arch Clin Exp Ophthalmol* 258(6):1261–1268. <https://doi.org/10.1007/s00417-020-04626-7>
40. Nakahara T, Hoshino M, Hoshino S-i et al (2015) Structural and functional changes in retinal vasculature induced by retinal ischemia-reperfusion in rats. *Exp Eye Res* 135:134–145
41. Campbell J, Zhang M, Hwang T et al (2017) Detailed vascular anatomy of the human retina by projection-resolved optical coherence tomography angiography. *Sci Rep* 7:1–11
42. Ashraf M, Sampani K, Clermont A et al (2020) Vascular density of deep, intermediate and superficial vascular plexuses are differentially affected by diabetic retinopathy severity. *Invest Ophthalmol Vis Sci* 61:53–53. <https://doi.org/10.1167/iovs.61.10.53>
43. Usui Y, Westenskow PD, Kurihara T et al (2015) Neurovascular crosstalk between interneurons and capillaries is required for vision. *J Clin Investig* 125:2335–2346
44. Book BAJ, Schmidt B, Foerster AMH (2021) Bilateral acute macular neuroretinopathy after vaccination against SARS-CoV-2. *JAMA Ophthalmol* 139(7):e212471
45. Zamani G, AtaeiAzimi S, Aminzadeh A et al (2021) Acute macular neuroretinopathy in a patient with acute myeloid leukemia and deceased by COVID-19: a case report. *J Ophthalmic Inflamm Infect* 10(1):39
46. Bhavsar KV, Lin S, Rahimy E et al (2016) Acute macular neuroretinopathy: a comprehensive review of the literature. *Surv Ophthalmol* 61(5):538–565
47. Baig AM, Khaleeq A, Ali U et al (2020) Evidence of the COVID-19 virus targeting the CNS: tissue distribution, host–virus interaction, and proposed neurotropic mechanisms. *ACS Chem Neurosci* 11:995–998. <https://doi.org/10.1021/acscchemneuro.0c00122>

**Publisher's note** Springer Nature remains neutral with regard to jurisdictional claims in published maps and institutional affiliations.



## Authors and Affiliations

Mojtaba Abrishami<sup>1,2</sup>  · Kiana Hassanpour<sup>3</sup> · SeyedehMaryam Hosseini<sup>1</sup> · Zahra Emamverdian<sup>1</sup> · Mohammad-Reza Ansari-Astaneh<sup>1</sup> · Ghodsieh Zamani<sup>1</sup> · Bahareh Gharib<sup>1</sup> · Majid Abrishami<sup>1</sup>

<sup>1</sup> Eye Research Center, Mashhad University of Medical Sciences, Mashhad, Iran

<sup>2</sup> Eye Research Center, Khatam-al-Anbia Eye Hospital, Qarani Blvd, Mashhad 9195965919, Iran

<sup>3</sup> Ophthalmic Research Center, Research Institute for Ophthalmology and Vision Science, Shahid Beheshti University of Medical Sciences, Tehran, Iran