



Strongyloides stercoralis

Jonathan M. Czeresnia¹ · Louis M. Weiss^{2,3}

Received: 18 November 2021 / Accepted: 18 March 2022 / Published online: 9 April 2022
© The Author(s), under exclusive licence to Springer Science+Business Media, LLC, part of Springer Nature 2022

Abstract

Strongyloidiasis has been estimated to affect over 600 million people worldwide. It is caused by *Strongyloides stercoralis*, a roundworm endemic to the tropics and subtropics, especially areas where sanitation is suboptimal. Autochthonous transmission has been documented in rural areas of the USA and Europe. Humans are infected when larvae penetrate the skin or are ingested. Autoinfection, in which larvae generated in the host go on to re-infect the host, leads to a state of chronic asymptomatic infection often with eosinophilia. Hyperinfection syndrome may develop when patients develop immune suppression, due to medications such as corticosteroids or following solid-organ transplantation. Hyperinfection is characterized by exponential increase in parasitic burden, leading to tissue invasion and life-threatening disease and associated bloodstream infections due to enteric organisms. Cases following use of corticosteroids for COVID-19 pneumonia have been described. Strongyloidiasis can be diagnosed by direct visualization of larvae in stool or other body fluids, or by serology. Ivermectin is highly effective in treating the disease. Patients with exposure to endemic areas and those expected to become immune suppressed should be screened and treated before starting immune suppressive agents. Empiric treatment should be considered when timely testing is not readily available.

Keywords Strongyloidiasis · Hyperinfection · Immunosuppression · Treatment · Diagnosis · Ivermectin

Introduction

Strongyloides stercoralis is a roundworm (nematode) that causes the disease known as strongyloidiasis. It has been estimated to affect over 600 million people worldwide [1], and is of particular clinical importance due to its ability to cause chronic infection that can become life-threatening in the setting of immunosuppression. Though *S. fuelleborni* and some other zoonotic species have been implicated as human pathogens, they are of minor medical relevance [2]. This review will focus on the epidemiology, basic

parasitology, presentation, diagnosis, and management of *S. stercoralis* infection.

Epidemiology

Strongyloides stercoralis is endemic worldwide, but is most prevalent in tropical and subtropical climates, especially in areas with inadequate sanitary conditions. Community-based studies have estimated a prevalence of over 70% in countries such as Peru, Kenya, Namibia, and Papua New Guinea. In the USA and Europe the majority of cases are considered imported, though local transmission has been reported mainly in rural areas. A recent prospective study that enrolled patients in *Cataluña* (Spain) from 2003 to 2012 found seventy cases of strongyloidiasis, diagnosed either by serologic testing, or by sputum or fecal parasitology. Of these, 59% were considered to have originated in South America and the Caribbean, 26% in sub-Saharan Africa, 13% in Southeast Asia, and only 3% were considered autochthonous [3]. Infection with human immunodeficiency virus (HIV), human T-lympho-tropic virus 1 (HTLV-1), hypogammaglobulinemia, alcoholism,

✉ Louis M. Weiss
louis.weiss@einsteinmed.edu

Jonathan M. Czeresnia
jmamercze@montefiore.org

¹ Division of Infectious Diseases, Department of Medicine, Montefiore Medical Center/Albert Einstein College of Medicine, Bronx, NY, USA

² Department of Pathology, Albert Einstein College of Medicine, Bronx, NY, USA

³ Division of Infectious Diseases, Department of Medicine, Albert Einstein College of Medicine, Bronx, NY, USA

and malnutrition have been associated with an increased risk of strongyloidiasis [4, 5]. Institutionalized patients also seem to be more commonly affected [6]. In the USA, a seroprevalence as high as 4% has been documented in areas of rural Kentucky, with most cases occurring in American-born patients that had not traveled to endemic areas [7]. Statistical modeling has suggested that up to 16 states are at high risk of local transmission [8].

Transmission

The lifecycle of *S. stercoralis* is summarized in Fig. 1. *S. stercoralis* most commonly infects humans through the cutaneous route. Filariform larvae can be found in soil and penetrate the skin of people who go barefoot, which presents as “ground itch”. After penetration, filariform larvae migrate to the lungs, where they mature, are coughed up, and swallowed. When in the small intestine, the larvae mature into adult females, which in turn intermittently produce eggs through asexual reproduction. These then hatch into rhabditiform larvae, which are excreted in stool. The rhabditiform

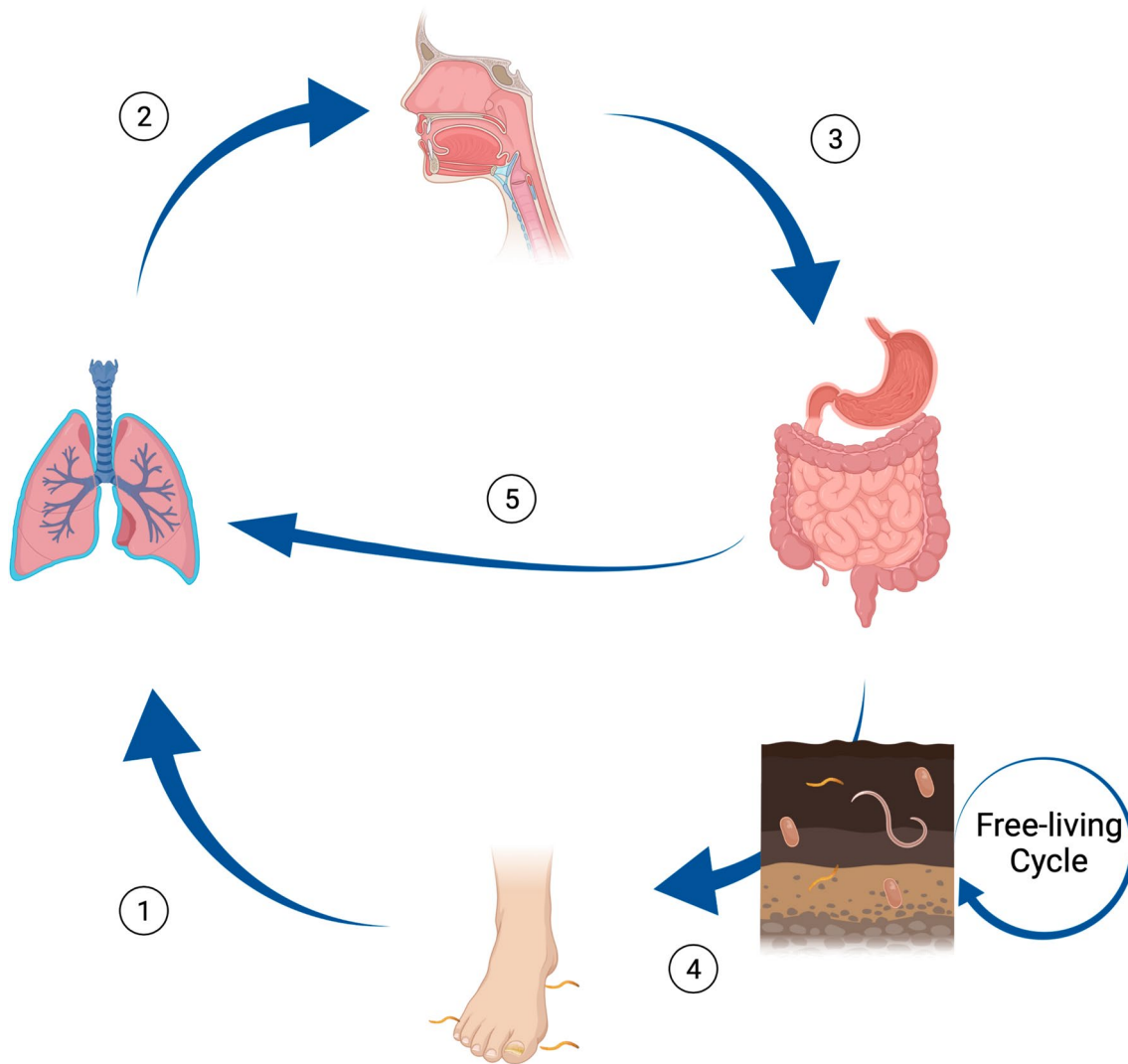


Fig. 1 Lifecycle of *S. stercoralis*. (1) Filariform larvae penetrate the host's skin and migrate to pulmonary parenchyma. (2) Filariform larvae are coughed up and swallowed. (3) Filariform larvae migrate to small intestine and lay eggs, which hatch into rhabditiform larvae. (4) Rhabditiform larvae are excreted in soil and give rise to infectious filariform larvae, which are able to penetrate skin and restart

the cycle. *S. stercoralis* also has a free-living life cycle, independent of human hosts. (5) Rhabditiform larvae may give rise to infectious filariform larvae in the host itself, leading to invasion of intestinal mucosa and/or perianal skin, process known as autoinfection. In the right host, this may lead to hyperinfection syndrome. Figure created with Biorender

larvae, which are non-infectious, then give rise to the infectious filariform larvae, either in soil or in the own host's intestine. The latter causes the unique phenomenon of autoinfection, in which filariform larvae generated in the host itself invade intestinal mucosa or perianal skin and restart the infectious cycle [9], which in turn leads to a chronic and frequently subclinical infection. Primary infection can also occur by ingestion of the filariform larvae, either by consumption of contaminated food or water, or sexually, by anal–oral contact [10]. In people with delayed fecal transport, autoinfection can be significant and cause large worm burdens. In those where fecal soilage of the skin occurs for prolonged periods of time, penetration of filariform larvae can cause local irritation as well as autoinfection. Cases of

transmission following kidney transplantation have also been reported [11].

Clinical Spectrum of Disease

Strongyloidiasis occurs in three forms: acute, caused by primary parasitic invasion; chronic, caused by autoinfection; and hyperinfection, which typically occurs in the setting of immunosuppression. Table 1 further outlines the wide array of manifestations that have been described in this disease. The most common pulmonary manifestations of strongyloidiasis are transient pulmonary opacities with cough, dyspnea, and bronchospasm often with associated pulmonary and

Table 1 Presentation, diagnosis, and management *S. stercoralis* infection

Phase	Host	Presentation	Diagnosis	Management
Acute strongyloidiasis	Recent exposure to endemic area	<i>Larva currens</i> Loeffler-like syndrome Heartburn Anorexia Abdominal pain Constipation Diarrhea	Stool positive 3 to 4 weeks after initial infection Multiple samples may be required to obtain diagnosis Limited utility of serology, typically negative	Single or multiple dose ivermectin 200 µg/kg
Chronic strongyloidiasis	Remote exposure to endemic area	Often asymptomatic May cause intermittent nausea/vomiting, diarrhea, constipation, abdominal pain Pruritus ani Urticaria Recurrent asthma Eosinophilia	Stool positive (multiple samples required may be required for diagnosis) Serology positive	Single or multiple dose ivermectin 200 µg/kg
Strongyloides hyperinfection syndrome	Remote exposure to endemic area and: Immunosuppression (corticosteroids, chemotherapy) Bone marrow transplant Solid-organ transplant Human T-Lymphotropic virus 1 (HTLV-1) infection Hypogammaglobulinemia (associated with nephrotic syndrome and multiple myeloma) Hematologic malignancies	<i>General</i> Fever, chills, fatigue Eosinophilia in early stages (occasionally seen) Eosinopenia in later stages (commonly seen) Bacteremia/fungemia with enteric flora (often recurrent) <i>Central nervous system</i> Meningitis caused by enteric flora <i>Cardiopulmonary</i> Cough, wheezing, chest pain, pneumonia, recurrent asthma <i>Gastrointestinal</i> Abdominal pain, nausea/vomiting, diarrhea, constipation, ileus <i>Other</i> <i>Larva currens</i> , Pruritus ani Larval invasion of other organs (liver, pancreas, kidneys, etc.) described	Identification of larvae in bodily fluids [e.g., sputum or bronchoalveolar lavage (BAL)] Serology positive	Ivermectin 200 µg/kg/day until stool is negative (minimum 14 days) Consider rectal and subcutaneous ivermectin in severe cases or when unable to tolerate oral medications

peripheral eosinophilia. Chest radiographs range from being normal to showing bilateral opacities. Other manifestations that have been reported include lobar infiltrates, interstitial infiltrates, and abscess/cavitation. Strongyloidiasis may cause asthma with improvement of asthma occurring following treatment of this infection. Patients with chronic obstructive pulmonary disease (COPD) or asthma from endemic regions should be screened for strongyloidiasis, especially before starting steroids which could trigger a hyperinfection syndrome.

Acute Strongyloidiasis

Acute strongyloidiasis is typically oligosymptomatic. Larval skin invasion usually occurs in the feet and may cause a serpiginous trail of dermatitis known as *larva currens* (“running larvae”), similar to what occurs in toxocariasis. Though pulmonary migration of larvae may cause a Loeffler-like syndrome, it is less frequent than that classically described in ascariasis [12]. Symptoms of asthma, peripheral eosinophilia, and pulmonary infiltrates on chest imaging may develop in this stage. Upper gastrointestinal symptoms, such as heartburn and bloating are commonly reported. Diarrhea and malabsorption are less frequent [13].

Chronic Strongyloidiasis

Chronic strongyloidiasis is mostly asymptomatic. It is most frequently diagnosed during workup of peripheral eosinophilia, which tends to decrease steadily following initial exposure [3]. Serology for strongyloidiasis can be used to screen for asymptomatic chronic infection. Symptomatic patients can intermittently experience dyspnea, wheezing, diarrhea, abdominal pain, constipation, vomiting, weight loss, urticaria, and/or *larva currens* [3, 6, 14, 15]. Migration of larvae through the lung parenchyma can cause a foreign body reaction, inflammatory pneumonitis, and pulmonary hemorrhage [16]. Rarer manifestations of chronic infection include reactive arthritis, chronic malabsorption, nephrotic syndrome, duodenal obstruction, and hepatic lesions.

Strongyloides Hyperinfection Syndrome

Strongyloides hyperinfection syndrome typically occurs when patients with chronic infection become immunosuppressed, leading to a dramatic increase in the rate of autoinfection and consequently, in parasitic burden [17]. Dissemination of larvae throughout tissues causes direct damage. Disruption of the intestinal membrane predisposes to bacteremia caused by intestinal flora. It has been suggested that the migrating larvae may also carry bacteria from the gastrointestinal tract to the lung and other organs. Though presentation is highly variable, classically strongyloides

hyperinfection syndrome manifests by recurrent unexplained enterobacterial bloodstream infections, which can be polymicrobial and seed to unusual sites such as the meninges [12]. The lung is an important target organ in hyperinfection with the usual presentation being pneumonia and cough from the migrating filiform larvae in the pulmonary parenchyma. Eosinophilia is usually not seen due to steroids being the precipitating factor in the majority of cases of strongyloides hyperinfection syndrome. Chest radiographs typically show bilateral infiltrates which can be interstitial or parenchymal; however focal lobar infiltrates are also reported to occur. Hemoptysis and respiratory failure can be seen. Hyperinfection often presents with significant gastrointestinal symptoms including abdominal pain, nausea, vomiting, and ileus. The mortality of untreated strongyloides hyperinfection syndrome varies from 85 to 100% [18].

Use of corticosteroids is the most common trigger for strongyloides hyperinfection syndrome [17] and has been reported with courses as short as 6 days [19] and doses as low as 20 mg of prednisone/day [20]. Unsurprisingly, multiple cases of strongyloides hyperinfection syndrome following use of corticosteroids in the management of COVID-19 pneumonia have been reported [21, 22]. A variety of other immunosuppressive medications, such as rituximab, mycophenolate mofetil, antithymocyte globulin, and antineoplastic agents such as adriamycin, doxorubicin, and melphalan have also been implicated in strongyloides hyperinfection syndrome. Infection with HTLV-1, hypogammaglobulinemia (associated with nephrotic syndrome and multiple myeloma), hematologic malignancies, solid-organ and hematopoietic stem cell transplantation have also been associated with strongyloides hyperinfection syndrome [18]. Though initially considered an AIDS (acquired immunodeficiency syndrome) defining illness, a relatively small number of cases of strongyloides hyperinfection syndrome associated with HIV have been reported, and most of them have occurred following use of corticosteroids for conditions such as *Pneumocystis pneumonia* [23–25]. Strongyloides hyperinfection syndrome has been seen occasionally in immune competent individuals without other significant risk factors, for example, cases have been seen following laparoscopic surgery [26, 27]. It is thought that hypomotility of the gastrointestinal tract, i.e., prolonged transit time of stool, probably permits conversion of a higher numbers of rhabditiform larvae into infectious filariform larvae facilitating hyperinfection.

Immunopathogenesis

The innate immune response to *S. stercoralis* is mediated by eosinophils, granulocytes, and macrophages [28–30]. Larval killing by eosinophils depends on eosinophil major

basic protein, and by granulocytes on myeloperoxidase [31]. Both cell types rely on complement-mediated mechanisms for killing [32]. Though classically not thought of as antigen-presenting cells, eosinophils have been shown to be able to act as such in animal models of strongyloidiasis [33]. The adaptive immune response to *S. stercoralis* is typically Th2-skewed, with interleukin (IL)-5 leading to further recruitment and activation of eosinophils, and IL-4 and IL-5 promoting class switch of immunoglobulins secreted by B cells to IgEs [34]. IL-13 causes increased peristalsis, possibly leading to increased larval expulsion [35]. Expression of regulatory T-cells (T-reg) appears to be important in the pathogenesis of hyperinfection, i.e., increased numbers of T-regs lead to decreased levels of IL-5 and IgE, and presumably impaired larval killing [36]. In HTLV-1 co-infected patients, T-reg expression is increased and is thought to contribute to the higher frequency of hyperinfection in this population [37].

Diagnosis

Strongyloidiasis should be suspected in any patient with unexplained eosinophilia especially if they have had epidemiologic exposure in areas of high disease prevalence. There is also a role for screening patients thought to be at increased risk of developing hyperinfection, such as those undergoing transplantation [38] or starting medications, such as corticosteroids, that have been implicated in strongyloides hyperinfection syndrome [39]. Screening should also be considered in those with evidence of infection with HTLV-1 [18]. Screening prior to use of corticosteroids can involve both parasitological and serological assays.

Parasitological Testing

Direct visualization of larvae is the gold-standard for diagnosis of strongyloidiasis. Sensitivity of single specimen stool microscopy is as low as 21% [40]. This is thought to be due to intermittent parasite shedding and low infectious burden. Examination of multiple specimens obtained on different dates increases sensitivity, which approaches 100% when seven samples are sent [41]. Parasitological techniques such as the modified agar plate method and the Baermann technique can be used to improve diagnostic yield, but they are seldom performed in most parasitology labs [42]. Real-time polymerase chain reaction (PCR) has been used for diagnosis of strongyloidiasis, but estimates of sensitivity of this method vary greatly and the nucleic acid probes are not yet easily available [42]. In cases of hyperinfection, the large number of worms make detection less challenging: larvae can be seen in preparations of sputum, bronchoalveolar or

gastric lavage, urine, blood, and even in lung or gastrointestinal biopsies [42].

Serologic Testing

There are several commercially available serologic tests for strongyloidiasis. Though it is challenging to estimate sensitivity and specificity of these tests, as cases of chronic strongyloidiasis have low parasitic burden, which in turn decreases the sensitivity of fecal tests used as gold-standards, the negative predictive value of serology in immigrants in low prevalence settings approaches 100% [43]. The same is not true for recently acquired infections (e.g., returning traveler), in which the negative predictive value of serological screening was found to be only 72% [44]. In these cases, a negative serology is not sufficient to rule out infection and clinicians should consider stool examination and paired serologic testing if clinical suspicion is high. Cross-reactivity with other parasites such as hookworms, ascariis, and filaria has been well described, though this appears to be less of a concern in more modern test kits [45].

Management

Clinical trials of drugs for treatment of strongyloidiasis have mostly focused on the treatment of chronic infection, not on strongyloides hyperinfection syndrome. Ivermectin, a broad-spectrum antiparasitic that causes muscle paralysis in invertebrates, has emerged as the treatment of choice for strongyloidiasis. It is better tolerated than and has similar efficacy than the previously recommended drug thiabendazole [46] and is more effective in achieving larval clearance when compared to albendazole [47]. For uncomplicated *S. stercoralis* infections, the usual treatment in the USA is oral ivermectin 200 µg/kg/day for two consecutive days. Some experts recommend repeating the course after 2 weeks to account for the parasite's autoinfectious cycle [48]. However, in a randomized clinical trial, single-dose ivermectin has been shown to have similar efficacy to multiple-dose regimens [49, 50]. The same treatment recommendation as used for uncomplicated *S. stercoralis* infection applies to patients found to have positive serology during screening, though it is important to note that the use of comparative antibody titers as markers of parasitic eradication following treatment has not been adequately evaluated. Moreover, characteristics of different serology techniques vary greatly, and laboratory protocols are not standardized [45]. Due to the high cost and long turn-around times of tests for *S. stercoralis* and the safe profile of ivermectin, some experts suggest empiric treatment in patients considered to be at high risk [18].

Though there is a lack of high-quality evidence for treatment of cases of hyperinfection, experts suggest that

ivermectin should be given daily at 200 µg/kg/day for at least two weeks. Ideally, treatment should be extended until no more larvae are found in stool specimens. Reduction in immunosuppressive regimens should be considered in cases where the risks of strongyloides hyperinfection syndrome outweigh the benefits of immunosuppression. In cases where oral administration is not possible, or when intestinal absorption of ivermectin is thought to be impaired, alternative routes of administration may be considered. Though not approved by the US Food and Drug Administration (FDA), rectal administration of ivermectin (200 µg/kg/day) has been reported as successful. Parenteral (subcutaneous) ivermectin, only available in veterinary formulations, should be reserved as a last resort [18]. There have also been reports of successful treatment with the addition of albendazole (400 mg orally twice a day) to ivermectin [51]. Additionally, patients with strongyloides hyperinfection syndrome should be considered infectious and placed on standard contact precautions [18].

Though there have been reports of cases of severe toxicities following use of high-dose ivermectin inappropriately used to treat COVID-19, the drug is generally well-tolerated when given in recommended doses. Use should be avoided in patients with *Loa loa*, a filarial disease endemic to West Africa, as it has been associated development of encephalopathy [52]. Albendazole is a possible alternative for the management of these co-infection cases. Moxidectin has shown efficacy for the treatment of strongyloides infections in a phase 2 clinical trials and is a promising addition to the armamentarium for this infection [53, 54].

Conclusion

Although infection with *S. stercoralis* is frequently asymptomatic, it has the potential of causing life-threatening disease in the immunocompromised. Ivermectin is a well-tolerated and highly efficacious drug for treatment of strongyloidiasis. As such, screening and adequate treatment of at-risk populations, especially the immunocompromised and those receiving immunosuppressive agents such as corticosteroids, is paramount in avoiding the devastating hyperinfection syndrome. When screening is not feasible, empiric treatment of these patients should be strongly considered.

Author contributions All authors contributed to the preparation and editing of this article (JMC wrote the initial draft, LMW edited and revised this draft).

Funding The authors declare that no funds, grants, or other support were received that supported the preparation of this manuscript.

Declarations

Conflict of interest The authors declare that they have no relevant financial or non-financial interests to disclose.

Ethical Approval This manuscript does not involve research with human or animal subjects.

References

- Buonfrate D, Bisanzio D, Giorli G, Odermatt P, Furst T, Greenaway C et al (2020) The global prevalence of *Strongyloides stercoralis* Infection. *Pathogens* 9(6):468
- Nutman TB (2017) Human infection with *Strongyloides stercoralis* and other related Strongyloides species. *Parasitology* 144(3):263–273
- Valerio L, Roure S, Fernandez-Rivas G, Basile L, Martinez-Cuevas O, Ballesteros AL et al (2013) *Strongyloides stercoralis*, the hidden worm. Epidemiological and clinical characteristics of 70 cases diagnosed in the North Metropolitan Area of Barcelona, Spain, 2003–2012. *Trans R Soc Trop Med Hyg* 107(8):465–470
- Schar F, Trostorf U, Giardina F, Khieu V, Muth S, Marti H et al (2013) *Strongyloides stercoralis*: global distribution and risk factors. *PLoS Negl Trop Dis* 7(7):e2288
- Scowden EB, Schaffner W, Stone WJ (1978) Overwhelming strongyloidiasis: an unappreciated opportunistic infection. *Medicine (Baltimore)* 57(6):527–544
- Berk SL, Verghese A, Alvarez S, Hall K, Smith B (1987) Clinical and epidemiologic features of strongyloidiasis. A prospective study in rural Tennessee. *Arch Intern Med* 147(7):1257–1261
- Russell ES, Gray EB, Marshall RE, Davis S, Beaudoin A, Handali S et al (2014) Prevalence of *Strongyloides stercoralis* antibodies among a rural Appalachian population—Kentucky, 2013. *Am J Trop Med Hyg* 91(5):1000–1001
- Singer R, Sarkar S (2020) Modeling strongyloidiasis risk in the United States. *Int J Infect Dis* 100:366–372
- Mehlhorn H (2008) *Encyclopedia of parasitology*, 3rd edn. Springer, New York
- Sorvillo F, Mori K, Sewake W, Fishman L (1983) Sexual transmission of *Strongyloides stercoralis* among homosexual men. *Br J Vener Dis* 59(5):342
- Hamilton KW, Abt PL, Rosenbach MA, Bleicher MB, Levine MS, Mehta J et al (2011) Donor-derived *Strongyloides stercoralis* infections in renal transplant recipients. *Transplantation* 91(9):1019–1024
- Bennett JE, Dolin R, Blaser MJ (2019) *Mandell, Douglas, and Bennett's principles and practice of infectious diseases*, 9th edn. Elsevier, Philadelphia
- Mokhlesi B, Shulzhenko O, Garimella PS, Kuma L, Monti C (2004) Pulmonary Strongyloidiasis: the varied clinical presentations. *Clin Pulm Med* 11(1):6–13
- Nwokolo C, Imohiosen EA (1973) Strongyloidiasis of respiratory tract presenting as “asthma.” *Br Med J* 2(5859):153–154
- Pelletier LL Jr., Gabre-Kidan T (1985) Chronic strongyloidiasis in Vietnam veterans. *Am J Med* 78(1):139–140
- Woodring JH, Halfhill H 2nd, Reed JC (1994) Pulmonary strongyloidiasis: clinical and imaging features. *AJR Am J Roentgenol* 162(3):537–542
- Keiser PB, Nutman TB (2004) *Strongyloides stercoralis* in the immunocompromised population. *Clin Microbiol Rev* 17(1):208–217

18. Mejia R, Nutman TB (2012) Screening, prevention, and treatment for hyperinfection syndrome and disseminated infections caused by *Strongyloides stercoralis*. *Curr Opin Infect Dis* 25(4):458–463
19. Ghosh K, Ghosh K (2007) *Strongyloides stercoralis* septicaemia following steroid therapy for eosinophilia: report of three cases. *Trans R Soc Trop Med Hyg* 101(11):1163–1165
20. Wurtz R, Mirot M, Fronda G, Peters C, Kocka F (1994) Short report: gastric infection by *Strongyloides stercoralis*. *Am J Trop Med Hyg* 51(3):339–340
21. Marchese V, Crosato V, Gulletta M, Castelnuovo F, Cristini G, Matteelli A et al (2021) *Strongyloides* infection manifested during immunosuppressive therapy for SARS-CoV-2 pneumonia. *Infection* 49(3):539–542
22. Lier AJ, Tuan JJ, Davis MW, Paulson N, McManus D, Campbell S et al (2020) Case Report: disseminated Strongyloidiasis in a patient with COVID-19. *Am J Trop Med Hyg* 103(4):1590–1592
23. Celedon JC, Mathur-Wagh U, Fox J, Garcia R, Wiest PM (1994) Systemic strongyloidiasis in patients infected with the human immunodeficiency virus. A report of 3 cases and review of the literature. *Medicine (Baltimore)* 73(5):256–263
24. Mascarello M, Gobbi F, Angheben A, Gobbo M, Gaiera G, Pegoraro M et al (2011) Prevalence of *Strongyloides stercoralis* infection among HIV-positive immigrants attending two Italian hospitals, from 2000 to 2009. *Ann Trop Med Parasitol* 105(8):617–623
25. Walson JL, Stewart BT, Sangare L, Mbogo LW, Otieno PA, Piper BK et al (2010) Prevalence and correlates of helminth co-infection in Kenyan HIV-1 infected adults. *PLoS Negl Trop Dis* 4(3):e644
26. Husni RN, Gordon SM, Longworth DL, Adal KA (1996) Disseminated *Strongyloides stercoralis* infection in an immunocompetent patient. *Clin Infect Dis* 23(3):663
27. Mohammed S, Bhatia P, Chhabra S, Gupta SK, Kumar R (2019) Pulmonary hyperinfection with *Strongyloides stercoralis* in an immunocompetent patient. *Indian J Crit Care Med* 23(10):481–483
28. Bonne-Annee S, Kerepesi LA, Hess JA, O'Connell AE, Lok JB, Nolan TJ et al (2013) Human and mouse macrophages collaborate with neutrophils to kill larval *Strongyloides stercoralis*. *Infect Immun* 81(9):3346–3355
29. Galioto AM, Hess JA, Nolan TJ, Schad GA, Lee JJ, Abraham D (2006) Role of eosinophils and neutrophils in innate and adaptive protective immunity to larval *Strongyloides stercoralis* in mice. *Infect Immun* 74(10):5730–5738
30. Rosenberg HF, Dyer KD, Foster PS (2013) Eosinophils: changing perspectives in health and disease. *Nat Rev Immunol* 13(1):9–22
31. O'Connell AE, Hess JA, Santiago GA, Nolan TJ, Lok JB, Lee JJ et al (2011) Major basic protein from eosinophils and myeloperoxidase from neutrophils are required for protective immunity to *Strongyloides stercoralis* in mice. *Infect Immun* 79(7):2770–2778
32. Kerepesi LA, Hess JA, Nolan TJ, Schad GA, Abraham D (2006) Complement component C3 is required for protective innate and adaptive immunity to larval *Strongyloides stercoralis* in mice. *J Immunol* 176(7):4315–4322
33. Padigel UM, Lee JJ, Nolan TJ, Schad GA, Abraham D (2006) Eosinophils can function as antigen-presenting cells to induce primary and secondary immune responses to *Strongyloides stercoralis*. *Infect Immun* 74(6):3232–3238
34. Allen JE, Maizels RM (2011) Diversity and dialogue in immunity to helminths. *Nat Rev Immunol* 11(6):375–388
35. Mannon P, Reinisch W (2012) Interleukin 13 and its role in gut defence and inflammation. *Gut* 61(12):1765–1773
36. Montes M, Sanchez C, Verdonck K, Lake JE, Gonzalez E, Lopez G et al (2009) Regulatory T cell expansion in HTLV-1 and strongyloidiasis co-infection is associated with reduced IL-5 responses to *Strongyloides stercoralis* antigen. *PLoS Negl Trop Dis* 3(6):e456
37. Dykie A, Wijesinghe T, Rabson AB, Madugula K, Farinas C, Wilson S et al (2020) Human T-cell Leukemia Virus Type 1 and *Strongyloides stercoralis*: partners in pathogenesis. *Pathogens* 9(11):904
38. LaHoz RM, Morris MI, Practice ASTIDCo (2019) Intestinal parasites including cryptosporidium, cyclospora, giardia, and microsporidia, entamoeba histolytica, strongyloides, schistosomiasis, and echinococcus: guidelines from the American Society of Transplantation Infectious Diseases Community of Practice. *Clin Transplant* 33(9):e13618
39. Stauffer WM, Alpern JD, Walker PF (2020) COVID-19 and dexamethasone: a potential strategy to avoid steroid-related strongyloides hyperinfection. *JAMA* 324(7):623–624
40. Campo Polanco L, Gutierrez LA, Cardona AJ (2014) Diagnosis of *Strongyloides stercoralis* infection: meta-analysis on evaluation of conventional parasitological methods (1980–2013). *Rev Esp Salud Publica* 88(5):581–600
41. Nielsen PB, Mojon M (1987) Improved diagnosis of *Strongyloides stercoralis* by seven consecutive stool specimens. *Zentralbl Bakteriol Mikrobiol Hyg A* 263(4):616–618
42. Siddiqui AA, Berk SL (2001) Diagnosis of *Strongyloides stercoralis* infection. *Clin Infect Dis* 33(7):1040–1047
43. Boscolo M, Gobbo M, Mantovani W, Degani M, Anselmi M, Monteiro GB et al (2007) Evaluation of an indirect immunofluorescence assay for strongyloidiasis as a tool for diagnosis and follow-up. *Clin Vaccine Immunol* 14(2):129–133
44. Sudarshi S, Stumpfle R, Armstrong M, Ellman T, Parton S, Krishnan P et al (2003) Clinical presentation and diagnostic sensitivity of laboratory tests for *Strongyloides stercoralis* in travellers compared with immigrants in a non-endemic country. *Trop Med Int Health* 8(8):728–732
45. Requena-Mendez A, Chiodini P, Bisoffi Z, Buonfrate D, Gotuzzo E, Munoz J (2013) The laboratory diagnosis and follow up of strongyloidiasis: a systematic review. *PLoS Negl Trop Dis* 7(1):e2002
46. Gann PH, Neva FA, Gam AA (1994) A randomized trial of single- and two-dose ivermectin versus thiabendazole for treatment of strongyloidiasis. *J Infect Dis* 169(5):1076–1079
47. Detry A, Hilmarsdottir I, Mayorga-Sagastume R, Lyagoubi M, Gaxotte P, Biligui S et al (1994) Treatment of *Strongyloides stercoralis* infection with ivermectin compared with albendazole: results of an open study of 60 cases. *Trans R Soc Trop Med Hyg* 88(3):344–345
48. Greaves D, Coggle S, Pollard C, Aliyu SH, Moore EM (2013) *Strongyloides stercoralis* infection. *BMJ* 347:f4610
49. Hurlimann E, Keiser J (2019) A single dose of ivermectin is sufficient for strongyloidiasis. *Lancet Infect Dis* 19(11):1150–1151
50. Buonfrate D, Salas-Coronas J, Munoz J, Maruri BT, Rodari P, Castelli F et al (2019) Multiple-dose versus single-dose ivermectin for *Strongyloides stercoralis* infection (Strong Treat 1 to 4): a multicentre, open-label, phase 3, randomised controlled superiority trial. *Lancet Infect Dis* 19(11):1181–1190
51. Pornsuriyasak P, Niticharoenpong K, Sakapibunnan A (2004) Disseminated strongyloidiasis successfully treated with extended duration ivermectin combined with albendazole: a case report of intractable strongyloidiasis. *Southeast Asian J Trop Med Public Health* 35(3):531–534
52. Boussinesq M, Kamgno J, Pion SD, Mackenzie CD (2010) Erythropoietin for treating post-ivermectin Loa-related serious adverse events? *Trends Parasitol* 26(1):4–5

53. Hofmann D, Sayasone S, Sengngam K, Chongvilay B, Hattendorf J, Keiser J (2021) Efficacy and safety of ascending doses of moxidectin against *Strongyloides stercoralis* infections in adults: a randomised, parallel-group, single-blinded, placebo-controlled, dose-ranging, phase 2a trial. *Lancet Infect Dis* 21(8):1151–1160
54. Bisoffi Z, Buonfrate D (2021) Moxidectin: an ally to ivermectin for treating *Strongyloides stercoralis*? *Lancet Infect Dis* 21(8):1060–1061

Publisher's Note Springer Nature remains neutral with regard to jurisdictional claims in published maps and institutional affiliations.