



Post-COVID-19 rhino-orbito-cerebral mucormycosis: a new addition to challenges in pandemic control

Sandipta Mitra¹ · Mridul Janweja¹ · Arunabha Sengupta¹

Received: 17 June 2021 / Accepted: 20 July 2021 / Published online: 26 July 2021
© The Author(s), under exclusive licence to Springer-Verlag GmbH Germany, part of Springer Nature 2021

Abstract

Objective To document and analyse demographic data, clinical presentation, possible interventions for early clinical detection and management of post-COVID-19 rhino-orbito-cerebral mucormycosis (ROCM).

Method 32 patients having history of SARS-CoV-2 infection with features of ROCM were observed in terms of their history, presenting features, clinical, microbiological examination, type of surgical intervention, surgical sites of involvement which were subsequently analyzed.

Results The mean (\pm S.D.) age of patients was 57 ± 13 years. All patients were diabetic. Mean (\pm S.D.) time of onset of ROCM symptoms, since onset of COVID-19 symptoms was $18 (\pm 4)$ days. 12.5% patients were fully vaccinated. 78.1% patients received steroid therapy; 28.1% received high flow nasal oxygen. 87.5% patients had blurring of vision, 65.62% headache, 59.37% cheek and eyelid swelling, 50% proptosis, 46.87% ophthalmoplegia, 40.62% ptosis, 40.62% loss of sensation over cheek, 25% orbital pain. Examination of specimen with KOH mount revealed *Mucor* spp. in all patients. 87.5% patients underwent endoscopic sinus surgery with debridement with/without orbital clearance; 56.25% maxillectomy; 25% orbital exenteration. 87.5% patients had paranasal sinus involvement, 43.75% orbit sparing orbital apex, 68.75% orbit with orbital apex. 81.25% patients had involvement of pterygopalatine fossa±infratemporal fossa. 50% patients had disease in Vidian canal and pterygoid wedge. 25% of patients had involvement of palate and 56.25% cheek and eyelid soft tissues.

Conclusion A judicious COVID treatment protocol, high index of suspicion, close monitoring of high-risk patients and early institution of treatment can prevent case severity and reduce mortality.

Keywords COVID-19 · SARS-CoV-2 · Mucormycosis · Paranasal sinuses

Introduction

Mucormycosis is an opportunistic fungal infection caused by fungi of the order Mucorales, the most common of which is *Rhizopus oryzae*. Immunocompromised patients, such as those suffering from diabetes mellitus (DM), malignancy, prolonged neutropenia, hematopoietic stem cell transplant/solid organ transplant recipients are at high risk of developing this disease [1]. The commonest form of presentation is rhino-orbito-cerebral mucormycosis (ROCM), with symptoms ranging from orbital pain, periorbital swelling, facial pain, facial numbness, conjunctival suffusion, diminution of

vision to complete ophthalmoplegia, blindness and cavernous sinus thrombosis.

COVID-19 is a global health emergency and has affected over 169 million people worldwide at the time of writing this paper [2]. Recent times have seen a sudden surge of mucormycosis cases, especially ROCM in patients who have tested positive for SARS-CoV2 recently or in the past. Many theories have emerged to associate causality of ROCM with COVID infection, such as immunosuppression caused by the virus [3], corticosteroid administration [4], uncontrolled DM [5] and possible peripheral microthrombi [6], but the exact cause is yet to be established.

COVID-19 may present with a myriad of symptoms. Though existing literature has shed much light on the native symptoms of the disease spectrum, addition of opportunistic infection, such as ROCM, has created an additional burden on healthcare resources. Hence, to formulate effective control measures, it is imperative

✉ Mridul Janweja
mriduljanweja@gmail.com

¹ Institute of Otorhinolaryngology and Head & Neck Surgery,
Institute of Post-Graduate Medical Education & Research,
Kolkata, India

to answer certain critical questions pertaining to the course of mucormycosis associated with active or post-COVID-19 infection, its common presentations and possible interventions.

Materials and methods

32 patients with a documented history of SARS-CoV-2 infection presenting with features of ROCM were included in our study. Patients with known head and neck malignancy, post-chemoradiation, on chronic steroid or immunosuppressive drug therapy (pre-COVID-19 infection) were excluded from our study. Following a detailed history taking, all the patients were subjected to clinical examination, radiological assessment in the form of Gadolinium enhanced MRI brain with nose, paranasal sinuses and orbits, diagnostic nasal endoscopy and guided nasal smears/biopsy for Potassium hydroxide (KOH) examination and ophthalmological evaluation (Figs. 1, 2, 3). Pre-operative workup and pre-anaesthetic check-up were done. All patients were treated with either one or a combination of surgical interventions, namely, endoscopic sinus surgery (ESS)/sinus debridement/endoscopic orbital clearance and/or maxillectomy and/or orbital exenteration with adjuvant Amphotericin-B infusion.

The parameters assessed were demographic data, comorbidities, time of onset of ROCM symptoms since onset of COVID-19 symptoms, COVID-19 vaccination status, treatment received for COVID-19 infection, clinical features, microbiological examination on KOH mount, type of surgical intervention and common sites of involvement during surgery. Data were summarized as mean and standard deviation for continuous variables and counts and percentages for categorical variables.

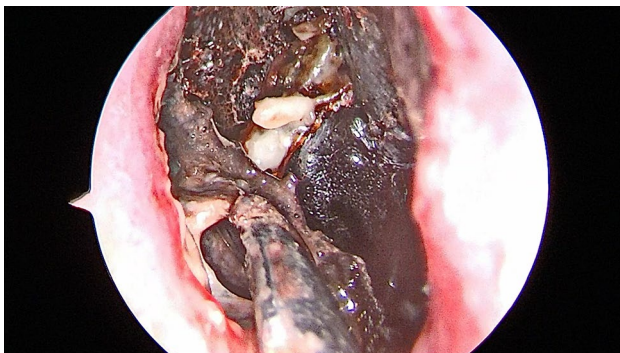


Fig. 1 Diagnostic nasal endoscopy showing extensive necrosis of nasal mucosa with black eschar

Results

Age

The mean (\pm S.D.) age of the patients was 57 ± 13 years.

Sex

The male to female ratio was 23:9 with 71.8% patients of male sex.

Co-morbidities

All patients were found to have DM, with 62.5% (20/32) patients having impaired glycemic state at the time of

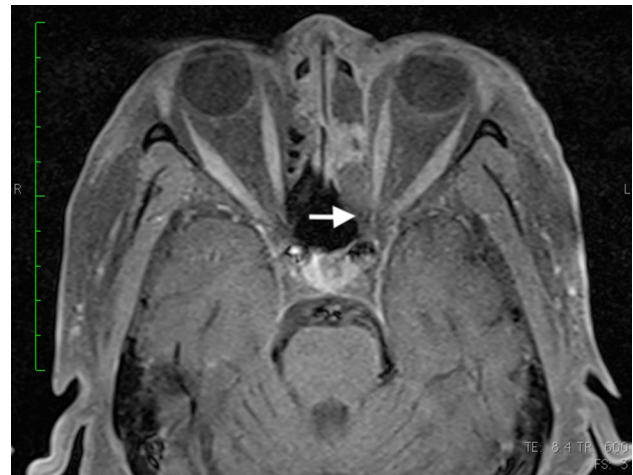


Fig. 2 Post-contrast fat suppressed T1 axial MRI showing hypointense shadow near left orbital apex (white arrow)

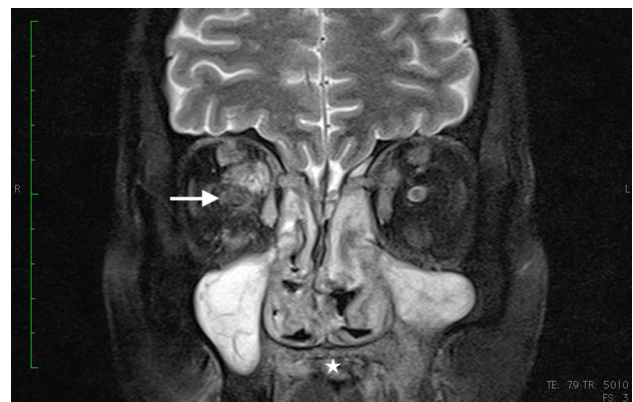


Fig. 3 Fat suppressed T2 coronal MRI showing extensive involvement of right orbit including extra-ocular muscles and optic nerve (white arrow). In addition, note the hypointense shadow involving hard palate (starmark)

presentation. 18.75% (6/32) patients suffered from hypertension and one patient had chronic kidney disease.

Time of onset of ROCM symptoms since onset of COVID-19 symptoms

The mean (\pm S.D.) time of onset of ROCM symptoms since onset of COVID-19 symptoms was found to be 18 (\pm 4) days.

COVID-19 vaccination status

12.5% (4/32) of affected patients were fully vaccinated, while one patient received a single dose of vaccine prior to onset of ROCM symptoms.

Treatment received for COVID-19 infection

78.1% (25/32) patients received steroid therapy, in oral or parenteral form as a part of COVID-19 treatment. 28.1% (9/32) patients received high flow nasal oxygen in a hospital setup. 15.6% (5/32) patients were in home isolation only and did not receive any medication.

Clinical features

87.5% (28/32) patients presented with blurring of vision, 65.62% (21/32) with headache, 59.37% (19/32) with cheek and eyelid swelling, 50% (16/32) with proptosis, 46.87% (15/32) patients with ophthalmoplegia, 40.62% (13/32) with ptosis, 40.62% (13/32) with loss of sensation over cheek, 25% (8/32) with orbital pain, and one patient presented with

dysphagia and palsy of facial and lower cranial nerves (IX, X, XI) (Fig. 4).

Microbiological examination

Examination of specimen with KOH mount revealed wide angled, broad, aseptate hyphae suggestive of *Mucor* spp. in all patients. One patient had a mixed flora comprising of *Mucor* spp., *Candida* sp. and *Aspergillus*.

Type of surgical intervention

87.5% (28/32) patients underwent ESS with sinus debridement with/without orbital clearance. 56.25% (18/32) patients underwent maxillectomy of which 44.4% (8/18) underwent total maxillectomy. Out of the 10 patients who underwent partial maxillectomy, 7 patients underwent medial maxillectomy and 3 underwent infrastructure maxillectomy. None of them had bilateral involvement. For involvement of soft tissues of cheek and eyelids, necrotic tissues were debrided. 25% (8/32) patients had their orbit exenterated.

Surgical sites of involvement

87.5% (28/32) patients had involvement of paranasal sinuses, 43.75% (14/32) orbit sparing orbital apex. 68.75% (22/32) patients had involvement of orbit with orbital apex showing thrombosed ophthalmic artery (scarce bleeding intra-operatively). 81.25% (26/32) patients had disease involving pterygopalatine fossa with/without extension into infratemporal fossa. 50% patients were found to have disease invading the Vidian canal and/or bony pterygoid wedge. 25% (8/32)

Fig. 4 Figure showing common presenting features with corresponding number of patients

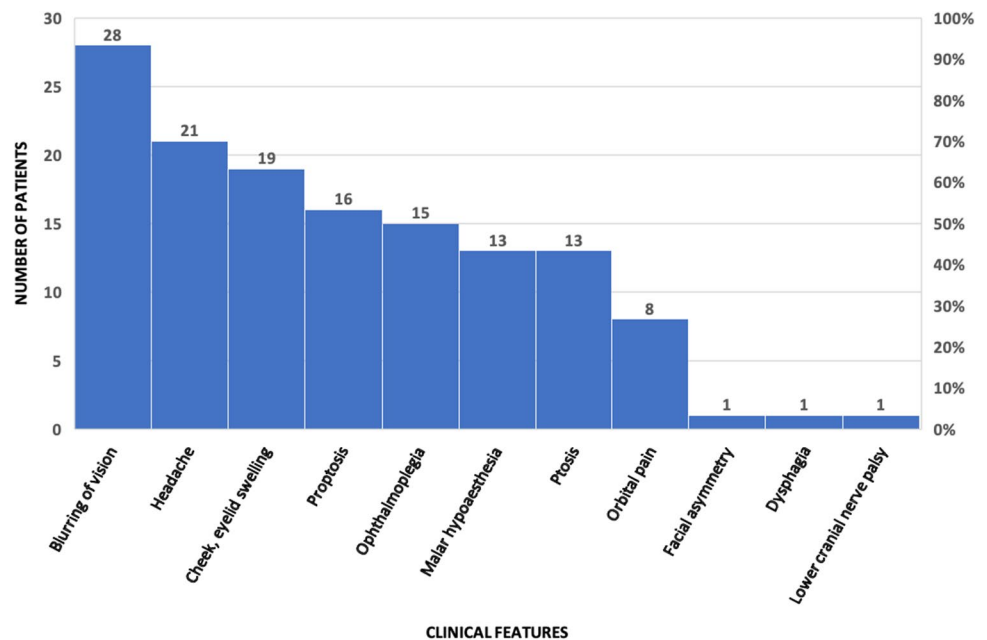


Table 1 Surgical sites of involvement found intra-operatively

Surgical sites of involvement	Number of patients	Percentage (%)
Paranasal sinuses	28	87.50
Orbit sparing orbital apex	14	43.75
Orbit with orbital apex	22	68.75
Pterygopalatine ± infratemporal fossa	26	81.25
Palate	8	25.00
Vidian canal ± pterygoid wedge	16	50
Facial/eyelid soft tissues	18	56.25

of patients presented with involvement of palate. 56.25% (18/32) patients had involvement of soft tissues of cheek and eyelids (Table 1).

Discussion

Mucormycosis has been long recognized as a rare, fulminant, life-threatening disease of fungal etiology, belonging to Mucorales [7]. It may present in many forms which include rhino-orbito-cerebral, pulmonary, cutaneous, gastrointestinal or disseminated disease. In India, the estimated number of cases diagnosed with mucormycosis is 0.14 cases per 1000 population [8]. With the onset of COVID-19 pandemic, clinicians have seen an alarming rise in the number of cases of ROCM in post-infectious or active COVID-19 affected patients, which is manifold than the usual reported incidence of the disease in the pre-COVID setting. In a study by White et al., 26.7% of the patients with COVID-19 were found to have invasive fungal infection [9].

Lymphopenia has been associated with high morbidity and mortality in COVID-19 patients [10]. Decreased CD4+ and CD8+ T-cell population, which are mediators of protective cell mediated immunity against fungal pathogens, increase the propensity of opportunistic mycotic infections in COVID-19 affected patients. Moreover, background of poorly controlled DM, which is seen in majority of the patients presenting with post-COVID Mucorales infection further jeopardises the host response [11–13]. Furthermore, steroid therapy, which has evolved as an integral part of moderate to severe COVID-19 management, leads to impaired glycemic state as well as waning immune response. Hence, COVID-19 infected patients with history of DM, who are started on steroid therapy, should be kept on strict surveillance for early signs and symptoms of ROCM. Patients should be made aware of early symptoms, such as headache, numbness of face, blurring of vision which should prompt early diagnostic nasal endoscopy, ophthalmological evaluation and further work-up, if indicated.

Angioinvasion with infarction is the hallmark of invasive mucormycosis [14]. The critical vessels in the vicinity of the disease, such as ophthalmic artery, sphenopalatine artery were often found to be completely thrombosed with scanty bleeding intra-operatively (Fig. 5). The resultant infarction contributes to the typical clinical findings of vision loss, pre-maxillary, peri-orbital soft tissue involvement, sino-nasal mucosal discolouration and necrosis of the underlying bone. Hence, debridement of all devitalized, necrotic tissues including dead bone is imperative for checking the inflammatory load. Herein comes the importance of extent of surgical debridement, which is often a matter of debate. Critical areas affecting surgical decision-making include involvement of pre-maxillary, peri-orbital soft tissues, hard and soft palate, pterygopalatine fossa, pterygoid wedge, Vidian canal and skull base which often require bone drilling. Pre-maxillary, peri-orbital soft tissue or palatal involvement precludes exclusive endoscopic approach and calls for more aggressive open approach. Perineural invasion is another distinctive feature of ROCM [15]. This along with angioinvasion accounts for early optic nerve involvement and orbital apex syndrome. In this respect, decision of orbital exenteration is often controversial [16]. In a review of literature by Hargrove et al., there is no standard guideline regarding decision-making of orbital exenteration in ROCM patients [17]. Shah et al. have devised a scoring system to guide the decision-making of exenterating the orbit in patients with ROCM [18]. The fulminant nature of the disease and its consequent aggressiveness of management often leaves the patients with considerable morbidity and poor quality of life post-operatively.

Early diagnosis is the key. High degree of clinical suspicion coupled with appropriate investigations should be done at the earliest in high-risk patients. Nasal endoscopy with biopsy and swabs for KOH mount and fungal culture are the most economical and easily available tools for diagnosis. In addition, MRI of paranasal sinus with orbit and brain

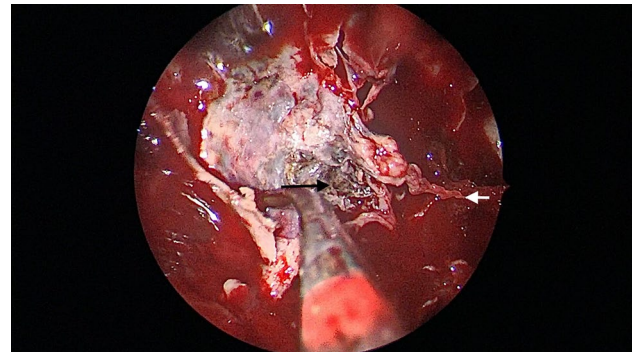


Fig. 5 Posterior wall of right maxillary sinus being removed to show necrotic tissue filling right pterygopalatine fossa (black arrow) with a thrombosed right sphenopalatine artery (white arrow)

aid in surgical planning and extent of resection. Surgical debridement of all the accessible necrotic tissues should be done as far as practicable. Post-operatively, total leucocyte counts and serial C-reactive protein (CRP) are vital and easily accessible markers of inflammation and residual disease surveillance, especially in critical-care setting [19]. Renal function tests and electrolytes should be closely monitored in the peri-operative period as these patients are treated with adjuvant Amphotericin-B, which is potentially nephrotoxic [20]. Long-term follow-up data of the patients are still awaited and shall be addressed in further studies. We acknowledge this as a limitation of our study.

Mucormycosis has long been recognized as a life-threatening infection in susceptible individuals. However, its addition to the spectrum of COVID-19 has posed a new challenge due to an already weakened immunity with concomitant multi-system compromise due to the virus itself. As cases continue to be reported globally, still much needs to be known about this deadly combination of virus and fungus, which is slowly becoming an epidemic in itself [21–24].

Conclusion

COVID-19 patients with high-risk features should be kept under surveillance. A slightest degree of suspicion must prompt early diagnosis and initiation of treatment. Clinicians should not hesitate to initiate Amphotericin B therapy when there is reasonable suspicion of ROCM. Underlying risk factors such as diabetes should be managed promptly. Radical debridement of all necrotic tissue, with special attention to the critical surgical areas of affection must be done as far as practicable, to decrease the inflammatory burden and increase the drug penetration.

References

1. Spellberg B, Ibrahim AS (2018) Mucormycosis. In: Jameson JL, Fauci AS, Kasper DL, Hauser SL, Longo D, Loscalzo J (eds) Harrison's principles of internal medicine, 20th edn. McGraw-Hill Education, New York, p 1538
2. COVID-19 Data Repository by the Center for Systems Science and Engineering (CSSE) at Johns Hopkins University. <https://www.arcgis.com/apps/dashboards/bda7594740fd40299423467b48e9ecf6>. Accessed 29 May 2021
3. Peman J, Gaitan AR, Vidal CG, Salavert M, Ramirez P, Puchades F, Hita MG, Izquierdo AA, Quindo G (2020) Fungal co-infection in COVID-19 patients: should we be concerned? *Rev Iberoam Micol* 37(2):41–46
4. Ahmadikia K, Hashemi SJ, Khodavaissy S, Getso MI, Aljani N, Badali H, Mirhendi H, Salehi M, Tabari A, Mohammadi Ardehali M, Kord M, Roilides E, Rezaie S (2021) The double-edged sword of systemic corticosteroid therapy in viral pneumonia: a case report and comparative review of influenza-associated mucormycosis versus COVID-19 associated mucormycosis. *Mycoses*. <https://doi.org/10.1111/myc.13256>. Advanceonline publication
5. Sharma S, Grover M, Bhargava S, Samdani S, Kataria T (2021) Post coronavirus disease mucormycosis: a deadly addition to the pandemic spectrum. *J Laryngol Otol* 135(5):442–447. <https://doi.org/10.1017/S0022215121000992>
6. Moorthy A, Gaikwad R, Krishna S et al (2021) SARS-CoV-2, uncontrolled diabetes and corticosteroids—an unholy trinity in invasive fungal infections of the maxillofacial region? A retrospective, multi-centric analysis. *J Maxillofac Oral Surg*. <https://doi.org/10.1007/s12663-021-01532-1>
7. Kendall KA, Senders CW (1996) Rhinocerebral mucormycosis. In: Gershwin ME, Incaudo GA (eds) Diseases of the sinuses. Humana Press, Totowa
8. Skiada A, Pavleas I, Drogari-Apiranthitou M (2020) Epidemiology and diagnosis of mucormycosis: an update. *J Fungi*. <https://doi.org/10.3390/jof6040265>
9. White PL, Dhillon R, Cordey A et al (2020) A national strategy to diagnose COVID-19 associated invasive fungal disease in the ICU. *Clin Infect Dis*. <https://doi.org/10.1093/cid/ciaa1298>
10. Henry BM (2020) COVID-19, ECMO, and lymphopenia: a word of caution. *Lancet Respir Med*. [https://doi.org/10.1016/S2213-2600\(20\)30119-3](https://doi.org/10.1016/S2213-2600(20)30119-3)
11. Revannavar SM, Supriya PS, Samaga L, et al (2021) COVID-19 triggering mucormycosis in a susceptible patient: a new phenomenon in the developing world?. *BMJ Case Rep* 14(4):e241663. <https://doi.org/10.1136/bcr-2021-241663>
12. Bagdade JD (1976) Phagocytic and microbicidal function in diabetes mellitus. *Acta Endocrinol Suppl (Copenh)* 205:27–34
13. Waldorf AR, Ruderman N, Diamond RD (1984) Specific susceptibility to mucormycosis in murine diabetes and bronchoalveolar macrophage defense against *Rhizopus*. *J Clin Invest* 74(1):150–160
14. Frater JL, Hall GS, Procop GW (2001) Histologic features of zygomycosis: emphasis on perineural invasion and fungal morphology. *Arch Pathol Lab Med* 125(3):375–378
15. Sravani T, Uppin SG, Uppin MS, Sundaram C (2014) Rhinocerebral mucormycosis: pathology revisited with emphasis on perineural spread. *Neurol India* 62:383–386
16. Songu M, Unlu HH, Gunhan K, Ilker SS, Nese N (2008) Orbital exenteration: a dilemma in mucormycosis presented with orbital apex syndrome. *Am J Rhinol* 22(1):98–103
17. Hargrove RN, Wesley RE, Klippenstein KA, Fleming JC, Haik BG (2006) Indications for orbital exenteration in mucormycosis. *Ophthalmic Plast Reconstr Surg* 22(4):286–291
18. Shah K, Dave V, Bradoo R, Shinde C, Prathibha M (2019) Orbital Exenteration in rhino-orbito-cerebral mucormycosis: a prospective analytical study with scoring system. *Indian J Otolaryngol Head Neck Surg* 71(2):259–265
19. Kostiala I (1984) C-reactive protein response induced by fungal infections. *J Infect* 8(3):212–220
20. Cornely OA, Alastruey-Izquierdo A, Arenz D et al (2019) Global guideline for the diagnosis and management of mucormycosis: an initiative of the European Confederation of Medical Mycology in cooperation with the Mycoses Study Group Education and Research Consortium. *Lancet Infect Dis* 19(12):e405–e421
21. Sarkar S, Gokhale T, Choudhury SS, Deb AK (2021) COVID-19 and orbital mucormycosis. *Indian J Ophthalmol* 69(4):1002–1004
22. Alekseyev K, Didenko L, Chaudhry B (2021) Rhinocerebral mucormycosis and COVID-19 pneumonia. *J Med Cases* 12(3):85–89
23. Maini A, Tomar G, Khanna D, Kini Y, Mehta H, Bhagyasree V (2021) Sino-orbital mucormycosis in a COVID-19 patient: a

- case report. *Int J Surg Case Rep.* <https://doi.org/10.1016/j.ijscr.2021.105957>
24. Krishna DS, Raj H, Kurup P, Juneja M (2021) Maxillofacial infections in covid-19 era-actuality or the unforeseen: 2 case reports. *Indian J Otolaryngol Head Neck Surg.* <https://doi.org/10.1007/s12070-021-02618-5>

Publisher's Note Springer Nature remains neutral with regard to jurisdictional claims in published maps and institutional affiliations.