



Correction to: The application of venous nerve conduit trap in the immediate repair and reconstruction of facial nerve in parotid gland tumor: an attempt of a new technique

Yudong Ning¹ · Wei Wang¹ · Yongcong Cai¹ · Yuqiu Zhou¹ · Jian Jiang¹ · Dingfen Zeng¹ · Ronghao Sun¹ · Xu Wang¹ · Wanghu Zheng¹ · Tianqi He¹ · Chunyan Shui¹ · Wei Liu¹ · Yuyao Zhang¹ · Xiaolei Chen¹ · Chao Li^{1,2}

Published online: 24 May 2021
© Springer-Verlag GmbH Germany, part of Springer Nature 2021

**Correction to: European Archives of
Oto-Rhino-Laryngology**
<https://doi.org/10.1007/s00405-021-06732-6>

In the original publication of the article, figure 3 was published incorrectly. The correct Fig. 3 is provided below,

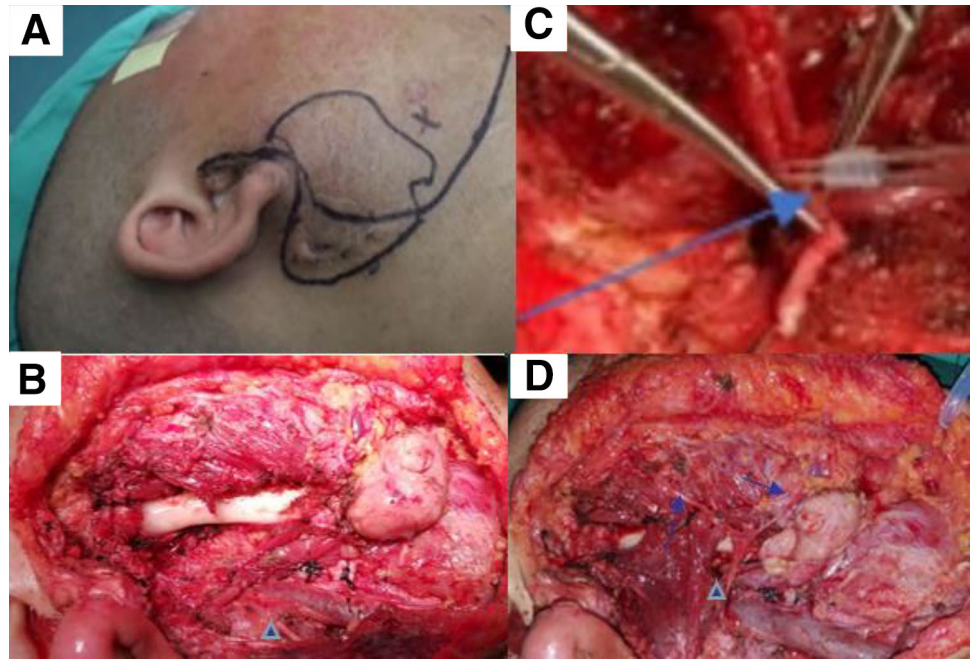
The original article can be found online at <https://doi.org/10.1007/s00405-021-06732-6>.

✉ Chao Li
headneck@qq.com
Yudong Ning
surgeon_ning@163.com

¹ Department of Head and Neck Surgery, Sichuan Cancer Hospital & Institute, Sichuan Cancer Center, School of Medicine, University of Electronic Science and Technology, Chengdu, China

² Department of Head and Neck Surgery, Sichuan Cancer Hospital, No.55, 4th Section of Southern Renmin Road, Chengdu 610041, Sichuan, China

Fig. 3 **a** Surgical incision. **b** The tumor and invaded facial nerve and tissues were already removed. **c** Select superficial vein, whose diameter was slightly larger than the repaired nerve, to make the nerve conduit. Before the anastomosis, venous nerve conduit was eventually wrapped at the anastomotic site. **d** The broken facial nerve branches were then anastomosed end-to-end with the accessory nerve branches. The arrow pointed to the venous nerve conduits. Triangle marked the accessory nerve



Publisher's Note Springer Nature remains neutral with regard to jurisdictional claims in published maps and institutional affiliations.