

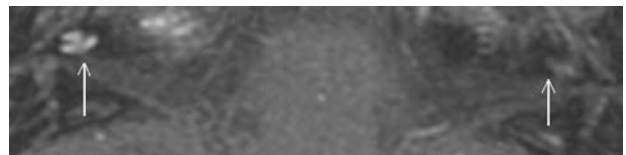
Magnetic resonance imaging in patients with meningitis induced hearing loss

J. Beijen · J. Casselman · F. Joosten · T. Stover ·
A. Aschendorff · A. Zarowski · H. Becker · E. Mylanus

Published online: 4 April 2009
© Springer-Verlag 2009

Erratum to: Eur Arch Otorhinolaryngol
DOI 10.1007/s00405-009-0921-z

In Fig. 2 as it is printed in the article, an indication arrow is pointing to a location that does not correspond with the location of the cochlea. The correct Fig. 2 is given here.



The online version of the original article can be found under
doi:[10.1007/s00405-009-0921-z](https://doi.org/10.1007/s00405-009-0921-z).

J. Beijen (✉) · E. Mylanus
Department of Otorhinolaryngology,
Radboud University Medical Centre, Philips van Leydenlaan 15,
P.O. Box 9101, 6500 HB Nijmegen, The Netherlands
e-mail: j.beijen@kno.umcn.nl

J. Casselman
Department of Radiology, Academic Hospital, Bruges, Belgium

F. Joosten
Department of Radiology,
Alysis Hospital, Arnhem, The Netherlands

T. Stover
Department of Otorhinolaryngology,
Medical University of Hannover, Hannover, Germany

A. Aschendorff
Department of Otorhinolaryngology,
University Hospital of Freiburg, Freiburg, Germany

A. Zarowski
Department of Otorhinolaryngology,
Sint-Augustinus University Hospital, Antwerp, Belgium

H. Becker
Department of Neuroradiology,
Medical University of Hannover, Hannover, Germany