



Correction: Apical prolapse correction by unilateral pectineal suspension

Michael Schreibmayer^{1,2,3} · Dimitrios I. Bolovis^{1,3,4} · Cosima V. M. Brucker^{1,3}

Published online: 3 November 2023
© The Author(s) 2023

Correction: Archives of Gynecology and Obstetrics
<https://doi.org/10.1007/s00404-023-07067-9>

Figure 1 was missing from this article; the figure should have appeared as shown below. The Original article is also updated.

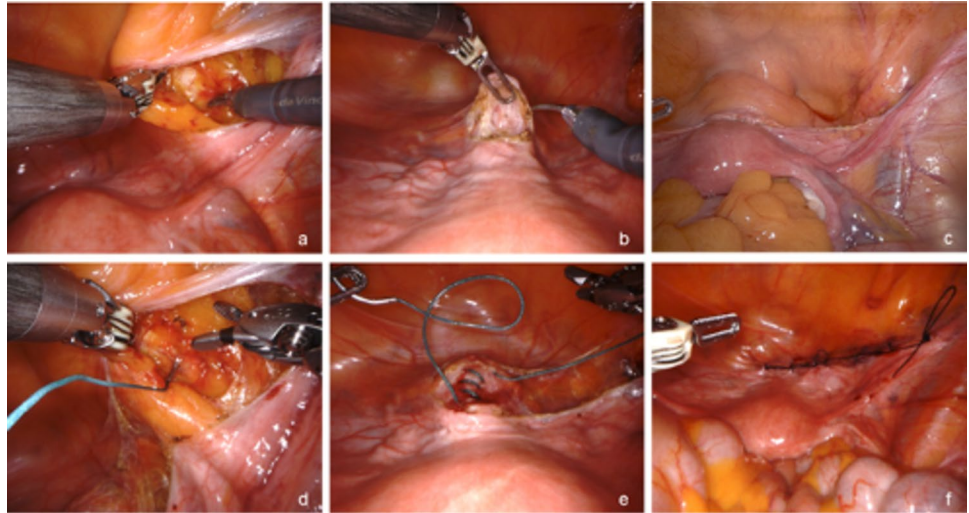
Open Access This article is licensed under a Creative Commons Attribution 4.0 International License, which permits use, sharing, adaptation, distribution and reproduction in any medium or format, as long as you give appropriate credit to the original author(s) and the source, provide a link to the Creative Commons licence, and indicate if changes were made. The images or other third party material in this article are

The original article can be found online at <https://doi.org/10.1007/s00404-023-07067-9>.

✉ Michael Schreibmayer
michael.schreibmayer@gmail.com

- ¹ University Women's Hospital, Paracelsus Medical University, Nuremberg, Germany
- ² Department of Obstetrics and Gynecology, Krankenhaus Barmherzige Brüder St. Veit/Glan, St. Veit an der Glan, Austria
- ³ Paracelsus Medical University, Salzburg, Austria
- ⁴ Georg Simon Ohm Technical University, Nuremberg, Germany

Fig. 1 Exposure of the pectineal (“Cooper”) ligament (a), removing the bladder flap from the anterior cervix (b), completing peritoneal dissection between bladder flap and pectineal ligament (c), placing a non-absorbable Ethibond #2 suture through the pectineal ligament (d), attaching the Ethibond #2 suture to the cervix and connecting the two structures (e), closure of the peritoneum with a running absorbable Vicryl #2.0 suture (f)



included in the article's Creative Commons licence, unless indicated otherwise in a credit line to the material. If material is not included in the article's Creative Commons licence and your intended use is not permitted by statutory regulation or exceeds the permitted use, you will need to obtain permission directly from the copyright holder. To view a copy of this licence, visit <http://creativecommons.org/licenses/by/4.0/>.

Publisher's Note Springer Nature remains neutral with regard to jurisdictional claims in published maps and institutional affiliations.