

Erratum to: Locked posterior shoulder dislocation: treatment options and clinical outcomes

Benedikt Schliemann · Daniel Muder ·
Jan Geßmann · Thomas A. Schildhauer ·
Dominik Seybold

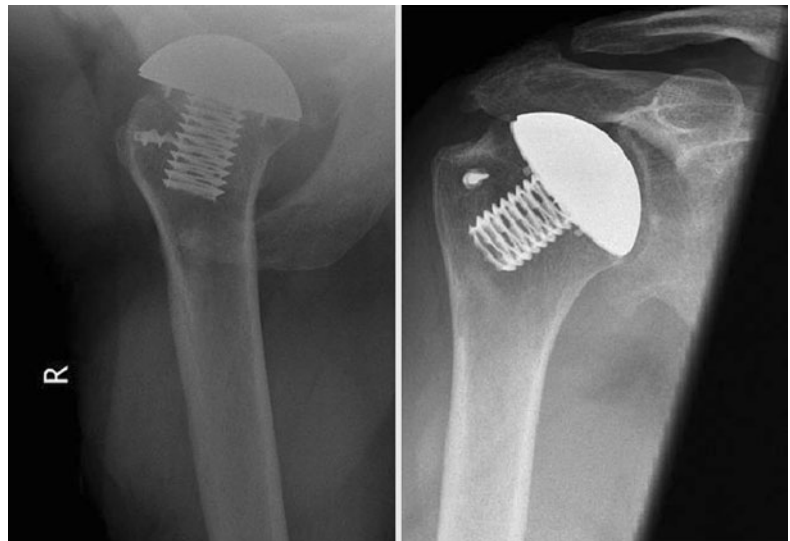
Published online: 5 August 2011
© Springer-Verlag 2011

Erratum to: Arch Orthop Trauma Surg DOI 10.1007/s00402-011-1310-9

Owing to an unfortunate error, Fig. 7 displays a copy of a figure published in an article by Gavriilidis et al. (“Chronic

locked posterior shoulder dislocation with severe head involvement” Int Orthop 2010 Feb;34(1):79–84. Epub 2009 Mar 20). Although, permission to publish that figure in our article has been obtained, the figure has to be replaced by the following X-rays:

Fig. 7 Hemiarthroplasty for a massive humeral head defect



The online version of the original article can be found under doi:[10.1007/s00402-011-1310-9](https://doi.org/10.1007/s00402-011-1310-9).

B. Schliemann
Department of Trauma, Hand and Reconstructive Surgery,
University Hospital Münster, Waldeyerstr. 1,
48149 Münster, Germany

D. Muder · J. Geßmann · T. A. Schildhauer · D. Seybold (✉)
Department of Trauma Surgery, BG-University Hospital
Bergmannsheil Bochum, Bürkle-de-la-Camp-Platz 1,
44789 Bochum, Germany
e-mail: dseybold@mac.com