

Rudi Beschorner · Stefan Engel · Michel Mittelbronn  
Diana Adjodah · Klaus Dietz  
Hermann J. Schluesener · Richard Meyermann

## Differential regulation of the monocytic calcium-binding peptides macrophage-inhibiting factor related protein-8 (MRP8/S100A8) and allograft inflammatory factor-1 (AIF-1) following human traumatic brain injury

Received: 24 January 2000 / Revised, accepted: 24 February 2000

**Abstract** Intracellular calcium ( $\text{Ca}^{2+}$ ) has been shown to function as second messenger and to be associated with activation of different cell types including microglia. Previously, in human focal cerebral infarctions an early expression of macrophage-related protein-8 (MRP8/S100A8), a member of the  $\text{Ca}^{2+}$ -binding S100-protein family, in microglia has been reported. On the other hand, a delayed activation of microglia was observed following traumatic brain injury (TBI). We therefore examined immunohistochemically microglial expression of MRP8 and allograft inflammatory factor-1 (AIF-1), identical to microglial response factor-1 (mrf-1) and ionized calcium binding adaptor molecule-1 (iba1) in human brains after TBI and in control brains. Both, MRP8 and AIF-1 are  $\text{Ca}^{2+}$ -binding peptides which have been associated with microglial activation in experimental models and in human cerebral infarctions. Detection of AIF-1 in controls confirmed constitutive expression of this peptide in a subset of microglial cells. After TBI, the density of AIF-1<sup>+</sup> microglia did not increase significantly. Lesional expression of AIF-1 did not significantly differ from other brain regions. Furthermore, following TBI, we found no significant differences in the density of AIF-1<sup>+</sup> microglia as compared to controls. Microglial MRP8 expression was not detectable in controls and within the first 3 days post TBI, but increased rapidly after 3 days post TBI, suggesting a subpopulation of microglial cells to be AIF-1<sup>-</sup>/MRP8<sup>+</sup>. We conclude that the delayed expression of MRP8 and the lack of AIF-1 up-regulation in microglia after TBI is in contrast to ischemic brain lesions and might reflect different activation cascades of microglia.

**Key words** Allograft-inflammatory factor-1 · Microglia response factor-1 · Macrophage-inhibiting factor related-protein-8/S100A8 · Traumatic brain injury · Human

### Introduction

Calcium ( $\text{Ca}^{2+}$ ) functions as an intracellular second messenger and is associated with activation of many cells, including monocytes [6] and microglia [18, 19]. In these cell types,  $\text{Ca}^{2+}$  responses precede phagocytosis and oxidative burst. It induces the transcription of a number of eukaryotic genes through transcription factors interacting with  $\text{Ca}^{2+}$  response elements [22]. Several  $\text{Ca}^{2+}$ -binding peptides, in particular members of the S100 supergene family such as S100A8 (macrophage-related protein 8, MRP8) and S100A9 (MRP14) are preferentially expressed in activated microglia ([13, 16, 20, 23], for review see [24]). MRP8 expression has been reported in various inflammatory conditions, including active inflammatory bowel disease [15], HTLV-I-associated myelopathy [1], coronavirus-induced demyelination in rats [31], human cerebral malaria [25] and human focal cerebral ischemia [20]. The allograft inflammatory factor-1 (AIF-1) is a polypeptide of 17 kDa that contains a 12-amino acid region, similar to  $\text{Ca}^{2+}$ -binding EF-hand domains [29]. AIF-1 has been detected in cultured rat microglial cells [11], in rat brain tissue by immunohistochemistry [3], in chronically rejected rat heart allografts [29] and in human heart transplants [30]. Human and rat amino acid sequences are 98% homologous [2]. AIF-1 is constitutively expressed in lymphatic tissue [2, 11] and is up-regulated in monocytes/macrophages under various pathological conditions such as chronic rejection of rat and human allografts [29, 30] and in autoimmune lesions [3, 26]. In the central nervous system (CNS) AIF-1 immunoreactivity is restricted to microglial cells [11]. Increasing AIF-1 expression was found to be associated with microglial activation. Following axotomy, increased AIF-1 expression in activated microglia surrounding injured central motor neurons in adult rats has been reported [7, 12, 28]. In acute inflammatory au-

R. Beschorner (✉) · S. Engel · M. Mittelbronn · D. Adjodah  
H. J. Schluesener · R. Meyermann  
Institute of Brain Research, Eberhard-Karls-University,  
Calwerstrasse 3, 72076 Tübingen, Germany  
e-mail: rudi.beschorner@med.uni-tuebingen.de,  
Tel.: +49-7071-2982293, Fax: +49-7071-294846

K. Dietz  
Department of Medical Biometry, Eberhard-Karls-University,  
Tübingen, Germany

tomimmune lesions of rat CNS, increased AIF-1 immunoreactivity was detected in microglia [25].

To analyze microglial reactions following human traumatic brain injury (TBI) we examined the temporal and regional expression of the two Ca<sup>2+</sup>-binding peptides, AIF-1 and MRP8 (S100A8), known to be associated with activation of monocytic/microglial cells.

## Materials and methods

### Patients

We investigated brain tissue from 24 cases (aged 18–87 years; Table 1) who died after severe closed TBI. The survival time post TBI varied from minutes up to 6 months. Tissue for paraffin-embedding was sampled in all cases from (1) the traumatized brain region (hemorrhagic contusion), (2) the region immediate adjacent to the contusion, (3) a macroscopic inconspicuous region remote to the lesion, and (4) the brain stem. These areas were selected by macroscopic examination according to the definitions established by Graham and Gennarelli [8] and inspected by microscopy. Tissue sections were routinely stained for hematoxylin-eosin (H & E) luxol-fast-blue (LFB), periodic acid staining (PAS), Bielschowsky's axon stain, Elastica-van-Gieson (EvG), and Berlin-blue (BB). In all cases histopathological stages of traumatic lesions correspond to clinical data.

Controls consisted of 20 adult cases (aged 21–92 years) who died from non-neurological diseases and, considering clinical history and neuropathological investigations, did not suffer from any

neurological disease. Moreover, brains affected by other medical conditions, known to alter the activation state of the immune system, e.g., sepsis, malignant neoplasias, immunosuppressive medication, were excluded. This was also true for brains with hypoxia, which is known to activate microglia immediately [20].

### Immunohistochemistry

Immunohistochemistry for AIF-1 was performed using a recently established monoclonal antibody [25]. In brief, slices were rehydrated and pretreated for 10 min in a microwave oven (600 W) in citrate buffer pH 6.0. Endogenous peroxidase was inhibited with 1% H<sub>2</sub>O<sub>2</sub> in methanol (15 min), and normal rabbit serum (1:10) was used to block nonspecific binding sites (15 min at room temperature). AIF-1 antibody-containing hybridoma supernatant was applied overnight at 4 °C. Antibody binding was visualized with biotinylated secondary antibody, streptavidin and biotinylated horseradish peroxidase complex (StrepABC/HRP; Dako GmbH, Hamburg, Germany) and diaminobenzidine (DAB; Dako) as chromogen. Immunostainings with antibodies directed against MRP8 (BMA Biomedicals AG, Augst, Switzerland; dilution 1:200) and CD68 (Dako; dilution 1:150) were handled appropriately. However, MRP8 was stained directly by a biotinylated antibody.

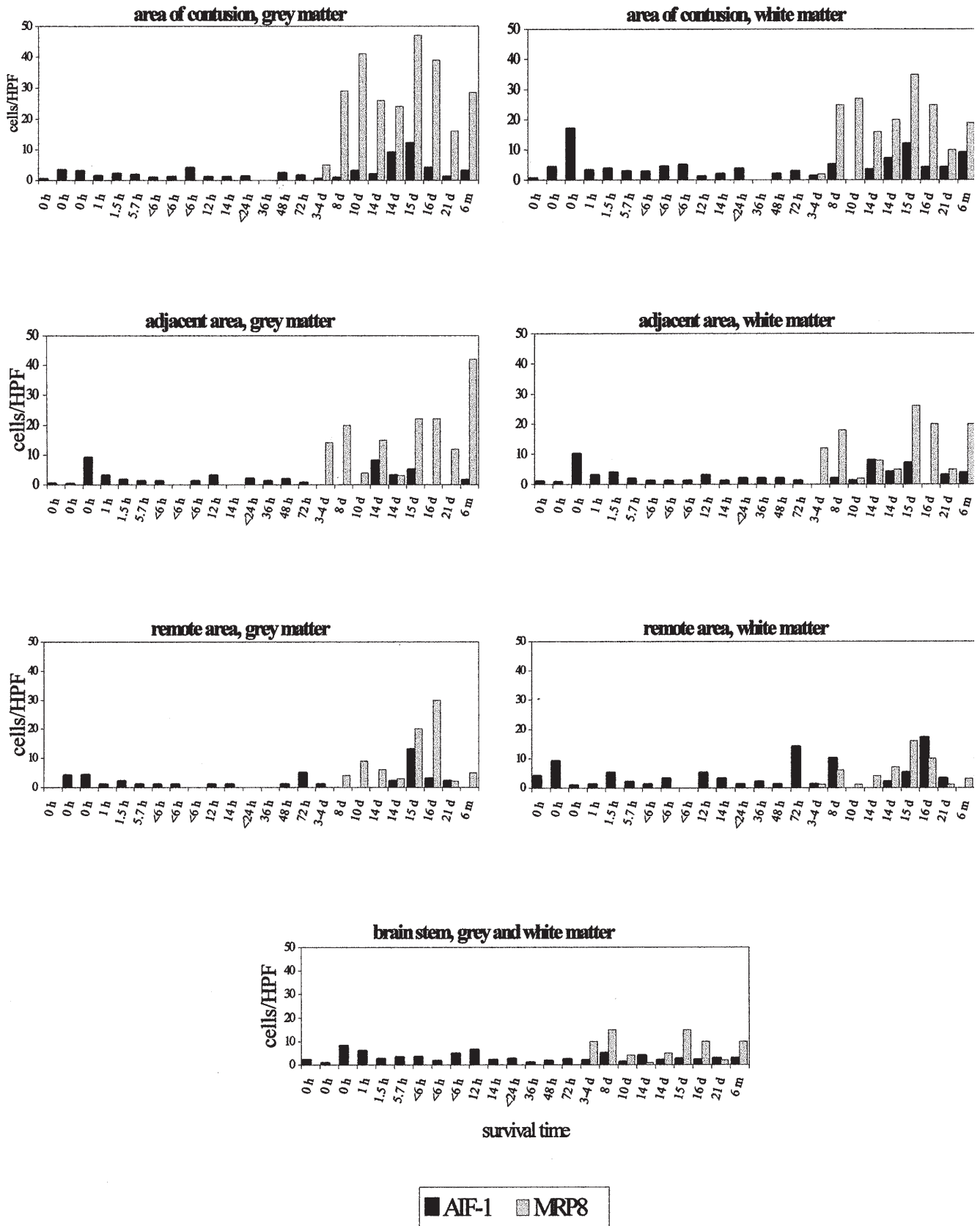
### Double-labeling experiments

Double immunolabeling was performed by incubating sections with the first primary antibody (CD68, MRP8) for 1 hour after a 10-min microwave pre-treatment in citrate buffer pH 6.0, and blocking non-specific binding immunoglobulins with 10% non-specific rabbit serum in TRIS/BSA. After incubation with the bio-

**Table 1** Clinical and autoptical data from cases following TBI (BSF basal skull fracture, CF calvarial fracture, CLL chronic lymphocytic leukemia, DAI diffuse axonal injury, EDH epidural hemorrhage, ICH intracerebral hemorrhage, ICP intracranial pressure,

*l* left, *l/r* left and right, *Preg.* pregnancy, *r* right, *Res* resuscitation, *SAH* subarachnoidal hemorrhage, *SDH* subdural hemorrhage, *TBI* traumatic brain injury, *temp* temporal *Trep.* trepanation)

Case	Age (years)	Sex	Survival time	Trauma	Lesion	Cause of death	Additional clinical and autoptical data
1	64	M	0 h	Traffic	Frontoparietal l/r	Disruption of brain stem	CF, BSF, enterorrhexis
2	54	F	0 h	Traffic	Frontotemporal l/r	Severe TBI	CF, BSF, multiple skeletal fractures
3	57	M	0 h	Traffic	Frontotemporal l/r	Polytrauma	CF, BSF, SAH, hepatorrhexis
4	49	M	1 h	Fall	Frontobasoparietal	Asystole	DAI
5	24	M	1.5 h	Traffic	Frontobasal l	Polytrauma	Hepatorrhexis, hemorrhagic pleurorrhea
6	63	F	5.7 h	Traffic	Frontoparietal l/r	Polytrauma	BSF, SDH, SAH, hemorrhagic pleurorrhea
7	27	F	< 6 h	Traffic	Frontal l/r	Herniation	SDH, Trep., DAI
8	36	M	< 6 h	Fall	Frontobasal l	Herniation	SAH
9	43	M	< 6 h	Fall	Frontotemporal l/r	Herniation	Chronic alcoholism
10	26	F	12 h	Traffic	Frontobasal l	Hemorrhagic shock	Polytrauma
11	28	M	14 h	Traffic	Frontotemporal l	Hemorrhagic shock	SAH, DAI, anoxic encephalopathy
12	52	M	12–24 h	Fall	Frontal r	Herniation	SDH
13	48	F	36 h	Fall	Frontal l/r	Herniation	SDH, DAI
14	64	M	48 h	Fall	Parietotemporal r	Severe brain edema	CF, BSF, SAH, DAI, Trep., liver cirrhosis
15	79	M	72 h	Fall	Frontotemporal l	Herniation	SDH, Trep., cerebral infarction cysts, DAI
16	30	F	72–96 h	Fall	Frontotemporal l	Herniation	Preg., fistula of cavernous sinus, DAI
17	55	M	8 days	Traffic	Frontotemporal l/r	Anoxic encephalopathy	CF
18	41	M	10 days	Traffic	Frontotemporal l/r	Contusion of brain stem	CF, DAI
19	87	M	14 days	Fall	Frontobasal l/r	ICB	SAH, SDH, CF, ischemia 48–72 h
20	83	M	14 days	Traffic	Temporobasal r	Pneumonia	SDH, Trep., hematoma 48–72 h, CLL
21	80	F	15 days	Traffic	Temporal l/r	Herniation	CF, DAI
22	18	F	16 days	Traffic	Frontotemporal l/r	Multiple-organ failure	Polytrauma, SAH, Trep., Res. anoxic encephalopathy
23	53	M	21 days	Fall	Parietal l	Pneumonia	EDH, CF, Trep., ischemia 4 days
24	56	F	6 months	Traffic	Frontobasal l	Pneumonia	SDH, CF, ischemia, hemiplegia



**Fig. 1** Number of AIF-1+ and MRP8+ cells per HPF in relation to survival time in different brain regions following TBI (HPF high-power field, TBI traumatic brain injury, d day, m month, AIF-1 allograft inflammatory factor, MRP8 macrophage-related protein-8)

tinylated secondary antibody (rabbit anti-mouse) sections were developed with avidin and biotinylated alkaline phosphatase reagents (ABC/AP; Dako) and stained with Fast-Blue BB salt (Sigma, Deisenhofen, Gennany). Following a second microwave pre-treatment to denature bound antibody molecules, and thereby completely blocking cross-reactivity between sequential rounds of staining [14], the second primary antibody (AIF-1) was added, followed by incubation as described above and development with Strept ABC/HRP and visualized with DAB as chromogen. As MRP8 is a biotinylated primary antibody, no secondary antibody is needed when this is applied as first primary antibody.

#### Evaluation

For evaluation of glial reaction the average quantity of immunoreactive cells per high-power field (HPF; 0.0625 mm<sup>2</sup>) was determined. For this, total number of immunolabeled cells (AIF-1<sup>+</sup> or MRP8<sup>+</sup>) in ten HPFs was divided by 10 and the result rounded to the next integer. Only cells with processes (ramified or amoeboid) were counted to exclude blood-derived monocytes/macrophages. In all brain regions, except the brain stem, grey and white matter were examined separately.

#### Statistical analysis

Data were plotted on a logarithmic scale, after adding the constant value one to the number of immunolabeled cells (AIF-1<sup>+</sup> or MRP8<sup>+</sup>) per HPF and to the survival time to handle zero values, e.g., [log {number of AIF-1<sup>+</sup> cells/HPF + 1} vs log {survival time (h) + 1}].

To examine, whether or not the number of AIF-1<sup>+</sup> cells/HPF is associated with survival times in any of the examined regions following TBI, linear regression lines were calculated. For the density of MRP8<sup>+</sup> cells the threshold value was determined, logT50 representing the moment at which 50% of the maximum value was reached.

To analyze the differences in the density of immunolabeled cells (AIF-1<sup>+</sup> or MRP8<sup>+</sup>) between the examined brain regions following TBI, zero values were excluded and a conditional comparison was performed by paired *t*-test.

To verify whether or not the density of AIF-1<sup>+</sup> cells following TBI differs from controls a two-sample *t*-test was used. To exclude possible topographic differences in the density of microglia in human brains, we compared data from tissue sections obtained from frontal lobe (*n* = 15) and brain stem (*n* = 24) after TBI with data from corresponding regions of controls (*n* = 20).

## Results

#### Control cases

In control brains immunoreactivity for AIF-1 was seen in cells with delicate processes (Fig. 2a) in various brain regions. The number of AIF-1<sup>+</sup> microglial cells per HPF

showed distinct variability, both in controls and following TBI. MRP8 was not detectable in ramified cells. Only intravascular round cells expressed MRP8<sup>+</sup>.

#### Cases with TBI

Results of immunolabelings for AIF-1 and MRP8 are summarized in Fig. 1 and Table 2. AIF-1 immunoreactivity was detected in ramified/amoeboid cells in various numbers in all brain regions. After TBI, AIF-1 was expressed in microglial cells as well as in round cells in the perivascular space and in hemorrhages. The number of AIF-1<sup>+</sup> microglial cells varied from case to case and in different brain regions. In the early phase following TBI ( $\leq 3$  days) AIF-1 was found to be colocalized with CD68 in microglial cells (Fig. 2b). In these cases immunoreactivity for MRP8 was not detectable in CD68<sup>+</sup> microglia. As in controls, only intravascular round cells were immunolabeled for MRP8 in the early phase post trauma. In cases who survived TBI for more than 3 days, increasing numbers of round cells with macrophage-like morphology appeared at the hemorrhagic lesion, showing mainly intense immunoreactivity for both CD68 and MRP8. In this region only part of the ramified and amoeboid cells expressed AIF-1 (Fig. 2c, d). At later stages ( $> 3$  days) MRP8 was detected in microglial cells remote from the lesion and in the brain stem. In contrast, in all other brain regions examined, distinct AIF-1 immunoreactivity was observed in microglia (Fig. 2e).

#### Statistical analysis

##### Expression of AIF-1

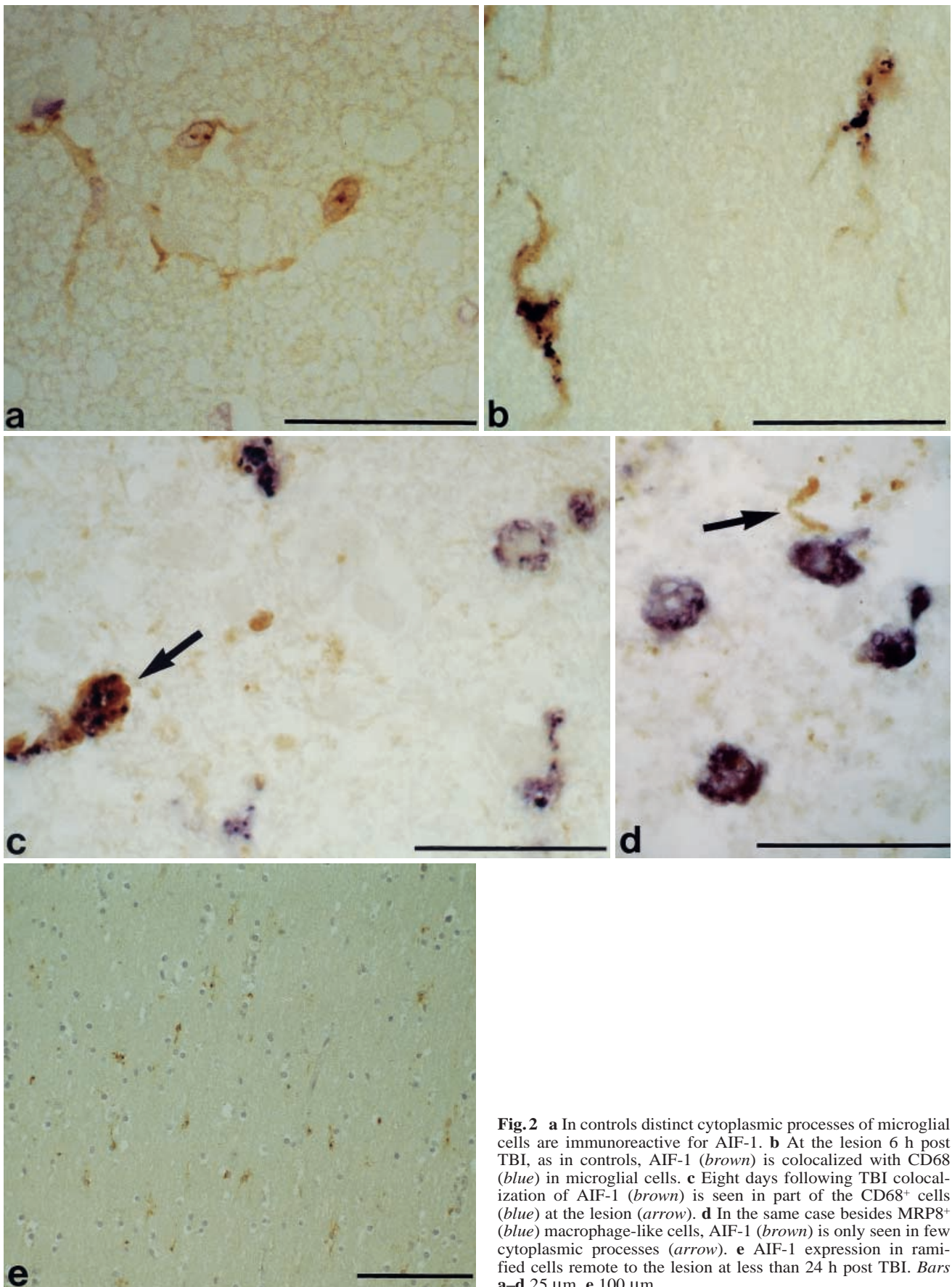
Increasing survival times following TBI were not accompanied by a significant increase in the density of AIF-1<sup>+</sup> cells, neither at the lesion, nor at any other brain region examined (Fig. 3,  $P > 0.16$ ).

Mean values of immunolabeled cells in different brain regions are listed in Table 2. Following TBI no significant differences in the density of AIF-1<sup>+</sup> microglia occurred between the lesion and remote areas ( $P > 0.22$ ). Among the examined brain regions significantly more AIF-1<sup>+</sup> cells occurred only in the brain stem when compared to adjacent white matter ( $P = 0.004$ ), adjacent grey matter ( $P >$

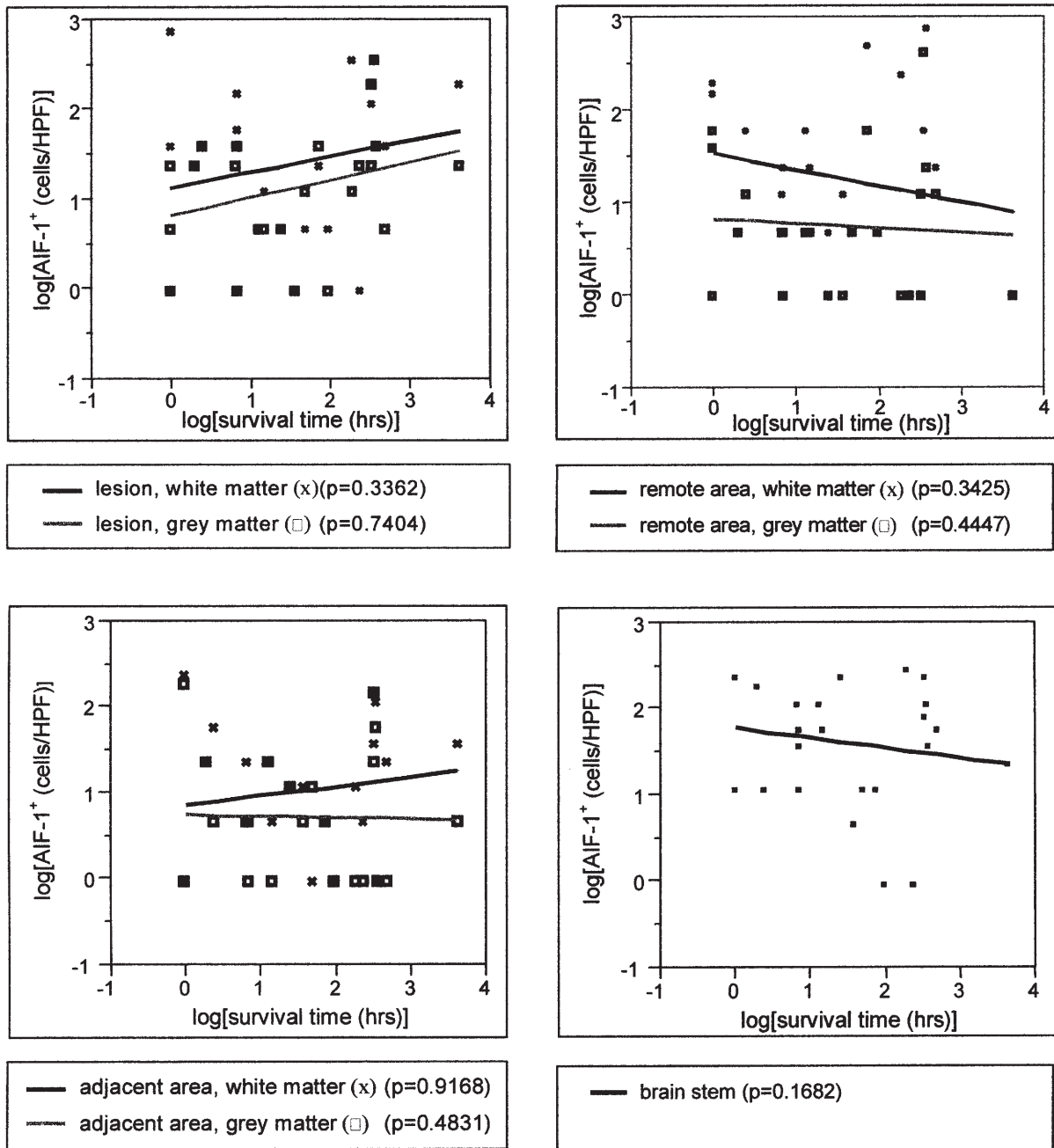
**Table 2** Means of AIF-1<sup>+</sup> or MRP8<sup>+</sup> cells and mean differences of AIF-1<sup>+</sup> and MRP8<sup>+</sup> cells per HPF in different brain regions following TBI (AIF-1 allograft inflammatory factor, MRP8 macrophage-related protein-8, HPF high-power field)

Brain region	Mean <sup>a</sup> of AIF-1 <sup>+</sup> cells	Mean <sup>a</sup> of MRP8 <sup>+</sup> cells	Mean <sup>a</sup> difference of AIF-1 <sup>+</sup> and MRP8 <sup>+</sup> cells	<i>P</i> *
Lesion, grey matter	1.12	3.25	0.853	< 0.0001
Lesion, white matter	1.39	2.87	0.458	< 0.0002
Adjacent area, grey matter	0.73	2.68	0.541	0.158
Adjacent area, white matter	1.03	2.42	0.341	0.026
Remote area, grey matter	0.75	2.08	0.298	0.234
Remote area, white matter	1.27	1.59	0.028	0.846
Brain stem	1.61	1.99	0.308	0.027

<sup>a</sup> mean of log (number of immunoreactive cells per HPF)  
\* Probability of higher numbers of MRP8<sup>+</sup> than AIF-1<sup>+</sup> cells per HPF



**Fig. 2** **a** In controls distinct cytoplasmic processes of microglial cells are immunoreactive for AIF-1. **b** At the lesion 6 h post TBI, as in controls, AIF-1 (brown) is colocalized with CD68 (blue) in microglial cells. **c** Eight days following TBI colocalization of AIF-1 (brown) is seen in part of the CD68<sup>+</sup> cells at the lesion (arrow). **d** In the same case besides MRP8<sup>+</sup> (blue) macrophage-like cells, AIF-1 (brown) is only seen in few cytoplasmic processes (arrow). **e** AIF-1 expression in ramified cells remote to the lesion at less than 24 h post TBI. Bars a–d 25  $\mu$ m, e 100  $\mu$ m



**Fig.3** Number of AIF-1+ microglial cells per HPF in relation to survival time and probability of significant increases in the density of AIF-1+ cells in different regions of the brain following TBI

0.05) and remote grey matter ( $P > 0.05$ ) and in the white matter at the lesion in comparison to adjacent grey matter ( $P > 0.05$ ), according to a known higher density of microglial cells in the white matter/brain stem than in grey matter regions [17, 27].

Analysis of AIF-1+ expression in corresponding brain regions (sections taken from frontal lobe and brain stem) following TBI and in controls showed no significant differences in the density of AIF-1+ cells (Table 3;  $P \geq 0.20$ ).

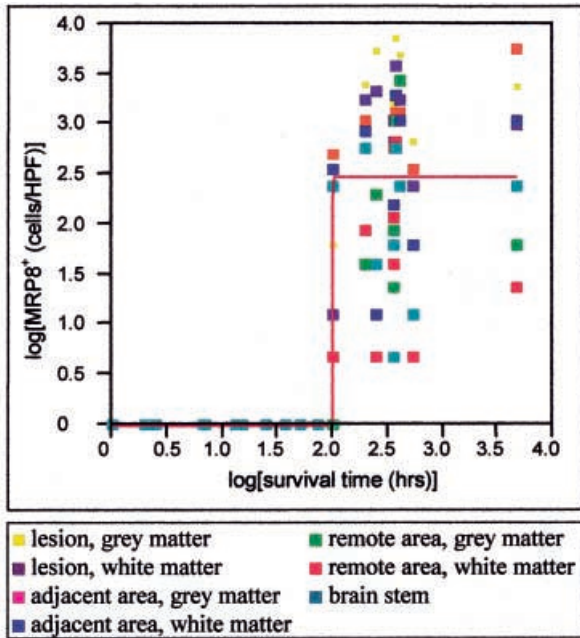
*Expression of MRP8*

In contrast to AIF-1, the density of MRP8+ cells increased suddenly between 72 h (case 16) and 96 h (case 17) in all brain regions (Fig. 4). Only in the remote grey matter was a sudden increase in the density of MRP8+ microglia delayed, starting between 96 h (case 17) and 168 h (case 18).

In later stages after TBI ( $> 3$  days) significantly  $P < 0.05$ ) higher numbers of microglial cells expressed MRP8 in the grey matter at the lesion than in the remote grey matter, remote white matter and brain stem. Significantly ( $P < 0.05$ ) more MRP8+ cells were also detected in white matter at the lesion and grey matter adjacent to the lesion in comparison to remote white matter.

**Table 3** Median number of AIF-1<sup>+</sup> microglial cells in ten HPF in frontal grey and white matter, and in the brain stem following TBI and in controls (*n* number of cases examined)

	TBI			Controls		
	Frontal lobe grey matter	Frontal lobe white matter	Brain stem	Frontal lobe grey matter	Frontal lobe white matter	Brain stem
<i>n</i>	15	15	24	20	20	20
Range	0–4	1–6	1–8	1–2	2–4	2–6
Median	1.4	3.1	2.5	1.3	2.7	3.2



**Fig. 4** Number of MRP8<sup>+</sup> microglial cells per HPF in relation to survival time after TBI (all brain regions)

#### Expression of AIF-1 versus MRP8

Significantly more MRP8<sup>+</sup> cells were found in the grey ( $P \leq 0.0001$ ) and white matter ( $P \leq 0.0002$ ) at the lesion, in the adjacent white matter ( $P = 0.0261$ ) and in the brain stem ( $P = 0.0274$ ). No significant differences ( $P > 0.15$ ) occurred in the other brain regions examined (Table 2).

#### Discussion

In the CNS expression of AIF-1 (identical to microglial response factor-1 and ionized calcium-binding adaptor molecule-1) was found to be restricted to microglia alone, both in cultured brain cells and in rat brain, respectively [11, 12]. In experimental models of inflammation [3, 25] and neuronal degeneration [7, 12, 28] in rat CNS as well as in human cerebral infarctions [21] an up-regulation of AIF-1 was observed. In experimental autoimmune diseases, expression of AIF-1 was shown to be modulated by immunotherapy, indicating an association of increased AIF-1 expression with microglial activation [26].

Following human TBI, the density of AIF-1<sup>+</sup> microglial cells did not correlate with survival time, neither at the lesion, nor at any other brain region examined (Fig 3,  $P \geq 0.16$ ). This is in contrast to experimental data following axotomy [7, 12, 28], in which AIF-1 was reported to be up-regulated in microglial cells surrounding injured central motor neurons and to peak at 7 days post injury [12] in rats. In human cerebral infarctions Postler et al. [21] observed both, an increase in the intensity of immunoreactivity and in the density of AIF-1<sup>+</sup> cells, including ramified/amoeboid and round cells. Although in the present study only ramified/amoeboid cells were considered, our data demonstrate a differential expression pattern of microglia following human TBI and cerebral infarction. This observation was supported by the analysis of MRP8-expressing microglia. As previously described by Engel et al. [5] no MRP8<sup>+</sup> microglia were seen in the first 3 days post TBI, as in controls, whereas after 3 days the number of MRP8<sup>+</sup> microglia increased strikingly in all brain regions examined and remained elevated at all time points investigated (Fig. 4). Following human cerebral infarctions, in contrast, an early onset of MRP8 expression in microglia was reported that declined within the first days and was no longer detectable by 3 days post infarction [20].

Furthermore, at the lesion or in the perilesional (adjacent) tissue no significantly higher density of AIF-1<sup>+</sup> cells occurred in comparison to remote areas, indicating a different pattern of microglial activation following TBI and ischemia in humans. In both, brains following TBI and unaffected controls, the variability in the density of AIF-1<sup>+</sup> cells was high, not showing significant differences in corresponding brain regions between TBI and controls (Table 3;  $P \geq 0.2$ ). Regular AIF-1 immunoreactivity of ramified cells in controls indicated constitutive expression of AIF-1 in a subset of human microglia, which corresponds to the findings of Postler et al. [21]. Following TBI increasing numbers of CD68<sup>+</sup> and MRP8<sup>+</sup> microglia/macrophages appeared at the lesion. Double immunolabeling showed that only some of the CD68<sup>+</sup> or MRP8<sup>+</sup> microglia/macrophages coexpressed AIF-1. Thus, AIF-1 was expressed only in a subset of microglia/macrophages after human TBI.

The concentration of intracellular Ca<sup>2+</sup> ( $[Ca^{2+}]_i$ ) is known to change following tissue damage and to be associated with modification of gene transcription [6, 18, 19, 22, 23]. The differential expression pattern of the two Ca<sup>2+</sup>-binding peptides AIF-1 and MRP8 in human microglia following TBI indicates that modification of

[Ca<sup>2+</sup>]<sub>i</sub> alone is not sufficient to stimulate protein production. These data are in accordance with previous studies reporting a delayed activation of microglia following TBI, both by immunohistochemistry [4, 5, 9] and at the mRNA level [10].

In conclusion the present study shows that in human brains AIF-1 is expressed in a subset of microglial cells and is not noticeably up-regulated following TBI. In contrast, MRP8 is strikingly up-regulated in microglia in all brain regions post TBI after 3 days. AIF-1 possibly characterizes a subpopulation of microglial cells, that shows a different activation potential following human TBI in contrast to human cerebral infarctions.

**Acknowledgement** This study was supported by a grant of the German Ministry of Education, Science, Research and Technology (BMBF; 01K0 9809/8).

## References

- Abe M, Umehara F, Kubota R, Moritoyo T, Izumo S Osame M (1999) Activation of macrophages microglia with the calcium-binding proteins MRP14 and MRP8 is related to the lesional activities in the spinal cord of HTLV-I associated myelopathy. *J Neurol* 246: 358–464
- Autieri MV (1996) cDNA-cloning of human allograft inflammatory factor-1: tissue distribution, cytokine induction and mRNA-expression in injured rat carotid arteries. *Biochem Biophys Res Commun* 228: 29–37
- Chen ZW, Ahren B, Östenson, Cintra A, Bergmam T, Möller C, Fuxe K, Mutt V, Efendic S (1997) Identification, isolation and characterization of daintain (allograft inflammatory factor-1), a macrophage polypeptide with effects on insulin secretion and abundantly present in the pancreas of prediabetic BB rats. *Proc Natl Acad Sci USA* 94: 13 879–13 884
- Engel S, Wehner H-D, Meyermann R (1996) Expression of microglial markers in the human CNS after closed head injury. *Acta Neurochir (Wien) Suppl* 66: 89–95
- Engel S, Schluesener HJ, Mittelbronn M, Seid K, Adjodah D, Wehner H-D, Meyermann R (2000) Dynamics of microglial activation after human traumatic brain injury are revealed by delayed expression of macrophage related proteins. *Acta Neuropathol* (in press)
- Gilchrist JS, Czubyrt MP, Pierce GN (1994) Calcium and calcium-binding proteins in the nucleus. *Mol Cell Biochem* 135: 79–88
- Graeber MB, Lopez-Redondo F, Ikoma E, Ishikawa M, Imai Y, Nakajima K, Kreutzberg GW, Kohsaka S (1998) The microglia/macrophage response in the neonatal rat facial nucleus following axotomy. *Brain Res* 813: 241–253
- Graham DI, Gennarelli TA (1997) Trauma. In: Graham DI, Lantos PL (eds) *Greenfield's neuropathology* 6th edn. Arnold, London, pp 197–262
- Holmin S, Schalling M, Hojeberg B, Nordquist AC, Skeftruna AK, Mathiesen T (1997) Delayed cytokine expression in rat brain following experimental contusion. *J Neurosurg* 86: 493–504
- Holmin S, Sonderlund J, Biberfeld P, Mathiesen T (1998) Intracerebral inflammation after human brain contusion. *Neurosurgery* 42: 291–298
- Imai Y, Ibata I, Ito D, Ohsawa K, Kohsaka S (1996) A novel gene iba-1 in the major histocompatibility complex class III region encoding an EF hand protein expressed in a monocytic lineage. *Biochem Biophys Res Commun* 225: 855–862
- Ito D, Imai Y, Ohsawa K, Nakajima K, Fukuuchi Y, Kohsaka S (1998) Microglia-specific localisation of a novel calcium binding protein, ibal. *Brain Res Mol Brain Res* 57: 1–9
- Lagasse E, Weissman IL (1992) Mouse MRP8 and MRP14, two intracellular calcium-binding proteins associated with the development of the myeloid lineage. *Blood* 8: 1907–1915
- Lan HY, Mu W, Nikolic-Paterson DJ, Atkins RJ (1995) A novel simple, reliable, and sensitive method for multiple immunoenzyme staining: use of microwave oven heating to block antibody crossreactivity and retrieve antigens. *J Histochem Cytochem* 43: 97–102
- Lugering N, Kucharzik T, Stoll R, Domschke W (1998) A system of nonspecific defense in chronic inflammatory bowel diseases – pathophysiologic and therapeutic aspects. *Z Gastroenterol* 36: 173–187
- Mahnke K, Bhardwaj R, Sorg C (1995) Heterodimers of the calcium-binding proteins MRP8 and MRP14 are expressed on the surface of human monocytes upon adherence to fibronectin and collagen: relation to TNF-alpha, IL-6 and superoxide production. *J Leukoc Biol* 57: 63–71
- Mattiace LA, Davies P, Dickson DW (1990) Detection of HLA-DR on microglia in the human brain is a function of both clinical and technical factors. *Am J Pathol* 136: 1101–1114
- McLarnon JG, Xu R, Lee YB, Kim SU (1997) Ion channels in human microglia in culture. *78: 1217–1228*
- Möller T, Nolte C, Burger R, Verkhratsky A, Kettenmann H (1997) Mechanisms of C5a and C3a complement fragment-induced [Ca<sup>2+</sup>]<sub>i</sub> signaling in mouse microglia. *J Neurosci* 17: 615–624
- Postler E, Schluesener HJ, Meyermann R (1997) Expression of the S-100 proteins MRP-8 and -14 in ischemic brain lesions. *Glia* 19: 27–34
- Postler E, Rimner A, Beschorner R, Schluesener HJ, Meyermann R (2000) Allograft-inflammatory-factor-1 is upregulated in microglial cells in human cerebral infarctions. *J Neuroimmunol* 104: 85–91
- Roche E, Prentki M (1994) Calcium regulation of immediate early response genes. *Cell Calcium* 16: 331–338
- Roth J, Goebler M, Wrocklage V, Van den Bos C, Sorg C (1994) Expression of the calcium-binding proteins MRP8 and MRP14 in monocytes is regulated by a calcium induced suppressor mechanism. *Biochemistry* 301: 655–660
- Schafer BW, Heizman CW (1996) The S100-family of EF-hand calcium-binding proteins: functions and pathology. *Trends Biochem Sci* 21: 134–140
- Schluesener HJ, Seid K, Kretzschmar J, Meyermann R (1998) Allograft-inflammatory factor in rat experimental autoimmune encephalomyelitis, neuritis and uveitis: expression by activated macrophages and microglial cells. *Glia* 24: 244–251
- Schluesener HJ, Seid K, Meyermann R (1999) Effects of autoantigen and dexamethasone treatment on expression of endothelial-monocyte activating polypeptide II and allograft-inflammatory factor-1 by activated macrophages and microglial cells in lesions of experimental autoimmune encephalitis, neuritis and uveitis. *Acta Neuropathol* 97: 119–126
- Streit WJ (1995) Microglial cells. In: Kettenmann H, Ranson BR (eds) *Neuroglia*. Oxford University Press, Oxford, pp 85–96
- Tanaka S, Suzuki K, Watanabe M, Matsuda A, Tone S (1998) Upregulation of a new microglial gene mrf-1, in response to programmed neuronal death and degeneration. *J Neurosci* 18: 6258–6369
- Utans U, Arci RJ, Yamashita Y, Russell ME (1995) Cloning and characterisation of allograft inflammatory factor-1: a novel macrophage factor identified in rat cardiac allografts with chronic rejection. *J Clin Invest* 95: 2954–2962
- Utans U, Quist WC, McManus BM, Wilson JE, Arci RJ, Wallace AF, Russell ME (1996) Allograft inflammatory factor: a cytokine-responsive macrophage molecule expressed in transplanted human hearts. *Transplantation* 61: 1387–1392
- Wege H, Schluesener H, Meyermann R, Barac-Latas V, Suchanek G, Lassmann H (1998) Coronavirus infection and demyelination. Development of inflammatory lesions in Lewis rats. *Adv Exp Med Biol* 440: 437–444