



Correction to: Quantifying the extent of fistulotomy. How much sphincter can we safely divide? A three-dimensional endosonographic study

Marina Garcés-Albir¹ · Stephanie Anne García-Botello¹ · Pedro Esclapez-Valero¹ · Angel Sanahuja-Santafé¹ · Juan Raga-Vázquez¹ · Alejandro Espi-Macías¹ · Joaquín Ortega-Serrano¹

Published online: 22 June 2019
© Springer-Verlag GmbH Germany, part of Springer Nature 2019

Correction to: *Int J Colorectal Dis* (2012) 27:1109–1116
<https://doi.org/10.1007/s00384-012-1437-3>

In the Figure 1 of the original published version of this article the numbers were switched. The number of **Intersphincteric Fistulas** should be **n=12** and of **Low Transphincteric Fistulas** should be **n=23**. Accordingly, in the text of Results section, lines 5 and 6 the numbers were also interchanged. The respective text in the result part should be changed to “**The low transphincteric fistula was the most common type (23 cases) followed by intersphincteric tracts (12 cases) as shown in Fig. 1.**”

The online version of the original article can be found at <https://doi.org/10.1007/s00384-012-1437-3>

✉ Marina Garcés-Albir
garalma@hotmail.com

Stephanie Anne García-Botello
stephaniegarcia@telefonica.net

Pedro Esclapez-Valero
pedro.esclapez@uv.es

Angel Sanahuja-Santafé
coloproc_hcv@gva.es

Juan Raga-Vázquez
juanragavazquez@hotmail.es

Alejandro Espi-Macías
alejandro.espi@uv.es

Joaquín Ortega-Serrano
joaquin.ortega@uv.es

¹ Department of General and Digestive Surgery, Colorectal Unit, Hospital Clínico Universitario, HCUV. Avd. Blasco Ibañez, 17, 46010 Valencia, Spain

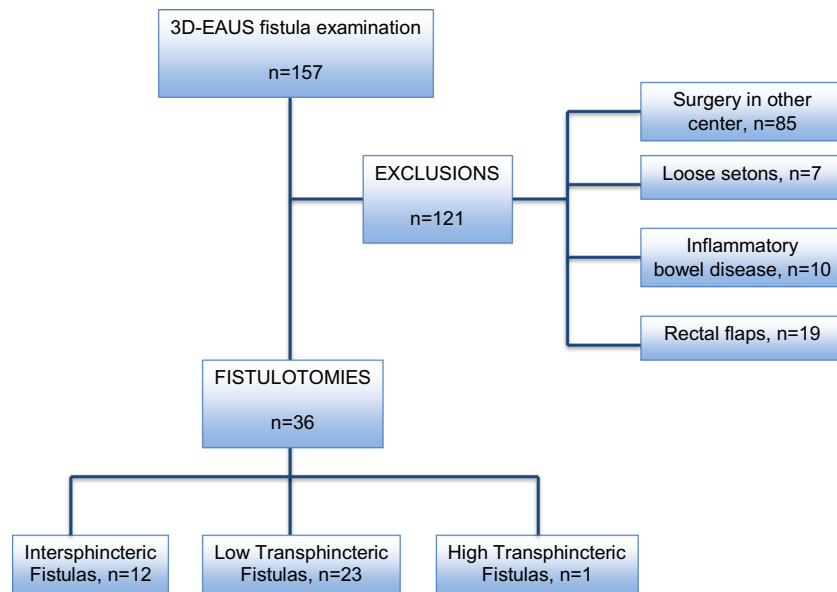


Fig. 1 Distribution of patients

Publisher's note Springer Nature remains neutral with regard to jurisdictional claims in published maps and institutional affiliations.