

R. J. P. Körver
P. H. M. H. Theunissen
W. T. van de Kreeke
M. J. A. van der Linde
I. C. Heyligers

Juxta-articular myxoma of the knee in a 5-year-old boy: a case report and review of the literature (2009: 12b)

Received: 7 April 2009
Revised: 15 May 2009
Accepted: 22 May 2009
© The Author(s) 2010.
This article is published with open access at
Springerlink.com

R. J. P. Körver (✉) ·
M. J. A. van der Linde · I. C. Heyligers
Department of Orthopaedic Surgery,
Atrium Medical Center Parkstad
Heerlen,
Henri Dunantstraat 5,
6419, PC, Heerlen, The Netherlands
e-mail: rob.korver@zonnet.nl
Tel.: +31-45-5766747
Fax: +31-45-5766576

M. J. A. van der Linde
e-mail: mle01@atriummc.nl

I. C. Heyligers
e-mail: ihs01@atriummc.nl

P. H. M. H. Theunissen
Department of Pathology, Atrium
Medical Center Parkstad Heerlen,
Henri Dunantstraat 5,
6419, PC, Heerlen, The Netherlands
e-mail: ptn02@atriummc.nl

W. T. van de Kreeke
Department of Radiological Sciences,
Atrium Medical Center Parkstad
Heerlen,
Henri Dunantstraat 5,
6419, PC, Heerlen, The Netherlands
e-mail: wke01@atriummc.nl

Abstract Juxta-articular myxoma
(JAM) is a relatively rare variant of
myxoma that occurs in the vicinity of

large joints. It is composed of fibroblast-like cells that produce an excessive amount of glycosaminoglycans rich in hyaluronic acid. The peak incidence is between the 3rd and 5th decades of life. In this report we describe an extremely rare case of JAM in the knee of a 5-year-old child. The clinical presentation, radiological features and histopathologic findings are described, and the relevant literature is reviewed.

Keywords Juxta-articular myxoma · Myxoma · Knee · Preschool child · MRI · Differential diagnosis

Introduction

Juxta-articular myxoma is an uncommon benign lesion that is seen with a peak incidence between the 3rd and 5th decades of life [1]. It seems to be composed of fibroblast-like cells that produce excessive amounts of glycosaminoglycans rich in hyaluronic acid. In the literature, the youngest patient reported was 9 years of age [2, 17]. In this case report we describe a juxta-articular myxoma of the knee in a 5-year-old patient.

Case presentation

A 5-year-old boy presented in our Orthopaedic Out-patient Department with a palpable mass on the medial side of the right knee proximal to the knee joint. The mass had first been detected by the boy's mother 4 weeks earlier. The history did

not reveal any trauma or other cause. Furthermore, the boy denied mechanical symptoms of locking, giving way, redness or warmth. The range of motion was unimpaired, and he had not experienced pain. The patient participated in sports and all normal daily activities suitable for his age. The physical and psychological development was normal, and there was no significant family, past medical or surgical history. Physical examination revealed a normal build, non-obese boy with an abnormal contour near his right knee. The mass was located underneath the vastus medialis muscle. Both lower extremities had an excellent joint stability and a normal range of motion. The palpable mass had a smooth surface and could be moved with regard to the underlying tissue. Palpation did not cause pain, and there was no associated hydrops, erythema or signs indicating neurovascular compromise distal to the mass.

Magnetic resonance imaging (MRI) of the affected knee showed a well-defined, heterogeneous and extra-articular mass measuring 4.0×3.0×2.0 cm near the medio-distal

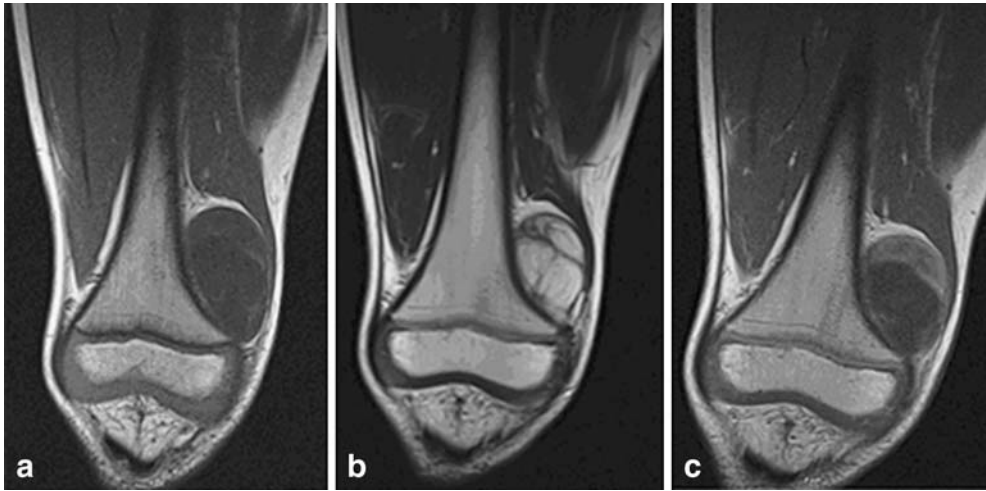

Fig. 1 a, b, c MR images show a mass near the medial metaphysis of the right knee, measuring $4.0 \times 3.0 \times 2.0$ cm, which displaces the distal part of the vastus medialis muscle to medio-cranial. **a** Coronal T1-weighted MR image shows a mass, hypointense to muscle and with a low signal intensity core. **b** On T2-weighted MR images, the

mass is hyperintense to muscle and isointense to fat. The multiple septa are clearly visible. **c** Intravenous admission of gadolinium shows markedly increased signal intensity of the thickened wall and septa without enhancement of the core

femoral metaphysis (Fig. 1). The lesion did not infiltrate adjacent bone, muscles, vessels or nerves. The distal part of the vastus medialis muscle was displaced to medio-cranial. On T1-weighted images, the lesion was hypointense to muscle with a low signal intensity core, a thickened wall and multiple septa that both had a slightly higher signal intensity. Using gadolinium-enhanced MR the thickened wall and septa became markedly enhanced without enhancement of the core. T2-weighted sequences of the lesion showed an evident high signal intensity, being hyperintense to fat, as well as multiple septa. No further abnormalities could be seen on the MR images.

Plain radiographs (Fig. 2) of the right knee showed soft tissue expansion at the medio-distal femoral condyle near the metaphysis without calcifications or bony abnormalities, especially no cortical bone involvement.

The radiological differential diagnosis therefore included myxoma and myxoid liposarcoma, even though myxoid liposarcoma is extremely rare in children younger than 16 years (0.6% of the cases of myxoid liposarcoma) [3]. Other extra-articular soft tissue tumors, including meniscus cyst and ganglion cyst, were also considered. The lesion's extra-articular location, its clinical presentation and defined MR characteristics excluded an abscess, a giant cell tumor of the tendon sheath (GCTTS), pigmented villonodular synovitis (PVNS) and synovial hemangioma.

An open biopsy was performed. During this surgical procedure the tumor capsule was cleft, and a tissue specimen measuring $1.0 \times 1.0 \times 0.5$ cm was excised. Histological examination of the specimen turned out to be inconclusive because the biopsy did not show representative tissue.

The patient underwent an open arthrotomy and excision of the mass. During the procedure, the well-circumscribed, encapsulated mass could be easily located underneath the distal part of the vastus medialis muscle. Because the tumor wall was fused to the patello-femoral joint capsule, the knee joint had to be opened to excise the lesion completely.

On cut section the lesion appeared to be glass-like and multicystic, measuring 3.5 cm in diameter (Fig. 3). Microscopic examination (Fig. 4) showed a partly solid

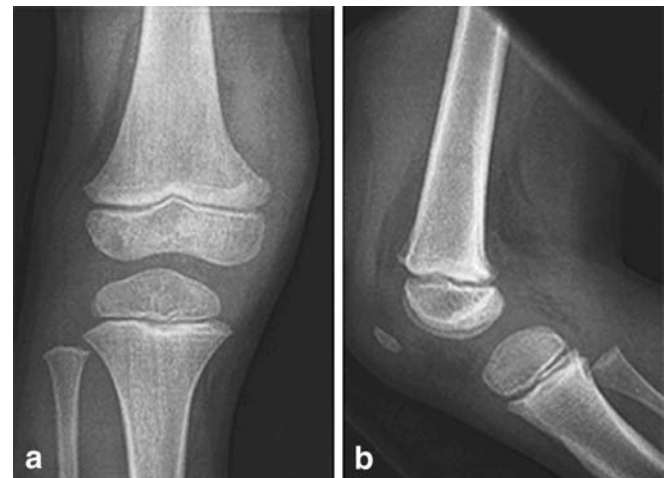
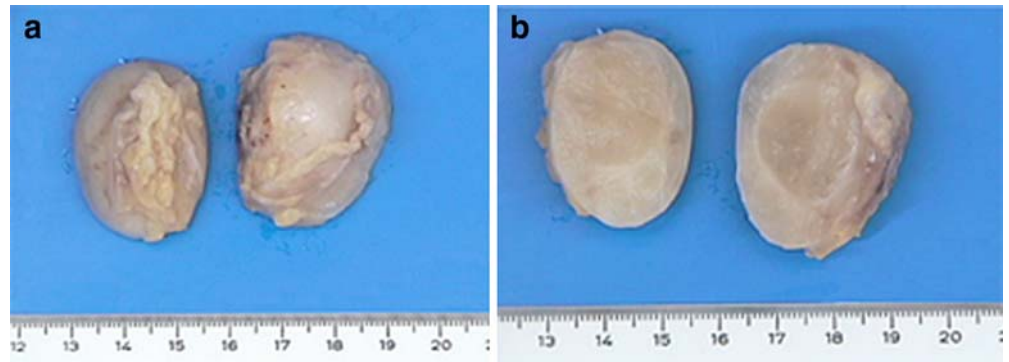


Fig. 2 a, b Radiographs of the right knee. **a** Antero-posterior radiograph shows soft tissue expansion at the medio-distal femoral condyle near the metaphysis without calcifications or bony abnormalities, especially no cortical bone involvement. **b** Lateral radiograph does not show any abnormalities

Fig. 3 a, b Macroscopic view of the tumor with a glassy appearance. **a** Exterior view. **b** Cut surface



and a partly cystic mesenchymal process encapsulated by fibrous connective tissue. The cell-poor process was homogeneously composed of abundant myxoid stroma containing variously sized cystic spaces with few small blood vessels. The monomorphic spindle-shaped cells, containing small uniform nuclei, were sparsely scattered throughout the myxoid matrix. Juxta-articular myxoma was diagnosed.

The knee function was somewhat restricted after the surgical procedure due to the pain. One month after surgery the patient went to the physiotherapist to regain the full range of motion in his knee joint. Within a few weeks after the first visit he was able to use his knee joint without any constraint. At 10-month follow-up, the patient did not experience any complaints, and no signs of recurrence were present.

Discussion

Juxta-articular myxoma (JAM) is a relatively rare variant of myxoma that occurs in the vicinity of large joints, especially around the knee (88%), and is considered

benign [1, 4, 6]. The shoulder, elbow, ankle and hip joints are affected in a minority of cases. The incidence of this lesion is highest in males between their 3rd and 5th decades of life [1, 2, 4]. In the literature, the youngest patient reported was 9 years of age [2].

Despite most JAMs tending to occur primarily in the subcutaneous adipose tissue, simultaneous involvement of the adjacent dermis, joint capsule, tendons or meniscus is, like in our case, common [1]. Most lesions present as a palpable swelling or mass, sometimes associated with pain or tenderness. Although their size usually varies from 2.0 to 6.0 cm, some may enlarge very rapidly, reaching 12 cm at the time of excision [1, 2, 4, 5, 6]. The pathogenesis is not clear, but trauma, for instance meniscal tear, and osteoarthritis may play a significant role in the development of JAM. This could also be an explanation for its predilection to occur around the knee [1, 6]. Optimal treatment consists of complete excision of the primary lesions and local recurrences. In over one third of cases (34%), the lesion recurs after surgical excision, sometimes on multiple occasions [1].

Although the majority of JAMs are correctly diagnosed as benign, in a substantial number of cases (23% in the

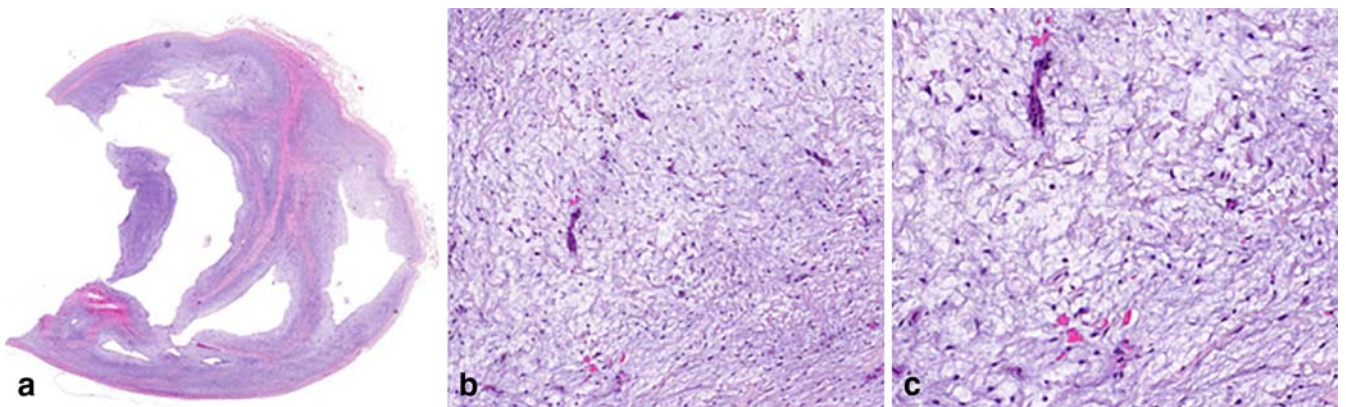


Fig. 4 a Microscopic features of the cell-poor process with abundant myxoid stroma (H&E, $\times 20$). The higher magnification shows monomorphic spindle-shaped cells containing small uniform nuclei **b** (H&E, $\times 100$), **c** (H&E, $\times 250$)

largest series), sarcoma is frequently considered or diagnosed, especially a myxoid liposarcoma [1, 2, 6]. Although all soft tissue myxomas are regarded as ‘probably nonneoplastic’ according to the WHO definition, Sciote et al. [7] presented a case of JAM with clonal chromosomal changes, suggesting that at least some of these lesions are neoplastic in nature [8].

On gross pathological examination, most lesions appear mucoid, myxoid, gelatinous or slimy (77%) with a silvery or pearly white to yellow color [1, 2, 5]. Histologically, JAMs are composed of loosely arranged spindle-like cells in a hypovascular myxoid matrix, resembling an intramuscular myxoma [1, 6]. Furthermore, variously sized cystic spaces can be seen in nearly 90% of the cases; this feature may be related to degenerative changes caused by the constant motion, friction and torsion from the adjacent joint [1]. The unpretentious vascular network throughout the myxoid areas and the presence of multiple cystic spaces may account for the serpiginous pattern of enhancement and the areas of non-enhancement on MRI, respectively. Suspicion of a low-grade myxoid sarcoma in the presence of hypercellular areas can be aroused, but mitotic figures are absent [1, 6].

There is no clear description of the MRI appearances of JAM documented in the literature. Although histologically JAM and intramuscular myxoma appear similar, in some cases their characteristics on MR may differ [2]. In contrast, the JAM of this report showed MR features similar to intramuscular myxoma, which is supported by the results of King et al. [5]. Therefore, it can be stated that JAMs are well-circumscribed lesions tending to be hypointense to muscle on T1-weighted sequences and hyperintense to fat on T2-weighted images. Furthermore, heterogeneous enhancement of the core can be observed after intravenous gadolinium administration.

Myxomatous lesions around the knee, including ganglion cyst and meniscal cyst, are commonly encountered in patients of all age groups and comprise a diverse group of entities, ranging from benign cysts to complications of underlying diseases such as malignancy [1, 2, 5, 8–13].

Ganglion cysts are cystic, tumor-like lesions filled with gelatinous fluid rich in hyaluronic acid and other mucopolysaccharides [10]. Ganglia can present around the knee and may show a close resemblance to JAM. Although this resemblance is reinforced by the fact that JAM and ganglia both contain cystic spaces, ganglia have a much less developed, solid myxoid component and differ in their clinical presentation. They tend to occur predominantly on the dorsum of the wrist in young women and usually are much smaller in size [1, 10, 11].

Meniscal cysts are encapsulated accumulations of synovial fluid located in the medial or lateral joint that are within the meniscus (intrameniscal cyst) or extravasated through a meniscal tear into the surrounding soft tissues (parameniscal cyst) [10–12]. They are highly suggestive of an associated meniscal tear (98%), but have also been reported in the absence of a detectable tear (most likely due to a previously healed meniscal tear) [10, 11]. Even though medial and lateral meniscal tears occur with the same frequency, meniscal cysts were traditionally thought to be more common in the lateral femorotibial compartment, but additional literature shows an almost two times higher prevalence in the medial compartment (34% vs. 66%) [2, 10–12, 14]. Patients typically present with symptoms including swelling, palpable mass, pain and tenderness, or limited mobility. On MR imaging, a well-circumscribed cystic mass is seen, which may show septations with low signal intensity on T1-weighted images and increased signal intensity on T2-weighted images [10–12].

Myxoid liposarcoma is the second most common type of liposarcoma, occurring in 20.5% of the cases of liposarcoma with a peak incidence between the 3rd and 7th decade of life [9, 15]. Patients present with a painless, slowly growing, soft mass in the intermuscular fascial planes or deep-seated areas of their lower extremities [15, 16]. MR imaging demonstrates hyperintense foci within a hypointense mass on T1-weighted images and a high signal intensity on T2-weighted images with foci of intermediate signal intensity corresponding to fat [9, 16]. The degree of enhancement after gadolinium contrast depends on the level of cellularity and vascularity of the tumor. Myxoid liposarcomas show intense enhancement of 65–100% of the tumor volume in most cases [16].

Myxoid liposarcomas have distinct radiological features that help differentiate them from myxomas. First, myxoid liposarcomas show intense enhancement in most cases. Second, the high signal intensity from fatty foci on T1-weighted images is quite characteristic [16].

In summary, we have presented the case of a 5-year-old boy with a painless mass in the medio-distal aspect of his right knee. Excision biopsy of the mass revealed a juxta-articular myxoma. The differential diagnosis for such an intra- or periarticular mass should include ganglion, meniscal cyst and myxoid liposarcoma.

Open Access This article is distributed under the terms of the Creative Commons Attribution Noncommercial License which permits any noncommercial use, distribution, and reproduction in any medium, provided the original author(s) and source are credited.

References

1. Meis JM, Enzinger FM (1992) Juxta-articular myxoma: a clinical and pathologic study of 65 cases. *Hum Pathol* 23:639–646
2. Daluiski A, Seeger LL, Doberneck SA, Finerman GAM, Eckardt JJ (1995) A case of juxta-articular myxoma of the knee. *Skeletal Radiol* 24:389–391
3. Vocks E, Worret WI, Burgdorf WHC (2000) Myxoid liposarcoma in a 12-year-old girl. *Pediatr Dermatol* 17:129–132
4. Minkoff J, Stecker S, Irizarry J, Whiteman M, Woodhouse M (2003) Juxta-articular myxoma: a rare cause of painful restricted motion of the knee. *Arthroscopy* 19:6–13
5. King DG, Saifuddin A, Preston HV, Hardy GJ, Reeves BF (1995) Magnetic resonance imaging of juxta-articular myxoma. *Skeletal Radiol* 24:145–147
6. Weiss SW, Goldblum JR (2008) Benign soft tissue tumors and pseudotumors of uncertain type. In: Enzingers & Weiss's soft tissue tumors, 5th edn. Mosby 1075–1076
7. Sciot R, Dal Cin P, Samson I, Van den Berghe H, Van Damme B (1999) Clonal chromosomal changes in juxta-articular myxoma. *Virchows Archiv* 454:177–180
8. Bancroft LW, Kransdorf MJ, Menke DM, O'Connor MI, Foster WC (2002) Intramuscular myxoma: Characteristic MR imaging features. *Am J Roentgenol* 178:1255–1259
9. De Schepper AM, Vanhoenacker F, Gielen J, Parizel PM (eds) (2001) *Imaging of soft tissue tumors*, 3rd edn. Springer
10. Beaman FD, Peterson JJ (2007) MR imaging of cysts, ganglia, and bursae about the knee. *Radiol Clin N Am* 45:969–982
11. Beall DP, Ly JQ, Wolff JD et al (2005) Cystic masses of the knee: magnetic resonance imaging findings. *Curr Probl Diagn Radiol* 34:143–159
12. Campbell SE, Sanders TG, Morrison WB (2001) MR imaging of meniscal cysts: Incidence, location, and significance. *AJR* 177:409–413
13. Ghormley RK, Dockerty MB (1943) Cystic myxomatous tumors about the knee: Their relation to cysts of the meniscus. *J Bone Joint Surg Am* 25:306–318
14. Janzen DL, Peterfy CG, Forbes JR, Tirman PF, Genant HK (1994) Cystic lesions around the knee joint: MR imaging findings. *Am J Roentgenol* 163:155–161
15. Kransdorf MJ (1995) Malignant soft-tissue tumors in a large referral population: distribution of diagnoses by age, sex, and location. *Am J Roentgenol* 164:129–134
16. Sung MS, Kang HS, Suh JS et al (2000) Myxoid liposarcoma: appearance at MR imaging with histologic correlation. *Radiographics* 20:1007–1019
17. Hashimoto H, Tsuneyoshi M, Daimaru Y, Enjoji M, Shinohara N (1986) Intramuscular myxoma. A clinicopathologic, immunohistochemical, and electron microscopic study. *Cancer* 58:740–747

Precisely correct answer was received by closing date from:

Vasilis Maniatis, Palini, Greece