

Topotecan distribution in an anephric infant with therapy resistant bilateral Wilms tumor with a *novel* germline *WT1* gene mutation

Rieneke T. Lugtenberg · Karlien Cransberg ·
Walter J. Loos · Anja Wagner · Marielle Alders ·
Marry M. van den Heuvel-Eibrink

Received: 30 November 2007 / Accepted: 25 January 2008 / Published online: 14 February 2008
© The Author(s) 2008

Abstract The therapeutic strategy for bilateral Wilms tumor (WT) remains a challenge. Especially in cases with chemotherapy resistant disease, bilateral nephrectomy is sometimes inevitable. For optimal cure rates stage V WT patients benefit from adjuvant treatment; however, there are limited data available on chemotherapy pharmacokinetics in anephric children. In this report, we describe a 10-month old girl with bilateral Wilms tumor and a *novel* germline *WT1* gene mutation. This patient hardly showed any response on preoperative chemotherapy, and ultimately, underwent sequential bilateral tumor-nephrectomy. Subsequently, during peritoneal dialysis, she received topotecan as adjuvant chemotherapy based on plasma levels, indicating that this is a reasonable option as adjuvant treatment in

therapy-resistant Wilms tumor patients after bilateral nephrectomy. This case showed a *novel* germline *WT1* gene mutation of which the correlation with resistant phenotype has to be confirmed in larger cohorts of WT patients.

Keywords Bilateral Wilms tumor · Topotecan · Anephric infant · Therapy resistance · *Novel WT1* mutation

Introduction

Nephroblastoma, or Wilms tumor, is the most common renal neoplasm of childhood, with an incidence of 1 in 10,000 children. The mean age of diagnosis is 42–47 months for unilateral disease and 30–33 months for bilateral disease [25]. Bilateral (stage V) tumors occur in approximately 5–6% of all Wilms tumors. The overall survival rate is 90% for unilateral Wilms tumor and 80% for bilateral disease. In cases with diffuse anaplasia, which occurs in 10% of all bilateral cases detected by initial diagnosis, prognosis is even worse [9, 28].

The treatment of bilateral Wilms tumor is focussed on complete resection of the tumor, which is mandatory to guarantee optimal outcome. Meanwhile the maximal amount of normal renal parenchyma needs to be preserved. In case of progressive or nonresponsive disease, bilateral nephrectomy is inevitable in selected patients. For optimal cure rates, these children benefit from chemotherapy, before as well as after surgery. However, in anephric children, the management of adjuvant chemotherapeutic treatment has not been well described, illustrated by the fact that only scarce information is available on dose adjustment of various cytostatic drugs in case of renal failure in children [4, 5, 11, 13, 17, 21].

It is conceivable that bilateral Wilms tumor patients, especially if it occurs at an early age of onset, may carry

R. T. Lugtenberg · M. M. van den Heuvel-Eibrink (✉)
Department of Pediatric Hematology/Oncology,
Erasmus MC-Sophia Children's Hospital, Room Sp2568,
P. O. Box 2060, 3000 CB Rotterdam, The Netherlands
e-mail: m.vandenheuvel@erasmusmc.nl

K. Cransberg
Department of Pediatric Nephrology,
Erasmus MC-Sophia Children's Hospital,
Rotterdam, The Netherlands

W. J. Loos
Department of Medical Oncology,
Laboratory of Translational Pharmacology,
Erasmus MC-Daniel den Hoed Cancer Center,
Rotterdam, The Netherlands

A. Wagner
Department of Clinical Genetics,
Erasmus Medical Center, Rotterdam, The Netherlands

M. Alders
Department of Clinical Genetics, Academic Medical Center,
University of Amsterdam, Amsterdam, The Netherlands

germline *WT1* gene mutations more frequently as compared to patients with unilateral Wilms tumor, although previous studies report conflicting observations [19, 23, 24]. Constitutional defects of the *WT1* gene are involved in several overlapping clinical phenotypes, including the WAGR syndrome (Wilms tumor, Aniridia, Genito-urinary malformations and mental Retardation), Denys-Drash and Beckwith Widemann syndrome.

It has been suggested that certain germline *WT1* gene mutations are associated with a more resistant phenotype, which in bilateral cases harbors a higher risk for an eventual anephric status [14, 26]. In this case report we describe a 10-month-old African girl with chemotherapy un-responsive bilateral Wilms tumor, with a *novel* germline *WT1* gene splice site mutation in intron 6, who ultimately, underwent sequential bilateral tumor-nephrectomy. Subsequently, she received topotecan as adjuvant chemotherapy in adjusted doses, based on the plasma levels, during peritoneal dialysis.

Case

A 10-month-old African girl presented with a palpable abdominal mass, without hematuria, and without abdominal pain. Medical history and development was unremarkable. Physical examination showed neither dysmorphic features nor congenital genitourinary abnormalities, nor signs of hemihypertrophia. She had a normal tongue, iris and external ears. Ultrasound of the abdomen showed normal uterus and ovaria. Cytogenetic analysis showed a normal female karyotype (46 XX). Ultrasound of the abdomen showed a large tumor in the upper pole (largest diameter: 7.2 cm) and a smaller lesion in the middle pole (largest diameter: 4 cm) of the left kidney. The right kidney revealed a tumor in the upper pole (largest diameter: 3 cm) and multiple small cysts, mostly centrally situated in the kidney. No metastases in liver, lungs or abdominal lymph nodes were found. MRI imaging revealed no nephrogenic rests. Serum creatinine was normal for age.

Being diagnosed with bilateral renal tumor, she was treated according to the stage V guidelines of the SIOP-2001 protocol for renal tumors. She received weekly vincristine (1 mg/m²) and dactinomycin (0.025 mg/kg) once every 2 weeks. After 4 weeks, ultrasound showed hardly any decrease in tumor size in the left kidney, and a slight growth on the right side, therefore doxorubicin (33 mg/m²) was added to the vincristine/dactinomycin regimen (VAD). After 9 weeks of chemotherapy, MRI of the abdomen showed a change in radiological pattern suggesting necrosis; however, again no change in size in any of the tumors was found. Subsequently, surgery, including a left tumor-nephrectomy and biopsy of the right kidney, was

performed. Pathology revealed vital triphasic nephroblastoma, (local stage I, in the left kidney), with less than 5% necrosis after chemotherapy. Histology revealed no diffuse anaplasia nor predominant blastema. Because of disappointing response to VAD, postoperative treatment was started, consisting of three cycles of etoposide (VP-16) (300 mg/m² for 3 consecutive days) and carboplatin (400 mg/m² for 3 consecutive days). Thereafter, again, no tumor reduction was observed in the right kidney. Because of the disappointing response and the central localisation of the tumor, a second nephrectomy became inevitable. Simultaneously a peritoneal dialysis catheter was inserted. Histology again showed mixed type nephroblastoma, local stage I, with no visible necrosis; no diffuse anaplasia nor predominant blastema was found. Two days after the right tumor-nephrectomy, peritoneal dialysis was started. With the aim to treat the patient with adjuvant chemotherapy, topotecan was started 2 weeks later. Two cycles of topotecan were administered with an interval of 21 days, each consisting of 5-day courses of daily infusions in modified doses. Topotecan was administered intravenously in a daily dose of 0.75 mg/m² in 30 min and the course was followed by G-CSF (neupogen) subcutaneously, 5 mg/kg daily.

Peripheral blood samples for topotecan pharmacokinetic analysis were collected in lithium-heparinized tubes. On days 1 and 5, blood samples were collected before infusion, 15 min after the start of infusion, at the end of infusion, and subsequently at 0.5, 1, 1.5, 2, 4, 8 and 12 h (only on day 1) after the end of infusion. On days 2, 3 and 4, blood samples were collected prior to infusion (i.e., trough level) and at the end of infusion. All samples were processed within 15 min after collection as described previously [13]. Peritoneal dialysis samples were collected on day 1 and day 5 at 1, 2, 3, 4, 8 and 16 h after the start of infusion. Plasma as well as peritoneal dialysate samples was stored at –20°C until analysis.

Determination of total topotecan levels (i.e., the sum of lactone and carboxylate) in plasma was performed by high-performance liquid chromatography with fluorescence detection, based on a previously described method with minor modifications [20]. In brief, 100 µl aliquots of plasma were added to 300 µl of cold (–20°C) methanol. After thorough vortex mixing, the samples were centrifuged for 5 min at 23,000×g. Aliquots of 100 µl of the clear supernatant were subsequently mixed with 400 µl 0.1% acetic acid, from which 150 µl was injected into the HPLC system. Chromatographic separations were achieved on a Hypersil BDS column (100 × 3 mm ID, 3 µm particle size; Shandon, Cheshire, UK), which was maintained at 35°C. The mobile phase, composed of 10 mM potassium dihydrogenphosphate–methanol–triethylamine (1,750:500:4, v/v/v) with the pH adjusted to 6.0 (orthophosphoric acid), was delivered at a flow rate of 0.70 ml/min. The excitation and emission wavelengths of the Jasco FP920 fluorescence

detector (Tokyo, Japan) were set at 381 and 525 nm, respectively, with an emission bandwidth of 40 nm. Chromatographic data analysis was performed based on peak height measurements relative to injected standards using the ChromCard system of Fisons (Milan, Italy). Prior to processing peritoneal dialysis samples were diluted twofold in blank plasma, after which they were processed as described above for plasma. Pharmacokinetic plasma profiles of topotecan were analyzed by non-compartmental, 1/concentration weighted, analysis using the software package WinNonlin version 5.0 (Pharsight, Mountain View, CA, USA).

In this chemo-resistant case which needed neo-adjuvant topotecan after bilateral tumornephrectomy, *WT1* gene analysis revealed a not previously described germline mutation of the invariant nucleotides AG of the splice acceptor site of intron 6, c.895-2A>G. The nucleotide numbering is derived from the cDNA sequence NM_024426.3 (isoform D, longest transcript), where the A in the ATG initiation codon (base 401 in this sequence) corresponds to base 1. The parents did not carry this mutation, indicating that this involves a de novo mutation. Analysis of DNA extracted from tumor material showed that in the tumor the normal wild type allele was lost (Fig. 1a).

To study the effect of the splice site mutation in this chemo-resistant case, RNA was extracted from tumor

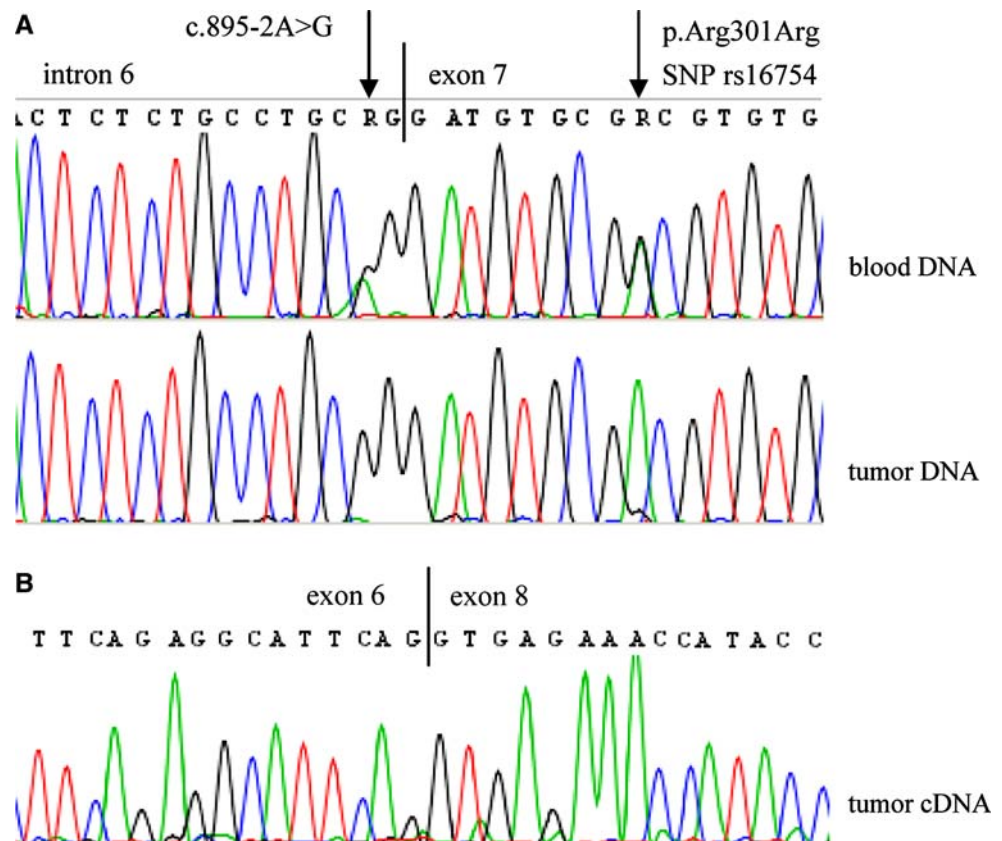
material using RNABee (AMS Biotechnology). Reverse transcription was done using SuperscriptIII and random hexamers, and subsequent PCR was performed with primers specific for exon 4 and exon 8 of the *WT1* gene. Two different products were amplified representing the normal splice variants with and without exon 5 (data not shown). Both products lacked exon 7 showing that the mutation causes skipping of exon 7 (Fig. 1b). This results in a frame-shift at position 299 of the *WT1* protein and a truncation after 31 altered aminoacids (p.Asp299fsX32).

Currently, after a follow-up of 32 months, the girl is in first complete continuous remission, in good health on peritoneal dialysis, waiting for renal transplantation.

Discussion

Although synchronous bilateral Wilms tumors have an overall survival rate of 80%, the optimal therapeutic strategy remains a challenge [9, 28]. Complete tumorresection, while preserving a sufficient amount of normal renal parenchyma, is not always feasible. Preoperative chemotherapy has been proven to be effective in most bilateral Wilms tumors; however, some patients show progressive or nonresponsive disease (PRND) during preoperative treatment.

Fig. 1 a Electropherograms showing the heterozygous mutation c.895-2A>G in the blood sample and loss of the wild type allele in the tumor sample. Patient is heterozygous for a common SNP (rs16754), which shows LOH in the tumor. **b** Electropherogram showing skipping of exon 7 in the cDNA synthesised from tumor RNA



Our patient was treated according to the stage V guidelines of the SIOP-2001 protocol for renal tumors. Because of response failure following all preoperative standard chemotherapeutic schedules, it was decided to perform sequential tumor-nephrectomies. The relatively favorable histology in our patient encouraged us to follow this delayed surgery strategy [9]. In general, to reach optimal outcome, patients with Wilms tumors benefit from adjuvant chemotherapy and sometimes radiotherapy. In this (local stage I) case radiotherapy was not indicated, as histology was favorable. Moreover, the perspective of future kidney transplantation discouraged us to use irradiation as adjuvant treatment in this chemotherapy resistant case. Because of resistance to first and second-line chemotherapy and promising results with topotecan in phase I and II clinical trials [21, 30] this camptothecin analogue was administered as adjuvant treatment. Topotecan has shown to induce significant growth inhibition in experimental Wilms tumors in mouse models, even in very low doses [29]. Moreover, in pediatric patients with recurrent Wilms tumor, Metzger et al. [22] showed that topotecan was effective, indicated as responsive or stable disease in 18 of 25 children with favorable histology Wilms tumor, who were all pretreated with other chemotherapeutic agents. However, it should be noted that in this study, 12 of the 18 responders showed earlier response to conventional chemotherapy.

Optimal chemotherapeutic treatment in anephric patients is a challenge. So far, only a few reports discussing chemotherapy in anephric children are available [4, 13, 17, 21]. In children with renal failure, it is questionable whether all agents should be administered at reduced dosages [5]. In a recent published report of the National Wilms Tumor Study (NWTs) investigators concluded that dose reduction for chemotherapeutic agents is not necessary for the treatment of newly diagnosed Wilms tumor in children with renal failure [5]. The included agents were vincristine, dactinomycin and doxorubicin. These agents can be safely administered in children with renal failure, because elimination of these agents is barely achieved by renal excretion.

In patients with normal renal function, topotecan is mainly eliminated by renal excretion, with approximately half of the administered intravenous dose excreted as parent drug in the urine [10]. Recently, pharmacokinetic studies in patients with impaired renal function showed that reduction of topotecan dosages in patients from 1.5 to 0.75 mg/m² resulted in adequate topotecan levels [11]. Moreover, topotecan was successfully administered in an anephric child at a dose of 0.75 mg/m² for 5 days in 30 min, with hemodialysis on the second day and fourth day [13]. It was shown that topotecan disposition was minimally affected by hemodialysis and was similar to that observed in children with Wilms tumor, without renal failure. Likewise, in our patient who was on peritoneal dialysis, the levels of topotecan in

plasma, after the administration of a reduced dose, were comparable to the pharmacokinetic data of a previously described anephric child [13]. As shown in Fig. 2a and Table 1, topotecan pharmacokinetics on day 1 and day 5 are comparable, illustrated by the minimal increases in the trough levels before start of the infusion. During the infusion, topotecan concentrations in peritoneal dialysate were lower than those observed in plasma, while peak concentrations in the dialysate were reached 1–4 h after the end of infusion (Fig. 2b). This is consistent with an earlier publication in which it was shown that both pleural and ascites represents only a small additional compartment for topotecan distribution [6]. Although topotecan is eliminated by peritoneal dialysis, as shown here, peritoneal dialysis is less effective than by the kidneys for the clearance of the drug. Dose reductions of topotecan in patients on peritoneal dialysis are thus required.

In our patient lack of chemotherapy response was found concomitantly with the occurrence of a *novel* germline *WT1* gene mutation. It is estimated that in at least 10% of all Wilms tumor cases, the disease arises in children with clinically well-defined genetic conditions, including WAGR, Denys–Drash, and Beckwith–Wiedemann syndrome [1, 3, 15, 18, 23, 27]. It has been suggested that nonsyndromic Wilms tumor patients carry a higher risk of germline *WT1* mutations in case of bilateral disease and an early age of onset [24]. In contrast, Perotti et al. [23] concluded that early age of diagnosis and bilaterality in Wilms tumor patients without associated abnormalities are no efficient predictors of germline *WT1* aberrations, based on a small group of 20 tumors with only 9 bilateral tumors [23]. The United Kingdom Children’s Cancer Group (UKCCG) analyzed 282 nonsyndromic WT patients and did not observe a difference in frequency of germline *WT1* mutations in unilateral compared to bilateral Wilms tumor cases [19]. Therefore, it could be questioned whether all bilateral Wilms tumors in nonsyndromic patients should be screened on germline mutations of *WT1*, as we did in our patient. Our patient revealed a germline splice site mutation in

Table 1 Summary of plasma pharmacokinetic data of topotecan

| Parameter | Day 1 | Day 2 | Day 3 | Day 4 | Day 5 |
|---|-------|-------|-------|-------|-------|
| $C_{\text{end of infusion}}$ (ng/ml) | 24.8 | 29.2 | 28.5 | 16.2 | 38.3 |
| Trough level (ng/ml) ^a | – | 0.82 | 1.53 | 2.03 | 2.23 |
| $AUC_{0-\text{inf}}$ (ng/h per ml) ^b | 176 | – | – | – | 207 |
| CL (l/h per m ²) | 4.27 | – | – | – | 3.63 |
| $T_{1/2z}$ (h) | 3.62 | – | – | – | 3.22 |

C Concentration, *AUC* area under the plasma concentration–time curve, *CL* systemic clearance

^a Concentration observed prior to start of infusion

^b Calculated using data up to 12 h (day 1) and 8 h (day 5) after start of infusion

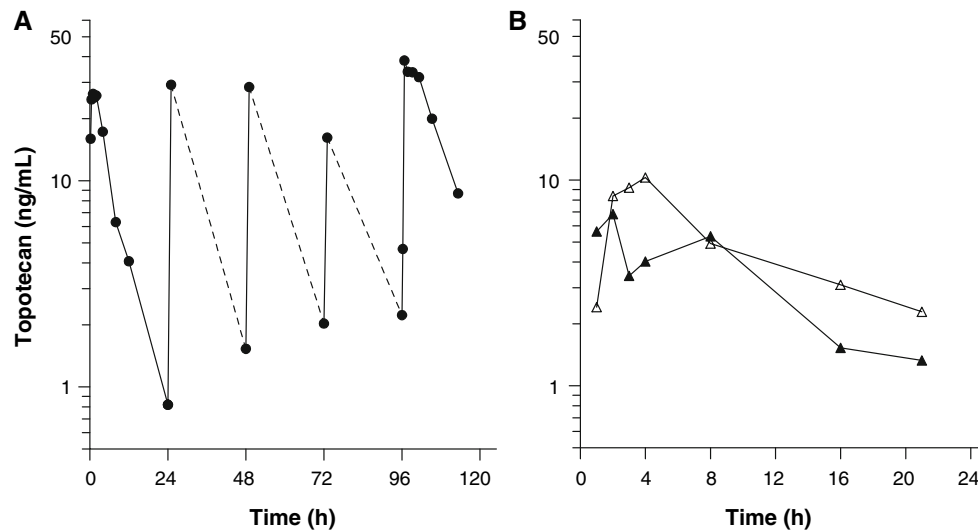


Fig. 2 **a** Pharmacokinetic profile of topotecan total concentration in plasma (days 1–5). **b** Pharmacokinetic profile of topotecan total concentration in peritoneal dialysate (day 1 closed symbols, day 5 open symbols)

intron 6 of the *WT1* gene (c.895-2A > G), which has not been described in previous cases with Wilms tumor. This mutation causes skipping of exon 7, which results in a frameshift and premature truncation before the nuclear localisation signal and the zinc fingers. Unfortunately, information is scarcely available about correlations between germline mutations and outcome in Wilms tumor patients [2, 7, 24, 26]. It seems that germline *WT1* mutations are associated with Wilms tumors of favorable histology, illustrated by the fact that germline *WT1* mutations are found predominantly in Wilms tumors with stromal histology [2, 7, 24, 26]. However, Schumacher et al. [26] found that an extensive rhabdomyomatous differentiation and the presence of *WT1* mutations correlate with a tumor subtype that responds poorly to chemotherapy. In our patient histology was not unfavorable, but response after chemotherapy was poor. Future studies in larger cohorts of patients are necessary to reveal whether the *novel WT1* gene mutation in our patient is associated with histological subtype and response.

More information is available on the association of somatic *WT1* gene mutations, which are found in approximately in 10% of all WT cases, and response, although conflicting results have been published [7, 18, 33]. Loss of heterozygosity (LOH) analysis revealed correlations between allelic loss or gene amplification and outcome in Wilms tumor patients [8, 12, 16, 31, 32]. Grundy et al. [8] found that loss of chromosome 1p and 16q are associated with an adverse outcome. Loss of chromosome 11q and 22q and gain of 1q and monosomy 22 are associated with an adverse outcome as well [12, 16, 32]. Our patient revealed biallelic loss (one germline mutation and one LOH in the tumor) of the *WT1* gene. To determine the role of this

novel mutation studies in larger cohort of patients are necessary.

In conclusion, our case shows that treatment with reduced doses of topotecan may be a reasonable option as adjuvant treatment in Wilms tumor patients, after bilateral nephrectomy, following a failed response on the initially started treatment. Further studies in larger cohorts of WT patients are needed to gain more knowledge about the correlation of this specific *novel WT1* gene mutation with response and prognosis.

Acknowledgments We appreciate the expert advise of C. Bergeron, J. de Kraker, ped. oncologists and J. Godzinski, ped. surgeon (SIOP, renal tumor coordinators for stage V disease) on the management of this case.

Open Access This article is distributed under the terms of the Creative Commons Attribution Noncommercial License which permits any noncommercial use, distribution, and reproduction in any medium, provided the original author(s) and source are credited.

References

1. Auber F, Lortat-Jacob S, Sarnacki S, Jaubert F, Salomon R, Thibaud E et al (2003) Surgical management and genotype/phenotype correlations in *WT1* gene-related diseases (Drash, Frasier syndromes). *J Pediatr Surg* 38(1):124–129 (discussion 124–129)
2. Bown N, Cotterill SJ, Roberts P, Griffiths M, Larkins S, Hibbert S et al (2002) Cytogenetic abnormalities and clinical outcome in Wilms tumor: a study by the U.K. cancer cytogenetics group and the U.K. Children's Cancer Study Group. *Med Pediatr Oncol* 38(1):11–21
3. Cooper WN, Luharia A, Evans GA, Raza H, Haire AC, Grundy R et al (2005) Molecular subtypes and phenotypic expression of Beckwith–Wiedemann syndrome. *Eur J Hum Genet* 13(9):1025–1032
4. Dagher R, Kreissman S, Robertson KA, Provisor A, Bergstein J, Burke K et al (1998) High dose chemotherapy with autologous

- peripheral blood progenitor cell transplantation in an anephric child with multiply recurrent Wilms tumor. *J Pediatr Hematol Oncol* 20(4):357–360
5. Feusner JH, Ritchey ML, Norkool PA, Takashima JR, Breslow NE, Green DM (2007) Renal failure does not preclude cure in children receiving chemotherapy for Wilms tumor: a report from the National Wilms Tumor Study Group. *Pediatr Blood Cancer*
 6. Gelderblom H, Loos WJ, Verweij J, de Jonge MJ, Sparreboom A (2000) Topotecan lacks third space sequestration. *Clin Cancer Res* 6(4):1288–1292
 7. Ghanem MA, van Steenbrugge GJ, Nijman RJ, van der Kwast TH (2005) Prognostic markers in nephroblastoma (Wilms' tumor). *Urology* 65(6):1047–1054
 8. Grundy PE, Breslow NE, Li S, Perlman E, Beckwith JB, Ritchey ML et al (2005) Loss of heterozygosity for chromosomes 1p and 16q is an adverse prognostic factor in favorable-histology Wilms tumor: a report from the National Wilms Tumor Study Group. *J Clin Oncol* 23(29):7312–7321
 9. Hamilton TE, Green DM, Perlman EJ, Argani P, Grundy P, Ritchey ML et al (2006) Bilateral Wilms' tumor with anaplasia: lessons from the National Wilms' Tumor Study. *J Pediatr Surg* 41(10):1641–1644
 10. Herben VM, Schoemaker E, Rosing H, van Zomeren DM, ten Bokkel Huinink WW, Dubbelman R et al (2002) Urinary and fecal excretion of topotecan in patients with malignant solid tumours. *Cancer Chemother Pharmacol* 50(1):59–64
 11. Herrington JD, Figueroa JA, Kirstein MN, Zamboni WC, Stewart CF (2001) Effect of hemodialysis on topotecan disposition in a patient with severe renal dysfunction. *Cancer Chemother Pharmacol* 47(1):89–93
 12. Hing S, Lu YJ, Summersgill B, King-Underwood L, Nicholson J, Grundy P et al (2001) Gain of 1q is associated with adverse outcome in favorable histology Wilms' tumors. *Am J Pathol* 158(2):393–398
 13. Iacono LC, Adams D, Homans AC, Guillot A, McCune JS, Stewart CF (2004) Topotecan disposition in an anephric child. *J Pediatr Hematol Oncol* 26(9):596–600
 14. Kaste SC, Dome JS, Babyn PS, Graf NM, Grundy P, Godzinski J et al (2008) Wilms tumour: prognostic factors, staging, therapy and late effects. *Pediatr Radiol* 38(1):2–17
 15. Kist-van Holthe JE, Ho PL, Stablein D, Harmon WE, Baum MA (2005) Outcome of renal transplantation for Wilms' tumor and Denys-Drash syndrome: a report of the North American Pediatric Renal Transplant Cooperative Study. *Pediatr Transplant* 9(3):305–310
 16. Klamt B, Schulze M, Thate C, Mares J, Goetz P, Kodet R et al (1998) Allele loss in Wilms tumors of chromosome arms 11q, 16q, and 22q correlate with clinicopathological parameters. *Genes Chromosomes Cancer* 22(4):287–294
 17. Koren G, Weitzman S, Klein J, Moselhy G (1993) Comparison of carboplatin pharmacokinetics between an anephric child and two children with normal renal function. *Med Pediatr Oncol* 21(5):368–372
 18. Lee SB, Haber DA (2001) Wilms tumor and the WT1 gene. *Exp Cell Res* 264(1):74–99
 19. Little SE, Hanks SP, King-Underwood L, Jones C, Rapley EA, Rahman N et al (2004) Frequency and heritability of WT1 mutations in nonsyndromic Wilms' tumor patients: a UK Children's Cancer Study Group Study. *J Clin Oncol* 22(20):4140–4146
 20. Loos WJ, Stoter G, Verweij J, Schellens JH (1996) Sensitive high-performance liquid chromatographic fluorescence assay for the quantitation of topotecan (SKF 104864-A) and its lactone ring-opened product (hydroxy acid) in human plasma and urine. *J Chromatogr B Biomed Appl* 678(2):309–315
 21. McCune JS, Adams D, Homans AC, Guillot A, Iacono LC, Stewart CF (2006) Cyclophosphamide disposition in an anephric child. *Pediatr Blood Cancer* 46(1):99–104
 22. Metzger ML, Stewart CF, Freeman BB 3rd, Billups CA, Hoffer FA, Wu J et al (2007) Topotecan is active against Wilms' tumor: results of a multi-institutional phase II study. *J Clin Oncol* 25(21):3130–3136
 23. Perotti D, Mondini P, Terenziani M, Spreafico F, Collini P, Fossati-Bellani F et al (2005) WT1 gene analysis in sporadic early-onset and bilateral wilms tumor patients without associated abnormalities. *J Pediatr Hematol Oncol* 27(4):197–201
 24. Royer-Pokora B, Beier M, Henzler M, Alam R, Schumacher V, Weirich A et al (2004) Twenty-four new cases of WT1 germline mutations and review of the literature: genotype/phenotype correlations for Wilms tumor development. *Am J Med Genet A* 127(3):249–257
 25. Ruteshouser EC, Huff V (2004) Familial Wilms tumor. *Am J Med Genet C Semin Med Genet* 129(1):29–34
 26. Schumacher V, Schuhen S, Sonner S, Weirich A, Leuschner I, Harms D et al (2003) Two molecular subgroups of Wilms' tumors with or without WT1 mutations. *Clin Cancer Res* 9(6):2005–2014
 27. Scott RH, Stiller CA, Walker L, Rahman N (2006) Syndromes and constitutional chromosomal abnormalities associated with Wilms tumour. *J Med Genet* 43(9):705–715
 28. Shamberger RC, Haase GM, Argani P, Perlman EJ, Cotton CA, Takashima J et al (2006) Bilateral Wilms' tumors with progressive or nonresponsive disease. *J Pediatr Surg* 41(4):652–657 (discussion-7)
 29. Soffer SZ, Kim E, Moore JT, Huang J, Yokoi A, Manley C et al (2001) Novel use of an established agent: topotecan is anti-angiogenic in experimental Wilms tumor. *J Pediatr Surg* 36(12):1781–1784
 30. Tubergen DG, Stewart CF, Pratt CB, Zamboni WC, Winick N, Santana VM et al (1996) Phase I trial and pharmacokinetic (PK) and pharmacodynamics (PD) study of topotecan using a five-day course in children with refractory solid tumors: a pediatric oncology group study. *J Pediatr Hematol Oncol* 18(4):352–361
 31. Uschkereit C, Perez N, de Torres C, Kuff M, Mora J, Royer-Pokora B (2007) Different CTNNB1 mutations as molecular genetic proof for the independent origin of four Wilms tumours in a patient with a novel germ line WT1 mutation. *J Med Genet* 44(6):393–396
 32. Wittmann S, Zirn B, Alkassar M, Ambros P, Graf N, Gessler M (2007) Loss of 11q and 16q in Wilms tumors is associated with anaplasia, tumor recurrence, and poor prognosis. *Genes Chromosomes Cancer* 46(2):163–170
 33. Yang L, Han Y, Saurez Saiz F, Minden MD (2007) A tumor suppressor and oncogene: the WT1 story. *Leukemia* 21(5):868–876