



Rhabdomyolysis induced by nelarabine

Christian Späth¹ · Mandy Schönau¹ · Sophie Gaubert¹ · Thomas Neumann¹ · Christian A. Schmidt¹ · Florian H. Heidel¹ · William H. Krüger¹

Received: 23 May 2022 / Accepted: 4 June 2022 / Published online: 17 June 2022
© The Author(s) 2022

Dear Editor,

A 56-year-old male suffering from stage IV_B (Ann Arbor) T-lymphoblastic lymphoma, karyotype 47, XYY, was induced according to the GMALL elderly protocol with idarubicin, vincristine and dexamethasone [1]. Analysis of CSF revealed no lymphoma cells and intrathecal chemoprophylaxis was performed according to the protocol. Initially, flow cytometry of the bone marrow cells detected 5.5% blasts. Consolidation I (methotrexate and PEG-asparaginase) and consolidation II (high-dose Ara-C) were administered and well tolerated. Computed tomography showed a complete remission after consolidation I and marrow cytology and histology were negative for T-LBL blasts. However, minimal residual disease was still detectable by flow cytometry and by PCR analysis [2, 3].

Due to high-risk situation, the patient was scheduled for allogeneic stem cell transplantation from a matched unrelated donor and nelarabine was given for bridging. At day 3 of the protocol, the patient reported significant pain in the pelvic/renal region but no signs of renal or coronary disease. However, due to the patient's BMI of 40.81 the diagnostic focused on exclusion of cardiac disease, but electrocardiography and troponin were negative. Nelarabine was discontinued after two doses. Creatinine kinase (CK) raised to a maximum of 179.73 μ katal/l (upper normal value [UNV] = 5.8 μ katal/l) and myoglobin (MG) to a maximum of 2201 μ g/l (UNV = 96 μ g/l) (Fig. 1). Lactate

dehydrogenase was slightly elevated. The patient's symptoms disappeared after discontinuation of nelarabine and CK, MG and LDH normalised over the next week under forced diuresis and supportive therapy. Kidney parameters were normal during the entire course. The patient proceeded to allogeneic transplantation in complete remission without further bridging, has been discharged and is well and alive on day +56 after SCT.

Nelarabine is a nucleoside analogue used for therapy of T-ALL and T-LBL [4, 5]. The main toxicities reported are neurological and haematological. Rhabdomyolysis is a critical illness associated with severe morbidity [6]. The case of rhabdomyolysis as an adverse effect of nelarabine described here is the third in the literature [4, 7, 8]. An unclear increase of creatinine kinase after nelarabine was already reported by Gökbuget et al. in 2011 [4]. In the presented case, the clinical picture in conjunction with the high BMI was first misleading to a suspected cardiac injury. The negative troponin and the positive myoglobin in clinical chemistry delivered finally the diagnosis of a rhabdomyolysis. The early discontinuation of nelarabine was presumably helpful to avoid organ damages and further morbidity.

In conclusion, we suggest a monitoring of myoglobin under nelarabine therapy for early recognition of rhabdomyolysis. A tool for the identification of patients at high risk for rhabdomyolysis would be very helpful.

✉ William H. Krüger
william.krueger@med.uni-greifswald.de

¹ Clinic for Internal Medicine C – Haematology and Oncology, Stem Cell Transplantation and Palliative Care, University Medicine Greifswald, Ferdinand-Sauerbruch-Straße, 17475 Greifswald, Germany

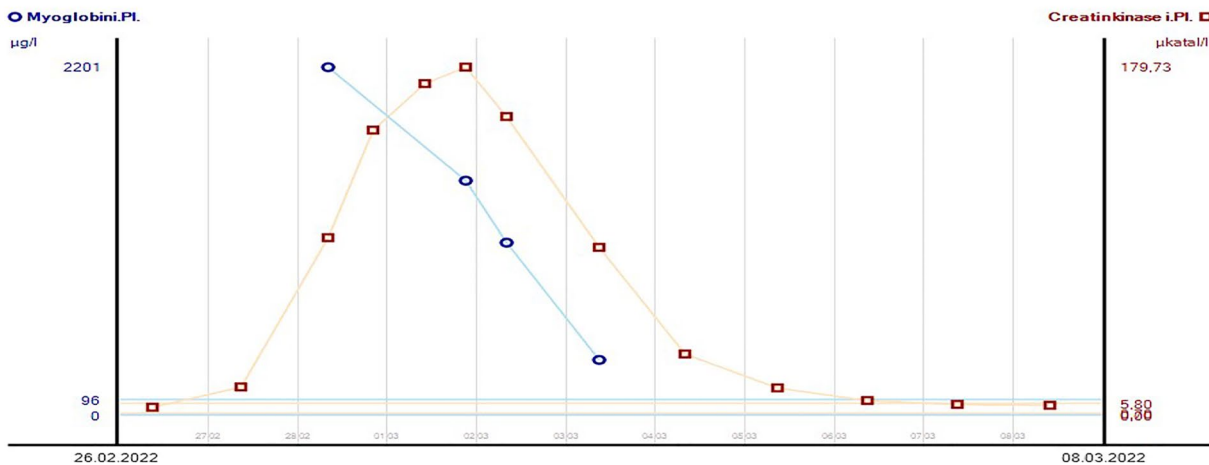


Fig. 1 Course of creatinine kinase (orange) and myoglobin (blue) in plasma

Funding Open Access funding enabled and organized by Projekt DEAL.

Declarations

Ethics approval n/a.

Consent to participate This article does not contain any studies with human participants performed by any of the authors.

Conflict of interest The authors declare no competing interests.

Open Access This article is licensed under a Creative Commons Attribution 4.0 International License, which permits use, sharing, adaptation, distribution and reproduction in any medium or format, as long as you give appropriate credit to the original author(s) and the source, provide a link to the Creative Commons licence, and indicate if changes were made. The images or other third party material in this article are included in the article's Creative Commons licence, unless indicated otherwise in a credit line to the material. If material is not included in the article's Creative Commons licence and your intended use is not permitted by statutory regulation or exceeds the permitted use, you will need to obtain permission directly from the copyright holder. To view a copy of this licence, visit <http://creativecommons.org/licenses/by/4.0/>.

References

- Gökbuget N (2016) Treatment of older patients with acute lymphoblastic leukemia. *Hematol Am Soc Hematol Educ Prog* 2016(1):573–579. <https://doi.org/10.1182/asheducation-2016.1.573>
- Brüggemann M, Schrauder A, Raff T et al (2010) Standardized MRD quantification in European ALL trials: proceedings of the Second International Symposium on MRD assessment in Kiel, Germany, 18–20 September 2008. *Leukemia* 24(3):521–535. <https://doi.org/10.1038/leu.2009.268>
- Theunissen P, Mejstrikova E, Sedek L et al (2017) Standardized flow cytometry for highly sensitive MRD measurements in B-cell acute lymphoblastic leukemia. *Blood* 129(3):347–357. <https://doi.org/10.1182/blood-2016-07-726307>
- Gökbuget N, Basara N, Baumann H et al (2011) High single-drug activity of nelarabine in relapsed T-lymphoblastic leukemia/lymphoma offers curative option with subsequent stem cell transplantation. *Blood* 118(13):3504–3511. <https://doi.org/10.1182/blood-2011-01-329441>
- Kisor DF (2005) Nelarabine: a nucleoside analog with efficacy in T-cell and other leukemias. *Ann Pharmacother* 39(6):1056–1063. <https://doi.org/10.1345/aph.1E453>
- Huerta-Alardín AL, Varon J, Marik PE (2005) Bench-to-bedside review: rhabdomyolysis — an overview for clinicians. *Crit Care (London, England)* 9(2):158–169. <https://doi.org/10.1186/cc2978>
- Haider M, Rizvi SA, Kasi PM (2015) Nelarabine associated myotoxicity and rhabdomyolysis. *Case Rep Hematol* 2015:825670. <https://doi.org/10.1155/2015/825670>
- Pandey RK, DiPippo A, Kadia T et al (2020) Nelarabine-related rhabdomyolysis in a patient with T-cell acute lymphoblastic leukemia. *Leuk Lymphoma* 61(11):2775–2777. <https://doi.org/10.1080/10428194.2020.1791852>

Publisher's note Springer Nature remains neutral with regard to jurisdictional claims in published maps and institutional affiliations.