

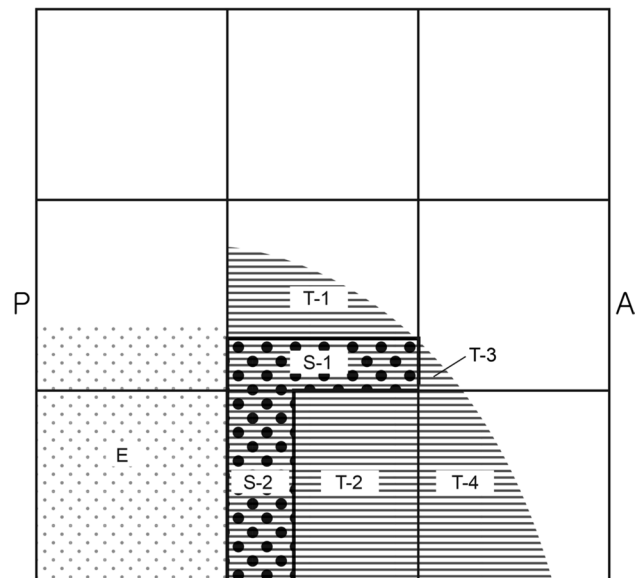
## Erratum to: Anatomical recommendations for safe botulinum toxin injection into temporalis muscle: a simplified reproducible approach

Won-Kang Lee<sup>1</sup> · Jung-Hee Bae<sup>2</sup> · Kyung-Seok Hu<sup>2</sup> · Takafumi Kato<sup>3</sup> · Seong-Taek Kim<sup>1,2</sup>

Published online: 13 September 2017  
© Springer-Verlag France SAS 2017

### Erratum to: Surg Radiol Anat (2017) 39:263–269 DOI 10.1007/s00276-016-1739-1

In the original publication of the article the Figs. 3 and 4 captions has been published incorrectly. the correct captions of Figs. 3 and 4 are as follows:



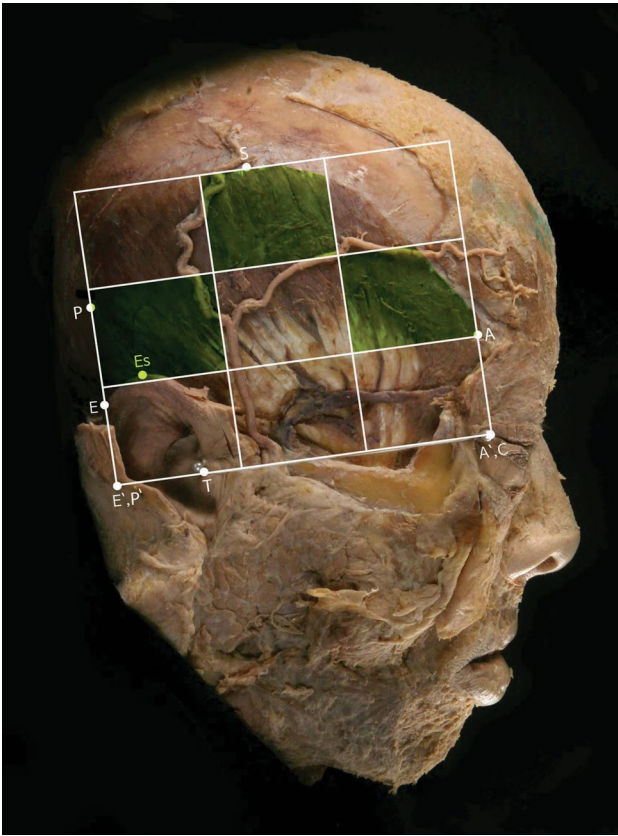
E. External ear : 32.2%  
T. Temporalis tendon  
T-1. 65%  
T-2. 100%  
T-3. 10%  
T-4. 53%  
S. Superficial temporal artery (STA)  
S-1. 30%  
S-2. 32%

The online version of the original article can be found under doi: [10.1007/s00276-016-1739-1](https://doi.org/10.1007/s00276-016-1739-1).

✉ Seong-Taek Kim  
k8756050@yuhs.ac

- <sup>1</sup> Department of Orofacial Pain and Oral Medicine, Yonsei University College of Dentistry, Seoul, South Korea
- <sup>2</sup> Division in Anatomy and Developmental Biology, Department of Oral Biology, Human Identification Research Center, Yonsei University College of Dentistry, 50 Yonsei-ro, Seodaemun-gu, Seoul 120-749, South Korea
- <sup>3</sup> Department of Oral Anatomy and Neurobiology, Osaka University Graduate School of Dentistry, Osaka, Japan

**Fig. 3** The percentages occupied by the main anatomical structures on each compartment. *E* external ear, *T* temporalis tendon: T-1. 65%, T-2. 100%, T-3. 10%, T-4. 53%, *S* superficial temporal artery: S-1. 30%, S-2. 32%



**Fig. 4** Recommended injection sites within the nine compartments are shaded in the clinical photo of simplified reproducible approach in a cadaver