

Awareness and use of intertrochanteric osteotomies in current clinical practice. An international survey

D. Haverkamp · H. Eijer · P. P. Besselaar · R. K. Marti

Received: 1 June 2006 / Revised: 22 August 2006 / Accepted: 24 August 2006 / Published online: 13 April 2007
© Springer-Verlag 2007

Abstract Current literature shows that intertrochanteric osteotomies can produce excellent results in selected hip disorders in specific groups of patients. However, it appears that this surgical option is considered an historical one that has no role to play in modern practice. In order to examine current awareness of and views on intertrochanteric osteotomies among international hip surgeons, an online survey was carried out. The survey consisted of a set of questions regarding current clinical practice and awareness of osteotomies. The second part of the survey consisted of five clinical cases and sought to elicit views on preoperative radiological investigations and preferred (surgical) treatments. The results of our survey showed that most of these experts believe that intertrochanteric osteotomies should still be performed in selected cases. Only 56% perform intertrochanteric osteotomies themselves and of those, only 11% perform more than five per year. The responses to the cases show that about 30–40% recommend intertrochanteric osteotomies in young symptomatic patients. This survey shows that the role of intertrochanteric osteotomies is declining in clinical practice.

Résumé La littérature montre que les ostéotomies intertrochantériennes peuvent donner de bons résultats dans des indications précises. Cependant il apparait que cette opération est considérée comme historique, sans rôle à

jouer dans une pratique moderne. Pour apprécier les idées actuelles sur ces ostéotomies parmi les chirurgiens de la hanche, une enquête a été faite par courrier électronique. Cette étude comportait une série de questions concernant les pratiques cliniques et la connaissance des ostéotomies inter trochantériennes. Une seconde partie concernait 5 cas cliniques et il était demandé les investigations radiologiques et les traitements proposés. Les résultats de cette étude montraient que la plupart des experts pensait que ces ostéotomies pouvaient être faites dans des cas sélectionnés. Seulement 56% font des ostéotomies intertrochantériennes et parmi eux, seulement 11% en font plus de 5 par an. Les réponses aux cas cliniques montraient que 30 à 40% préconise ces ostéotomies chez des patients jeunes et symptomatiques. Cette étude montre que le rôle de l'ostéotomie intertrochantérienne est déclinant en pratique clinique.

Introduction

The use of intertrochanteric osteotomies appears to be declining in current clinical practice. It seems that many orthopaedic surgeons consider it an historical operation that has lost its place in current hip-disorder treatment. There are many retrospective studies showing overall unsatisfactory results (Table 1) [1, 2, 4, 6, 9–10, 13, 16–18, 20, 21, 23–28, 30]. However, many of these included elderly patients with advanced stages of primary osteoarthritis (OA). The same studies showed that the outcome in younger patients with early-onset secondary osteoarthritis was good. However, only a few of these studies showed survival rates identical or superior to those of total hip replacements and then only in selected patient groups. In a recent long-term follow-up study, we demonstrated that, for specific hip disorders, intertrochanteric osteotomies can

D. Haverkamp (✉) · P. P. Besselaar · R. K. Marti
Academic Medical Centre,
Orthotrauma Research Centre Amsterdam (G4-No),
P.O. Box 22660, NL-1100 DD Amsterdam, The Netherlands
e-mail: D.Haverkamp@osteotomie.nl

H. Eijer
Clinic Sonnenhof, Department of Orthopaedic Surgery,
Bern, Switzerland

Table 1 Review of the literature

Authors ^a	n	Indication	Type of osteotomy	Age (mean, range)	Grade of OA	Follow-up	Survival/conclusion
Haverkamp et al. 2006 [6]	276	All	All	45 (16–79)	Mild to advanced	15–29 years	Better results in young patients with mild OA
Haverkamp et al. 2006 [6]	48	Idiopathic	All	57 (34–79)	Mild to advanced	15–29 years	10-year survival 50% and 15-year 32%
Haverkamp et al. 2006 [6]	166	Dysplasia	All	46 (16–75)	Mild to advanced	15–29 years	10-year survival 72% and 15-year 56%
Haverkamp et al. 2006 [6]	22	Post-traumatic	All	37 (17–68)	Mild to advanced	15–29 years	10-year survival 91% and 15-year 78%
Haverkamp et al. 2006 [6]	14	SCFE	All	44 (25–55)	Mild to advanced	15–29 years	10-year survival 71% and 15-year 56%
Haverkamp et al. 2006 [6]	20	AVN	All	38 (16–60)	Mild to advanced	15–29 years	10-year survival 60% and 15-year 30%
Pecasse et al. 2004 [21]	15	LCPD	All	30 (19–55)	Mild to advanced	4–25 years	33% converted after an average of 15.4 years
D'Souza et al. 1998 [4]	25	All	All	38 (18–53)	Mild to advanced	2–12 years	67% survival after an average of 12 years
Perlau et al. 1996 [23]	16	Idiopathic	All	48 (38–75)	Mild to advanced	5–10 years	44% converted after an average of 6.1 years
Morssher et al. 1971 [20]	2,251	All	All	20–80+	Moderate to advanced	2–14 years	Good indications are LCPD, SCFE and dysplasia
Schneider et al. 1966 [26]	109	All	All	70 by follow up	Moderate to advanced	12–15 years	35% converted after an average of 8 years
Marti et al. 2001 [17]	10	OA after acetabular fractures	All	29 (16–47)	Mild to advanced	3–22 years	80% survival after an average of 10 years
DePalma et al. 1970 [3]	38	All	All	57 (15–81)	Moderate to advanced	1–9 years	Pain relief in 87%, no long-term results
Perlau et al. 1996 [23]	18	Dysplasia	All	33 (24–58)	Mild to advanced	5–10 years	79% survival after an average of 6.1 years
Toyama et al. 2000 [28]	67	Dysplasia	Valgus-extension	44 (23–59)	Advanced	5–16 years	10-year survival 79%
Gotoh et al. 1997 [5]	31	Dysplasia	Valgus-extension	43 (22–59)	Advanced	12–18 years	15-year survival 51%
Iwase et al. 1996 [9]	42	Dysplasia	Varus	25	Mild	20 years	10-year survival 89% and 15-year 87%
Jingushi et al. 2002 [10]	70	Dysplasia	Valgus	44 (14–59)	Advanced	2–15 years	10-year survival 82%
Kubo et al. 2000 [12]	17	Dysplasia	Valgus-extension	50 (34–58)	Advanced	10–14 years	18% good at last follow up
Pellicci et al. 1991 [22]	56	Dysplasia	Varus	35 (17–62)	Mild to moderate	2–21 years	72% good to excellent after 9 years
Ito et al. 2005 [8]	55	Dysplasia	Varus	32 (12–55)	Mild to moderate	6–28 years	10-year survival 81%
Iwase et al. 1996 [9]	58	Dysplasia	Valgus	37	Moderate to advanced	20 years	10-year survival 66% and 15-year 38%
Langlais et al. 1979 [13]	150	Idiopathic	Valgus	52 (26–66)	Moderate to advanced	3–10 years	68% good
Maistrelli et al. 1990 [16]	277	All	Valgus-extension	52 (26–66)	Mild to advanced	11–15 years	67% perfect to good, better results in young patients with secondary OA
Miegel et al. 1984 [18]	77	All	Medialisation	?	Moderate to advanced	12–15 years	10-year survival 49%
Reigstad et al. 1984 [24]	103	All	All	58 (24–74)	Moderate to advanced	10–15 years	10-year survival 58%
Santore et al. 1983 [25]	45	All	Valgus	50 (32–69)	Moderate to advanced	11 years	75% good
Weisl et al. 1980 [30]	757	All	All	?(incl. 70+)	Moderate to advanced	10–22 years	25% good at follow up, better results in young patients with secondary OA
Castaigne et al. 1981 [1]	141	All	Varus	51 (25–71)	Moderate to advanced	13.5 years	67% good
Collert et al. 1979 [2]	94	All	All	60 (32–77)	Advanced	5 years	46% good after 5 years
Linde et al. 1985 [15]	85	All	All	<60	Moderate to advanced	1–15 years	39% good after 5 years
Teinturier et al. 1982 [27]	63	All	Flexion	55 (37–71)	Advanced	10 years	65% good
Zaoussis et al. 1984 [31]	70	All	Medialisation + rotation	47 (21–68)	Mild to advanced	6–15 years	70% good

^aWhere possible, articles are subdivided as indicated

achieve good to excellent long-term results [6]. Several recent reviews presented the same message, namely that intertrochanteric osteotomies should not be forgotten as a treatment option in these selected cases [19, 29]. Since we believed that this view was not shared universally, we initiated an online international survey to investigate current awareness among orthopaedic hip surgeons about these selected groups and to map the current clinical use of intertrochanteric osteotomies.

Methods

We developed a questionnaire consisting of two sections. The first section consisted of questions dealing with the use of intertrochanteric osteotomy in clinical orthopaedic practice. To assess orthopaedic surgeons' awareness, the second part of the questionnaire consisted of questions related to five clinical cases. These cases were taken from our own long-term follow-up series and the long-term outcome of the performed intertrochanteric osteotomy was known in each case [6]. The responders were unaware of the treatment these patients received. Table 2 shows the full questionnaire (cases excluded).

An invitation to respond online to the questionnaire was sent to all members of the American Association of Hip and Knee Surgeons, all members of the British Hip Society and members of the Dutch Orthopaedic Society.

In order to identify factors that influenced surgeons to opt for an intertrochanteric osteotomy, a statistical analysis of the required data was carried out using a Pearson correlation analysis in which $P < 0.05$ was considered as significant.

Results

One thousand invitations were sent by mail with an online return of 162 questionnaires. Since all responses were anonymous, no reminders or second invitations could be sent to non-responders. There were 69 responders from the United States and 93 from Europe.

From the content of the responses, we assume that all responders are orthopaedic surgeons with a special interest in hip surgery. Of all respondents, 96% believe that there is still a place for intertrochanteric osteotomy in current clinical practice with 56% still performing these. Only 11% perform more than five osteotomies per year.

The indications that are considered valid for performing intertrochanteric osteotomies are given in Table 3.

In the workup of hip disorders, 87% of surgeons ask for an AP pelvic radiograph and 85% a lateral radiograph. False profile views instead of lateral views are added only

by 62%. A CT scan is routinely requested by 29% and an additional MRI by 17%. Only 3% requested an MR arthrography.

When the issue of performing a THR after a previous intertrochanteric osteotomy was raised, 83% regarded this as a more challenging operation. Thirty-four percent believed that the long-term results of THR after a previous osteotomy would be impaired. This view appeared to have no bearing on the decision whether osteotomies should still be performed. Of the surgeons who perform osteotomies themselves, 46% think that the long-term outcome of a subsequent THR is impaired. In the case of surgeons who did not perform osteotomies, this figure increased to 68% (chi-square not significant).

When a sub-analysis was performed comparing responses from orthopaedic surgeons from the United States with those from Europe, the only significant differences were found in the performance and indication. In Europe, 69% of the questioned surgeons perform intertrochanteric osteotomies; in the United States only 39% (chi-square $P < 0.01$). In Europe, 33% believed that selected patients with idiopathic OA could benefit from an ITO; in the USA, this was only 9% (chi-square $P < 0.01$). Also for post-Perthes deformities (Europe 50%, USA 27%) and post-traumatic deformities (Europe 41%, USA 16%), significant differences were present (chi-square both $P < 0.01$). No significant regional differences were present in preoperative screening.

Although it is not possible to show all X-rays from the cases in this article, we attempt to give an impression by presenting the neck-shaft angle (CCD) as an indicator of coxa valga, the Sharp angle as an indication of the steepness of the acetabulum, and the CE angle according to Wiberg and the acetabular head index (AHI) as indicators of dysplasia and lateralisation.

The severity of osteoarthritis was graded according to Tönnis. Complaints were scored using the Merle d'Aubigne score.

In case 1, we presented a 34-year-old female with a coxa valga (CCD 140°) and mild dysplasia (Sharp angle 50°, CE 22° and AHI 0.7) with mild OA (Tönnis grade 1) and a Merle d'Aubigne score of 13. In addition to a pelvic X-ray and an abduction correction view, 64% requested additional investigations. These were mainly false profiles (35%), lateral X-rays (32%) and CT scans (30%). As a treatment option, an intertrochanteric osteotomy was mentioned by 32%, an acetabular realigning osteotomy (also known as periacetabular osteotomy, PAO) by 28% and a THR by 4% (Fig. 1). We performed a 15° varus osteotomy, which was converted to a THA after 21 years.

In case 2, we presented a 55-year-old female with a coxa valga (CCD 139°) and minimal dysplasia (Sharp angle 43°, CE 24°) with moderate OA (Tönnis grade 2) and a Merle

Table 2 Questions from the survey

Questions
Occupation: Orthopaedic Surgeon/Orthopaedic Resident/Other
Age: <30 years/30–50 years/>50 years
Question 1:
Is there still a place for intertrochanteric osteotomies (ITO) in the treatment of primary or secondary osteoarthritis? No/Yes/Yes, but only in young patients/Yes, but only in some special cases
Question 2:
Do you perform intertrochanteric osteotomies yourself? Yes/No
If Yes, how many per year?
Question 3a:
Do you investigate the possibility of performing an ITO in (selected) patients with osteoarthritis of the hip? Yes/No
Question 3b:
If Yes, for which types of osteoarthritis do you consider an osteotomy?
Idiopathic OA
OA secondary to acetabular dysplasia
OA secondary to coxa valga
OA secondary to Legg-Calvé-Perthes disease
OA secondary to slipped capital femoral epiphysis
Post-traumatic OA
Question 4:
Is 3-D CT scanning necessary for the planning of an ITO? Yes/No
Question 5:
Which kind of radiological investigation is necessary to plan an ITO in your opinion? (several options are possible)
Plain pelvic X-ray
Abduction and/or adduction correction views
X-ray according to Dunn
False profile
Lateral hip X-ray
CT scan
CT scan with 3-D reconstruction
MRI
Arthro-MRI
Question 6:
Do you consider a total hip replacement after a previous osteotomy to be a more challenging operation? Yes/No
Question 7:
Do you think that the long-term results of total hip replacement after a previous osteotomy are worse than the results of a primary THR?
Yes, worse than the long-term results of a primary THR/No, both long-term results are comparable
Question 8:
Is there, in your opinion, an age limit for performing an ITO? Yes/No

d'Aubigne score of 9. In addition to a pelvic X-ray and an abduction/adduction correction view as shown, 28% requested additional investigations. As a treatment option, an intertrochanteric osteotomy was mentioned by 9%, an acetabular realigning osteotomy by 1% and a THR by 70%. We performed a 10° valgus osteotomy, which was converted to a THA after 9.4 years.

In case 3, we presented a young female (31 years of age) with minimal complaints and mild dysplasia (sharp angle

Table 3 Indications for which intertrochanteric osteotomies are still considered

Indication	% of respondents
Idiopathic OA	23
Dysplasia	51
Coxa valga	65
Legg-Calvé-Perthes disease	40
Slipped capital femoral epiphysis	53
Post-traumatic deformities	31

50° and CE angle of 14°) without significant osteoarthritic changes (Fig. 1). The majority advised conservative treatment (58%). In this case, 21% requested additional MRI scanning and 22% requested additional false profile X-rays. We performed a 15° varus osteotomy. After 19 years the patient had a Merle d'Aubigne score of 13.

In case 4, we described an 18-year-old female with a symptomatic (Merle d'Aubigne 16) excessive femoral anteversion (CCD 140° anteversion 38°) with a normal acetabulum (Sharp angle 38° and CE angle 36°). In addition to a pelvic X-ray and a Dunn X-ray, 49% requested additional investigations and 50% of these requested an MRI. The suggested treatment consisted of conservative treatment in 43% and an intertrochanteric osteotomy in 41%. We performed a slight varus and 20° derotation osteotomy (at both hips) and after 20 years, the patient had a Merle d'Aubigne score of 15 (and 18 for the contra lateral hip).

In case 5, a typical post-Perthes deformity was shown in a 28-year-old male with progressive complaints. In addition to the presented pelvic X-ray and adduction correction view, 44% requested additional investigations, mainly lateral views and CT scans. The suggested treatment consisted of conservative treatment in 43% and an intertrochanteric osteotomy in 33%. We performed a valgus osteotomy; after 14 years, the patient had a Merle d'Aubigne score of 17.

Figure 2 shows a summary of suggestions made in the five cases. Overall, intertrochanteric osteotomies were advised by 30–40% in symptomatic young patients. One case consisted of an older female patient (case 2) with a symptomatic OA secondary to dysplasia, in which mainly THR was advised.

In the cases concerning younger patients, 44–63% of the respondents requested additional radiological investigations. In cases 1 and 5, these were mainly false profile views and CT scans; in case 3, mainly false profile views and MRIs; and in case 4, mainly CT scans and MRIs.

Responders were divided into two age groups: younger and older than 50. Apart from their responses in cases of post-traumatic deformities (young 40%, older 22%, chi-square $P < 0.05$), no significant differences were present.

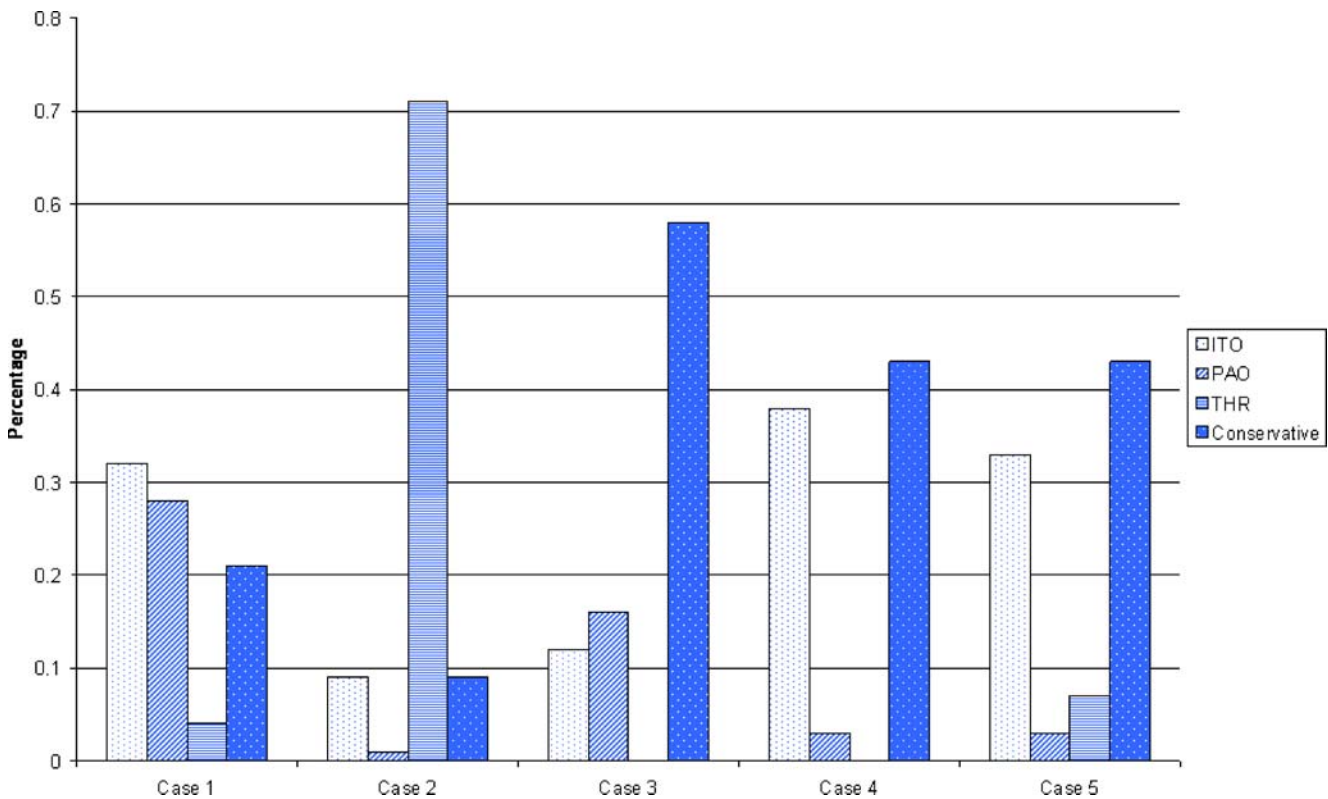


Fig. 1 Suggested interventions per case. *Case 1* A 34-year-old female with symptomatic mild OA due to mild dysplasia and coxa valga. *Case 2* A 55-year-old female with symptomatic moderate OA due to mild dysplasia and coxa valga. *Case 3* A 31-year-old female with mild OA without significant complaints due to mild dysplasia and coxa valga.

Case 4 An 18-year-old female with symptomatic excessive femoral anteversion without OA changes. *Case 5* A 28-year-old male with a symptomatic post-Perthes deformity without OA changes. *ITO* Intertrochanteric osteotomy, *PAO* periacetabular osteotomy, *THR* total hip replacement

The Pearson correlation analysis showed a significant correlation between THR and age ($R=0.91$) and clinical complaints ($R=0.91$). Conservative treatment showed a significant correlation with clinical complaints ($R=0.93$).

Discussion

The aim of this survey was to show the role of the intertrochanteric osteotomy in current practice. Although almost all responders believe that intertrochanteric osteotomies should still play a role in modern medicine, only a few are performed nowadays. One should take into account that we primarily surveyed hip experts and not many general orthopaedic surgeons. Thus, the responses do not necessarily reflect common orthopaedic practice; however, we can assume that the use of intertrochanteric osteotomy by the non-specialised hip surgeon is probably even lower. This indicates that less reconstructive osteotomy surgery is performed nowadays and that the surgical know-how is in danger of being lost.

Of course, it is difficult to give accurate advice based on limited information and without seeing the patient; however

it is possible to state a general opinion. The cases presented were selected in order to analyse the type of patients and hip deformities for which intertrochanteric osteotomies are considered and also to assess what type of radiological investigations are used in this decision-making process.

We believe that the cases presented are representative; however 45 (29%) of the surgeons who indicated that there was a place for intertrochanteric osteotomies in clinical practice did not recommend an intertrochanteric osteotomy in any of the cases.

There was a clear consensus that osteotomies should be reserved for younger patients and that THR was indicated in the older patient. This is consistent with the results from the literature [6, 19, 29].

The results of the survey showed a significant correlation between the level of symptoms and the choice for conservative treatment. One case consisted of a 31-year-old patient with minimal complaints (Merle d'Aubigne score 16 out of 18) with a mild dysplasia (Sharp angle 50° , CE angle 14°) and coxa valga (CCD 140°). In this case, 58% advised conservative therapy.

In patients already suffering from hip complaints (although only minor), it is thought that the development

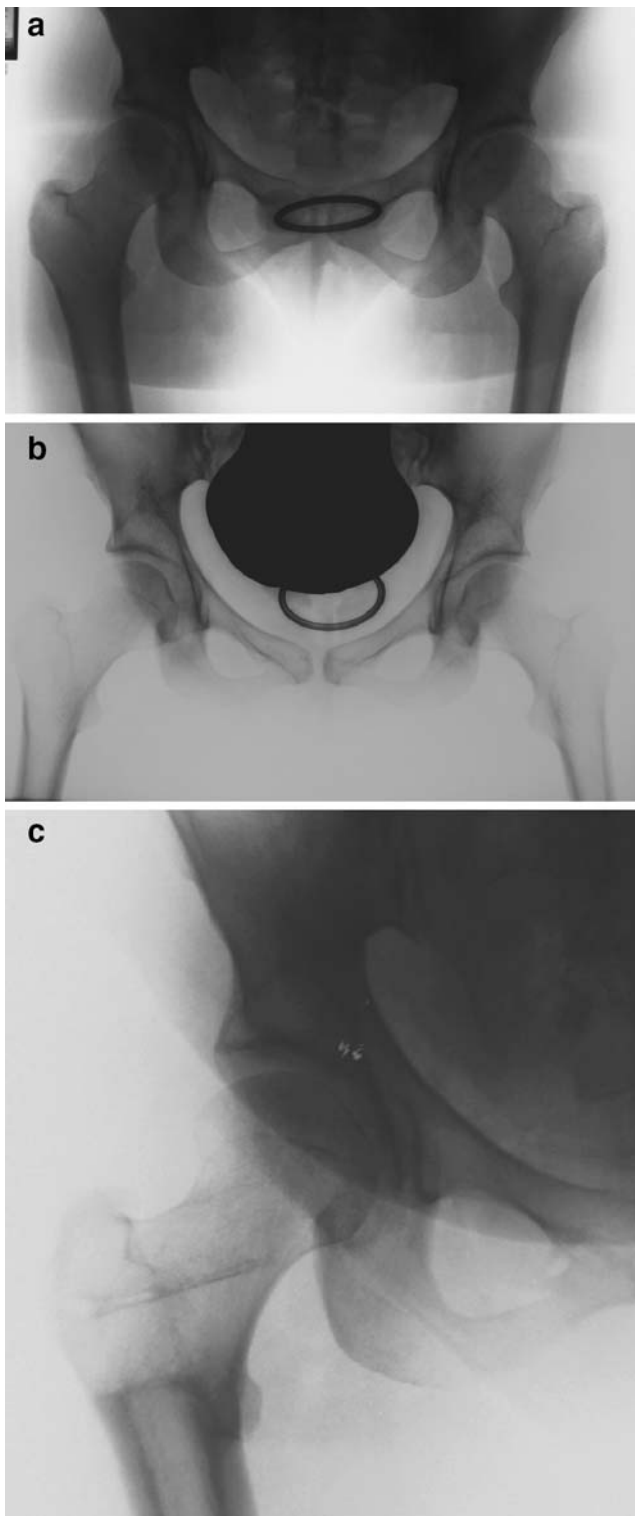


Fig. 2a–c Example of a case (case 3). **a** A 31-year-old female, with minor complaints of the right hip (Merle d’Aubigne score 16). ROM was full. Radiological measurements for right hip: Sharp angle 50°, CE angle 14°, CCD 140°. **b** Abduction correction view. **c** Long-term follow up after 18 years

of OA is inevitable [11, 14]. Several authors have mentioned that, in these patients especially, early intervention could be rewarding [6, 9, 19, 23]. This view is clearly not shared commonly.

In hips where the main deformity is on the acetabular side, an acetabular realigning procedure is the preferred surgical choice. In hips where the problem on the acetabular side is mild and where there is also a problem on the femoral side, a femoral osteotomy could be just as effective. In our cases, two of these types of patients were included (cases 1 and 3). Those who chose joint-saving surgery were equally divided among PAO and ITO supporters. The available literature shows that good long-term results can be obtained with intertrochanteric osteotomies in these patients [6].

The declining role of osteotomies could also be caused by patient preferences. Modern patients mostly wish to have a quick result, which is easier to obtain with a THR than with an osteotomy. A second patient preference could be that patients are no longer satisfied with the good results that can be obtained with an osteotomy, but want the excellent results that a THR could probably provide. It is important for us to inform patients of the long-term effects that this decision could have and to advise osteotomies in those patients who could benefit from it.

Many orthopaedic surgeons believe that the long-term outcome of a subsequent THR is impaired after a previous osteotomy. This view does not seem to influence the decision as to whether to perform or recommend intertrochanteric osteotomies. In the literature, several reports on THR after osteotomies are available but with conflicting views. However, it appears that the long-term outcome of the THR is not impaired after a previous osteotomy [7].

Our survey shows that, even among experts, the role of intertrochanteric osteotomies is declining. Only a few are performed each year although most surgeons believe they should still be performed today. The current use of intertrochanteric osteotomy is limited to a select group of young and active patients. By identifying the right indications, we should preserve intertrochanteric osteotomies from complete extinction.

References

1. Castaing J, Marcillaud G (1981) Varus osteotomy in severe arthrosis of the hip—a long-term study [author’s translation]. *Rev Chir Orthop Reparatrice Appar Mot* 67:267–277
2. Collert S, Gillstrom P (1979) Osteotomy in osteoarthritis of the hip. A prospective study. *Acta Orthop Scand* 50:555–561
3. DePalma AF, Rothman RH, Klemek JS (1970) Osteotomy of the proximal femur in degenerative arthritis. *Clin Orthop Relat Res* 73:109–115
4. D’Souza SR, Sadiq S, New AM, Northmore-Ball MD (1998) Proximal femoral osteotomy as the primary operation for young

- adults who have osteoarthritis of the hip. *J Bone Joint Surg Am* 80:1428–1438
5. Gotoh E, Inao S, Okamoto T, Ando M (1997) Valgus-extension osteotomy for advanced osteoarthritis in dysplastic hips. Results at 12 to 18 years. *J Bone Joint Surg Br* 79(4):609–615
 6. Haverkamp D, Eijer H, Patt TW, Marti RK (2006) Multi directional intertrochanteric osteotomy for primary and secondary osteoarthritis—results after 15 to 29 years. *Int Orthop* 30(1):615–620
 7. Haverkamp D, de Jong PT, Marti RK (2006) Intertrochanteric osteotomies do not impair long-term outcome of subsequent cemented total hip arthroplasties. *Clin Orthop Relat Res* 444:154–160
 8. Ito K, Matsuno T, Minami A (2005) Intertrochanteric varus osteotomy for osteoarthritis in patients with hip dysplasia: 6–28 years follow up. *Clin Orthop Relat Res* 433:124–128
 9. Iwase T, Hasegawa Y, Kawamoto K, Iwasada S, Yamada K, Iwata H (1996) Twenty years' followup of intertrochanteric osteotomy for treatment of the dysplastic hip. *Clin Orthop Relat Res* 331:245–255
 10. Jingushi S, Sugioka Y, Noguchi Y, Miura H, Iwamoto Y (2002) Transtrochanteric valgus osteotomy for the treatment of osteoarthritis of the hip secondary to acetabular dysplasia. *J Bone Joint Surg Br* 84:535–539
 11. Klaue K, Durnin CW, Ganz R (1991) The acetabular rim syndrome. A clinical presentation of dysplasia of the hip. *J Bone Joint Surg Br* 73:423–429
 12. Kubo T, Horii M, Yamaguchi J, et al (2000) Acetabular labrum in hip dysplasia evaluated by radial MRI. *J Rheumatol* 27:1955–1961
 13. Langlais F, Roure JL, Maquet P (1979) Valgus osteotomy in severe osteoarthritis of the hip. *J Bone Joint Surg Br* 61-B:424–431
 14. Leunig M, Beck M, Dora C, Ganz R (2006) Femoroacetabular impingement: trigger for the development of osteoarthritis. *Orthopade* 35:77–84
 15. Linde F, Pallesen R (1985) Osteoarthritis of the hip in patients under 60 years of age. A study of the importance of pain at rest as an indication for intertrochanteric osteotomy. *Arch Orthop Trauma Surg* 104(5):267–270
 16. Maistrelli GL, Gerundini M, Fusco U, Bombelli R, Bombelli M, Avai A (1990) Valgus-extension osteotomy for osteoarthritis of the hip. Indications and long-term results. *J Bone Joint Surg Br* 72:653–657
 17. Marti RK, Chaldecott LR, Kloen P (2001) Intertrochanteric osteotomy for posttraumatic arthritis after acetabular fractures. *J Orthop Trauma* 15:384–393
 18. Miegel RE, Harris WH (1984) Medial-displacement intertrochanteric osteotomy in the treatment of osteoarthritis of the hip. A long-term follow-up study. *J Bone Joint Surg Am* 66:878–887
 19. Millis MB, Kim YJ (2002) Rationale of osteotomy and related procedures for hip preservation: a review. *Clin Orthop* 405:108–121
 20. Morsscher E (1971) Die intertrochantere Osteotomie bei Coxarthrose. Verlag Hans Huber, Bern
 21. Pecasse GA, Eijer H, Haverkamp D, Marti RK (2004) Intertrochanteric osteotomy in young adults for sequelae of Legg-Calve-Perthes' disease—a long term follow-up. *Int Orthop* 28:44–47
 22. Pellicci P, Hu S, Garvin K, Salvati E, Wilson PJ (1991) Varus rotational femoral osteotomies in adults th hip dysplasia. *Clin Orthop Relat Res* 272:162–166
 23. Perla R, Wilson MG, Poss R (1996) Isolated proximal femoral osteotomy for treatment of residua of congenital dysplasia or idiopathic osteoarthritis of the hip. Five to ten-year results. *J Bone Joint Surg Am* 78:1462–1467
 24. Reigstad A, Gronmark T (1984) Osteoarthritis of the hip treated by intertrochanteric osteotomy. A long-term follow-up. *J Bone Joint Surg Am* 66:1–6
 25. Santore RF, Bombelli R (1983) Long-term follow-up of the Bombelli experience with osteotomy for osteoarthritis: results at 11 years. *Hip* 1983:106–128
 26. Schneider R (1966) Mehrjahresresultate eines Kollektivs von 100 intertrochanteren Osteotomien bei Coxarthrose. *Helv Chir Acta* 33:185–205
 27. Teinturier P, Levai JP, Collin JP, Terver S (1982) Intertrochanteric flexion osteotomy as an only alternative to total hip arthroplasty in advanced osteoarthritis. A ten-year follow-up. *Clin Orthop Relat Res* 166:158–161
 28. Toyama H, Endo N, Sofue M, Dohmae Y, Takahashi HE (2000) Relief from pain after Bombelli's valgus-extension osteotomy, and effectiveness of the combined shelf operation. *J Orthop Sci* 5:114–123
 29. Turgeon TR, Phillips W, Kantor SR, Santore RF (2005) The role of acetabular and femoral osteotomies in reconstructive surgery of the hip: 2005 and beyond. *Clin Orthop Relat Res* 441:188–199
 30. Weisl H (1980) Intertrochanteric osteotomy for osteoarthritis. A long-term follow-up. *J Bone Joint Surg Br* 62-B:37–42
 31. Zaoussis AL, Adamopoulos G, Geraris G, Manoloudis M, Galanis I (1984) Osteotomy for osteoarthritis of the hip. A clinical and radiological survey. *Int Orthop* 7(4):223–228