



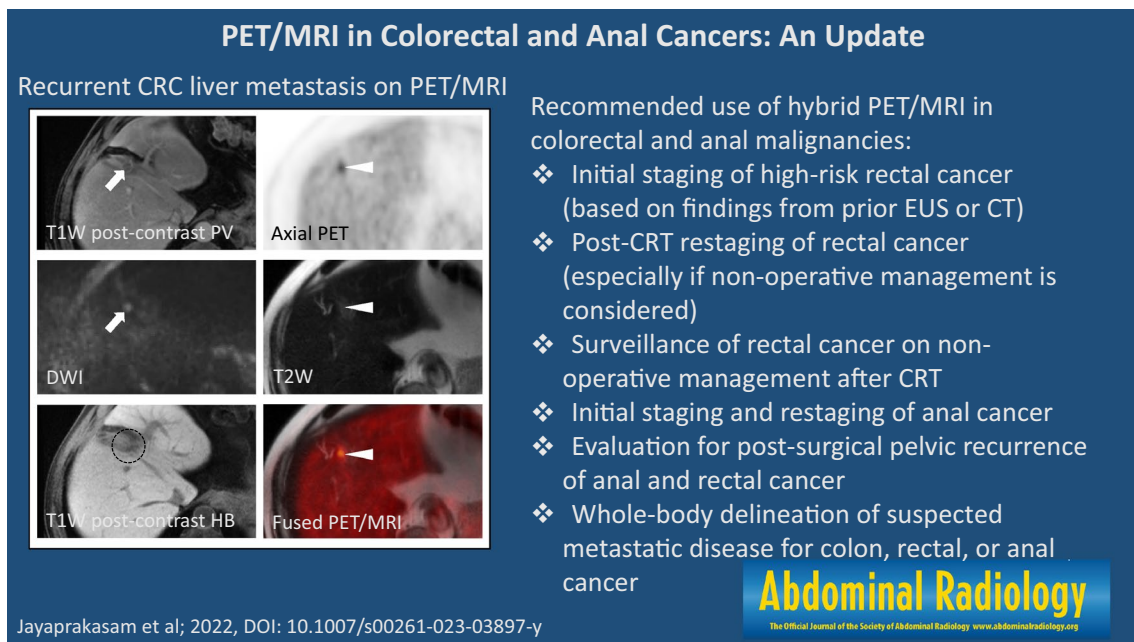
Correction to: PET/MRI in colorectal and anal cancers: an update

Vetri Sudar Jayaprakasam¹ · Semra Ince² · Garima Suman³ · Pankaj Nepal⁴ · Thomas A. Hope⁵ · Raj Mohan Paspulati⁶ · Tyler J. Fraum²

Published online: 23 November 2023
© Springer Science+Business Media, LLC, part of Springer Nature 2023

Correction to: Abdominal Radiology
<https://doi.org/10.1007/s00261-023-03897-y>

In the original version of this article, the graphic abstract was missing and it should appear as below:



The original article has been corrected.

The original article can be found online at <https://doi.org/10.1007/s00261-023-03897-y>.

✉ Vetri Sudar Jayaprakasam
jayprav@mskcc.org
<http://www.mskcc.org>

¹ Molecular Imaging and Therapy Service, Department of Radiology, Memorial Sloan Kettering Cancer Center, 1275 York Avenue, New York, NY 10065, USA

Publisher's Note Springer Nature remains neutral with regard to jurisdictional claims in published maps and institutional affiliations.

- ² Department of Radiology, Washington University School of Medicine, Saint Louis, MO, USA
- ³ Department of Radiology, Mayo Clinic, Rochester, MN, USA
- ⁴ Department of Radiology, Massachusetts General Hospital, Boston, MA, USA
- ⁵ Department of Radiology & Biomedical Imaging, University of California, San Francisco, CA, USA
- ⁶ Department of Radiology, Moffitt Cancer Center, Tampa, FL, USA