



# Unique [ $^{18}\text{F}$ ]FDG PET imaging pattern of drug-induced acute generalized exanthematous pustulosis within the SCAR-spectrum

E. Novruzov<sup>1</sup> · D. Schmitt<sup>1</sup> · Y. Mori<sup>1</sup> · J. Kirchner<sup>2</sup> · G. Kobbe<sup>3</sup> · J. Reifenberger<sup>4</sup> · E. Mamlins<sup>1</sup> · C. Antke<sup>1</sup> · F. L. Giesel<sup>1</sup>

Received: 20 September 2022 / Accepted: 24 November 2022 / Published online: 9 December 2022  
© The Author(s) 2022

Severe cutaneous adverse reactions (SCARs) including acute generalized exanthematous pustulosis (AGEP) are usually medication-related and represent a rare, heterogeneous group of T-cell-triggered delayed hypersensitivity reactions resulting from interactions between small molecule drugs, human leucocyte antigen (HLA) Class I molecules, and T-cell receptors (TCR) [1–5].

A 62-year-old male patient with an anaplastic large T-cell lymphoma in medical history presented in our clinic with an abrupt onset of generalized maculopapular exanthema without mucosal involvement after initiating antibiotic therapy with a combination of caspofungin, vancomycin, and meropenem due to community-acquired pneumonia. A whole-body [ $^{18}\text{F}$ ]FDG PET/CT scan, performed four days after initial symptoms, demonstrated a very striking pattern of uniformly increased metabolic uptake throughout

the skin. A marked [ $^{18}\text{F}$ ]FDG uptake was observed in the spine and spleen ( $\text{SUV}_{\text{max}}$ : 7,4) due to systemic inflammatory response. Moreover, the neck and groin areas exhibited also an intense tracer uptake ( $\text{SUV}_{\text{max}}$ : 7,3) mainly due to a partial volume effect and, to a lesser extent, physical stress in the skinfold areas in addition to the abovementioned dermatological changes. The elevated [ $^{18}\text{F}$ ]FDG uptake at the injection site in the right wrist is also to be mentioned. Skin biopsy revealed a superficial perivascular dermatitis with infiltration of the outermost layer of the dermis by lymphocytes, histiocytes, and single plasma cells, accompanied by focal parakeratosis and minimal spongiotic loosening of the stratum corneum (e).

To our best knowledge, this is the first metabolic imaging of SCAR syndrome, in particular meropenem-induced AGEP, using [ $^{18}\text{F}$ ]FDG PET/CT scan.

This article is part of the Topical Collection on Image of the month

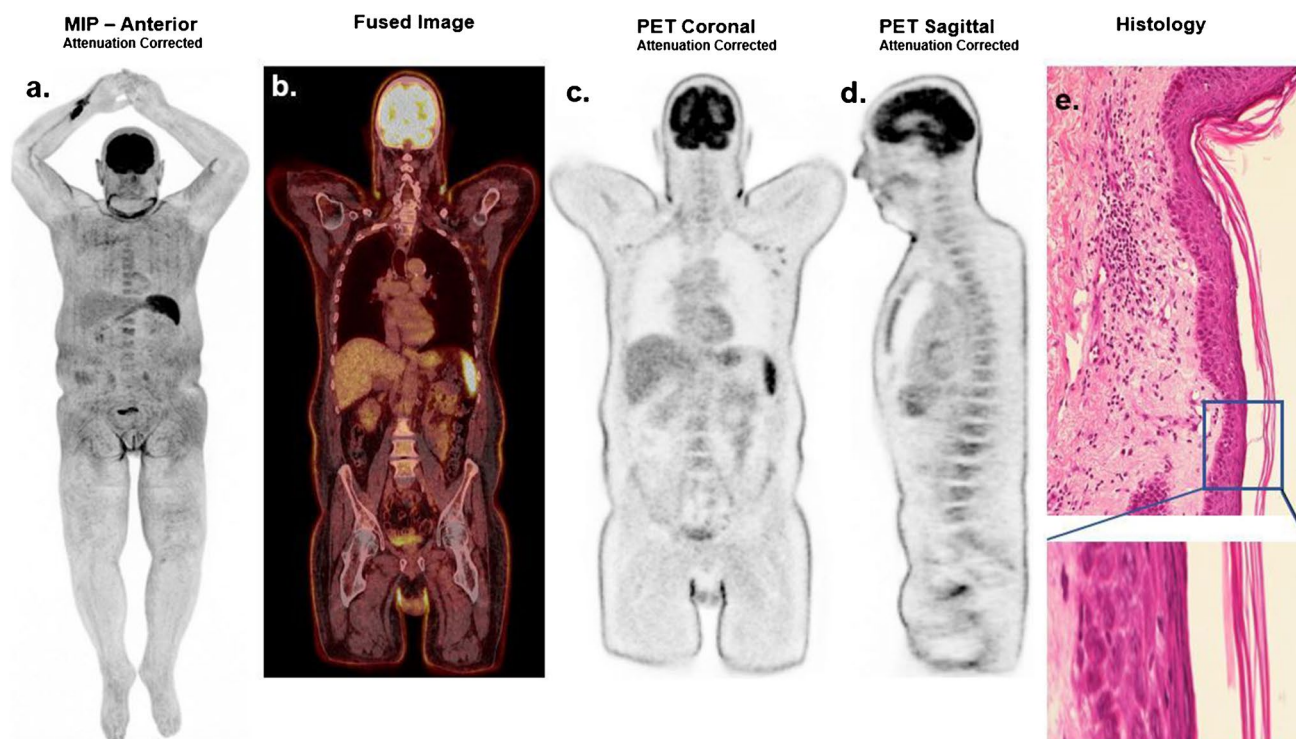
✉ E. Novruzov  
emil.novruzov@med.uni-duesseldorf.de

<sup>1</sup> Department of Nuclear Medicine, Medical Faculty, Heinrich-Heine-University, University Hospital Dusseldorf, Dusseldorf, Germany

<sup>2</sup> Department of Diagnostic and Interventional Radiology, Medical Faculty, Heinrich-Heine-University, University Hospital Dusseldorf, Dusseldorf, Germany

<sup>3</sup> Department of Hematology, Oncology and Clinical Immunology, Medical Faculty, Heinrich-Heine-University, University Hospital Dusseldorf, Dusseldorf, Germany

<sup>4</sup> Department of Dermatology, Medical Faculty and University Hospital Dusseldorf, Heinrich-Heine-University Dusseldorf, Dusseldorf, Germany



**Funding** Open Access funding enabled and organized by Projekt DEAL.

#### Declarations

All procedures were in accordance with the ethical standards of the institutional and/or national research committee and with the 1964 Helsinki Declaration and its later amendments or comparable ethical standards. For case reports from clinical practice, no trial registration is required.

**Conflict of interest** FLG is a medical advisor for ABX, Advanced Biochemical Compound and Telix Pharmaceuticals. The other authors have no relevant financial or non-financial interests to disclose.

**Open Access** This article is licensed under a Creative Commons Attribution 4.0 International License, which permits use, sharing, adaptation, distribution and reproduction in any medium or format, as long as you give appropriate credit to the original author(s) and the source, provide a link to the Creative Commons licence, and indicate if changes were made. The images or other third party material in this article are included in the article's Creative Commons licence, unless indicated otherwise in a credit line to the material. If material is not included in the article's Creative Commons licence and your intended use is not permitted by statutory regulation or exceeds the permitted use, you will need to obtain permission directly from the copyright holder. To view a copy of this licence, visit <http://creativecommons.org/licenses/by/4.0/>.

#### References

1. Ghoshal L, Nandi S, Sarkar A, Das S. Acute generalized exanthematous pustulosis due to meropenem: An unusual side effect of a commonly used drug. *Indian Dermatol Online J.* 2015;6(6):446–8. <https://doi.org/10.4103/2229-5178.169711>.
2. Adler NR, Aung AK, Ergen EN, Trubiano J, Goh MSY, Phillips EJ. Recent advances in the understanding of severe cutaneous adverse reactions. *Br J Dermatol.* 2017;177(5):1234–47. <https://doi.org/10.1111/bjd.15423>.
3. Sidoroff A, Halevy S, Bavinck JN, Vaillant L, Roujeau JC. Acute generalized exanthematous pustulosis (AGEP)—a clinical reaction pattern. *J Cutan Pathol.* 2001;28(3):113–9. <https://doi.org/10.1034/j.1600-0560.2001.028003113.x>.
4. Mohaghegh F, Hatami P, Aryanian Z, Fatemi F, Mohseni Afshar Z. Acute generalized exanthematous pustulosis following SARS-CoV-2 virus: remdesivir as a suspected culprit. *Case Rep Med.* 2022;2022:9880827. <https://doi.org/10.1155/2022/9880827>.
5. Khalel MH, Fattah Saleh SA, El-Gamal AHF, Najem N. Acute generalized exanthematous pustulosis: an unusual side effect of meropenem. *Indian J Dermatol.* 2010;55(2):176–7. <https://doi.org/10.4103/0019-5154.62759>.

**Publisher's note** Springer Nature remains neutral with regard to jurisdictional claims in published maps and institutional affiliations.