



Correction to: [^{18}F]FDG -PET/CT uptake reveals a single metastasis inside vertebral hemangioma, catch me if you scan

Yogev Cohen^{1,2} · Albert Grinshpun^{1,2} · Karen Meir³ · Jeremy Godefroy⁴

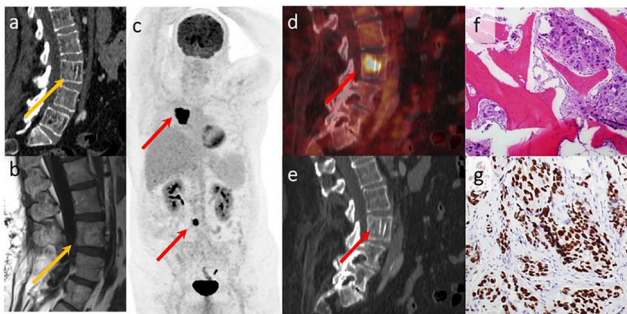
Published online: 5 April 2021

© Springer-Verlag GmbH Germany, part of Springer Nature 2021

Correction to: Eur J Nucl Med Mol Imaging

<https://doi.org/10.1007/s00259-021-05200-x>

The authors regret that the image in the original article appears to be very blurry. In line with this, the authors wishes to replace it with a better version of the figure. The correct figure appears below.



Publisher's note Springer Nature remains neutral with regard to jurisdictional claims in published maps and institutional affiliations.

This article is part of the Topical Collection on Erratum

The online version of the original article can be found at <https://doi.org/10.1007/s00259-021-05200-x>

✉ Albert Grinshpun
albertg@hadassah.org.il

¹ Sharett Institute of Oncology, Hadassah-Hebrew University Medical Center, Jerusalem, Israel

² Wohl Institute for Translational Medicine, Hadassah-Hebrew University Medical Center, Jerusalem, Israel

³ Department of Pathology, Hadassah-Hebrew University Medical Center, Jerusalem, Israel

⁴ Department of Nuclear Medicine, Hadassah-Hebrew University Medical Center, Jerusalem, Israel