



Reconstruction method to combine high temporal resolution with appropriate image quality in dynamic PET angiography

Christian Kühnel¹ · Philipp Seifert¹ · Robert Drescher¹ · Martin Freesmeyer¹ 

Received: 3 July 2020 / Accepted: 15 July 2020 / Published online: 23 July 2020
© The Author(s) 2020

Dear Sir,

With great interest, we read the Image of the Month article by Norikane et al., “One-stop shopping 18F-FDG PET/CT in a patient with vascular type Behcet’s disease” [1]. They describe the application of PET angiography to depict venous vascular malformations. The images shown are of outstanding quality, clearly depicting the vascular anatomy and hemodynamics in the first 21 s after tracer injection.

PET angiography is based on a continuous, dynamic PET acquisition starting simultaneously with tracer injection [2]. Images are reconstructed retrospectively from the list-mode raw data in user-selected time intervals (frames), which may range from few seconds to several minutes [3].

When considering the length of frames which should be reconstructed, a tradeoff has to be made between temporal resolution and signal-to-noise ratio of the resulting image sequence. A shorter frame represents a shorter snapshot of the hemodynamic evolution of the tracer bolus in the vasculature, but image quality may be limited due to poor count statistics. A longer frame contains more PET data for reconstruction, leading to higher image quality for visualization of detail. However, the dynamic information is averaged over the length of the frame.

Norikane et al. were able to achieve high image quality in consecutive 3-s frames because a venous circulation was

depicted after intravenous injection of the radiotracer. For PET angiography of arteries, a relevant dilution of the tracer bolus occurs in the cardiopulmonary circulation until it reaches the target vessels [4]. Frame lengths of at least 7–10 s are necessary.

An option to combine high temporal resolution with appropriate image quality in dynamic PET angiography, particularly for an animated display of the findings, is to reconstruct interleaved frames from the PET data, while preserving frame duration. In the presented case, 7-s frames were reconstructed with a 1 s time offset, e.g., 0–7 s, 1–8 s, 2–9 s, and so on (matrix 400, iterations 4, subsets 12 and Gaussian filter FWHM 5; performed with HD TrueX software, Siemens Healthineers, Erlangen, Germany). Each resulting image contains the averaged temporal information of 7 s of blood flow. The images are merged into a new sequence. A frame length of 7 s ensures sufficient image quality, and the short intervals of 1 s avoid loss of temporal information which would happen with the standard reconstruction method (Fig. 1). Visual smoothness of blood flow depiction is improved (Suppl. 1).

The described “reframing” method requires a significant technical effort, but may be helpful for specific cases with complicated vascular malformations, for demonstration purposes, and in patients with contraindications to other imaging methods.

This article is part of the Topical Collection on Technology

Electronic supplementary material The online version of this article (<https://doi.org/10.1007/s00259-020-04962-0>) contains supplementary material, which is available to authorized users.

✉ Martin Freesmeyer
martin.freesmeyer@med.uni-jena.de

¹ Clinic of Nuclear Medicine, Jena University Hospital, Am Klinikum 1, 07747 Jena, Germany

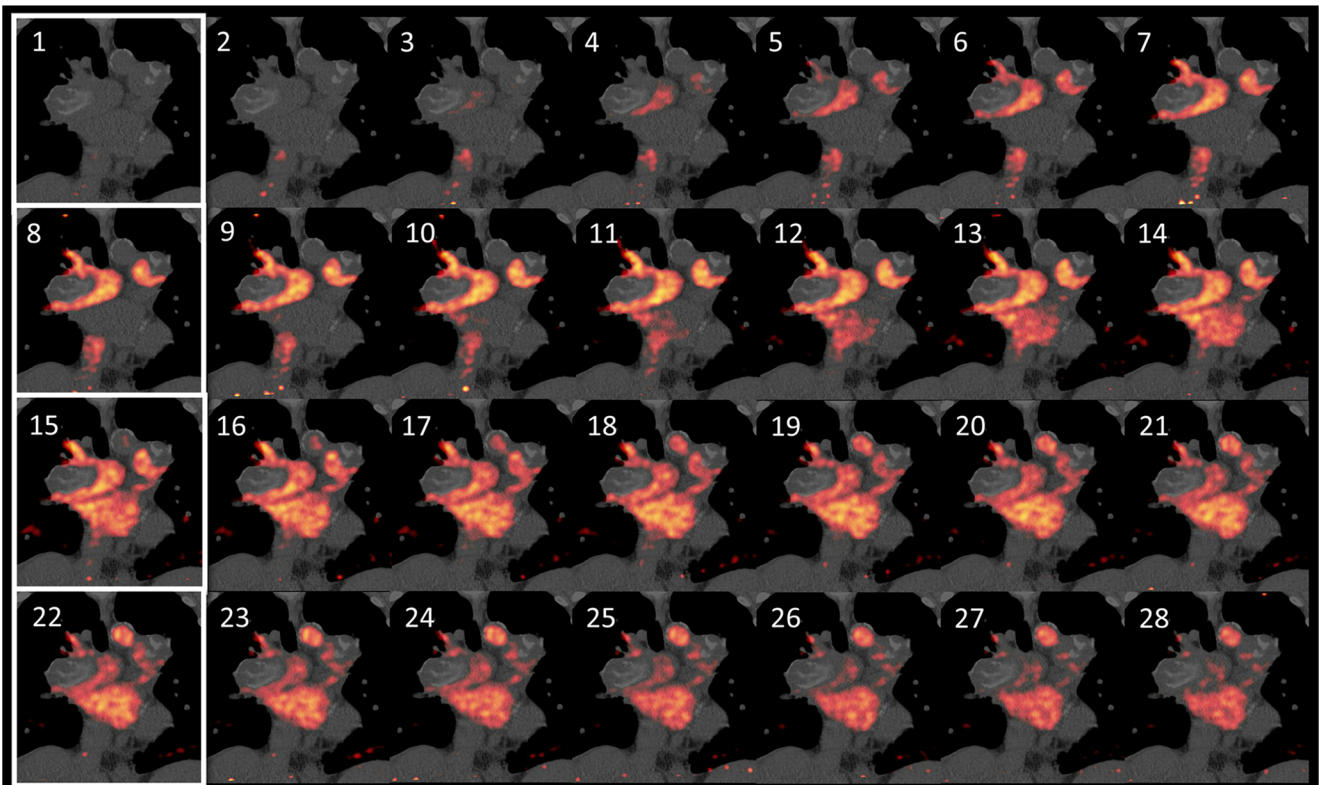


Fig. 1 Image sequence of interleaved reconstruction. Interval between images is 1 s. A conventional reconstruction of the same data would only consist of images 1, 8, 15, and 22 (white margins). Wall-adherent, calcified thrombi are seen in the pulmonary arteries

Funding information Open Access funding provided by Projekt DEAL. The project was funded solely from the internal Clinic of Nuclear Medicine, University Hospital Jena, budget.

Compliance with ethical standards

Conflict of interest The authors declare that they have no conflict of interest.

Ethical approval Written informed consent was obtained from the patient to reproduce anonymized image and video. All procedures performed in studies involving human participants were in accordance with the ethical standards of the institutional research committee and with the 1964 Helsinki declaration and its later amendments or comparable ethical standards.

Open Access This article is licensed under a Creative Commons Attribution 4.0 International License, which permits use, sharing, adaptation, distribution and reproduction in any medium or format, as long as you give appropriate credit to the original author(s) and the source, provide a link to the Creative Commons licence, and indicate if changes were made. The images or other third party material in this article are included in the article's Creative Commons licence, unless indicated otherwise in a credit line to the material. If material is not included in the article's Creative Commons licence and your intended use is not permitted by statutory regulation or exceeds the permitted use, you will need to obtain permission directly from the copyright holder. To view a copy of this licence, visit <http://creativecommons.org/licenses/by/4.0/>.

References

1. Norikane T, Yamamoto Y, Takami Y, Mitamura K, Arai-Okuda H, Nishiyama Y. One-stop shopping (18)F-FDG PET/CT in a patient with vascular type Behcet's disease. *Eur J Nucl Med Mol Imaging*. 2019;46(7):1578–80. <https://doi.org/10.1007/s00259-019-04293-9>.
2. Drescher R, Freesmeyer M. PET angiography: application of early dynamic PET/CT to the evaluation of arteries. *AJR Am J Roentgenol*. 2013;201(4):908–11. <https://doi.org/10.2214/AJR.12.10438>.
3. Schierz JH, Opfermann T, Steenbeck J, Lopatta E, Settmacher U, Stallmach A, et al. Early dynamic 18F-FDG PET to detect hyperperfusion in hepatocellular carcinoma liver lesions. *J Nucl Med*. 2013;54(6):848–54. <https://doi.org/10.2967/jnumed.112.113936>.
4. Freesmeyer M, Zanow J, Ludewig S, Drescher R. Multimodal imaging of aortoiliac occlusive disease with three-dimensional postprocessing of PET angiography and CT. *Clin Imaging*. 2014;38(6):877–9. <https://doi.org/10.1016/j.clinimag.2014.05.004>.

Publisher's note Springer Nature remains neutral with regard to jurisdictional claims in published maps and institutional affiliations.