



Test Yourself: Chronic thigh pain and swelling

Sanjay Desai¹ · Devendra Goyal¹ · Amith Gaitonde¹  · Preeti Osan¹ · Sujit Joshi¹

Received: 7 March 2023 / Revised: 28 September 2023 / Accepted: 1 October 2023 / Published online: 13 October 2023
© The Author(s), under exclusive licence to International Skeletal Society (ISS) 2023

Question

A 35-year-old female presented with pain in the right thigh area with gradually progressive swelling for about 10 months. She was unable to sit cross legged or squat. She was otherwise fit and healthy with no co-morbidities. No prior history of trauma or malignancy. Below the radiograph, MRI and CT images are provided (Figs. 1, 2, 3, 4, 5 and 6).

The diagnosis can be found at <https://doi.org/10.1007/s00256-023-04475-5>.

✉ Amith Gaitonde
amitgaitonde03@gmail.com

Sanjay Desai
drsanjaydesai@gmail.com; mskraddmh@gmail.com

Devendra Goyal
devendragoyal4@gmail.com

Preeti Osan
preetiosan2008@gmail.com

Sujit Joshi
sujitjoshi30@gmail.com

¹ Deenanath Mangeshkar Hospital and Research Centre, Pune, India

Fig. 1 Pelvic radiograph

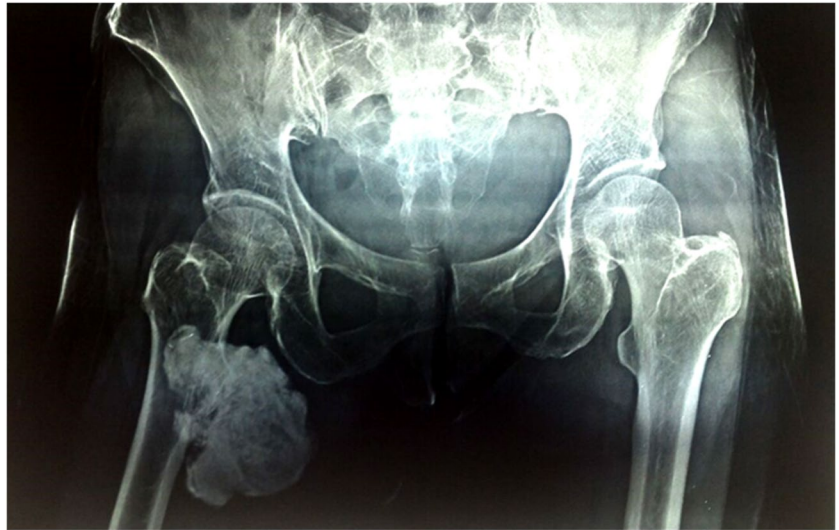

Fig. 2 A (Axial T1) and B (Axial T2)

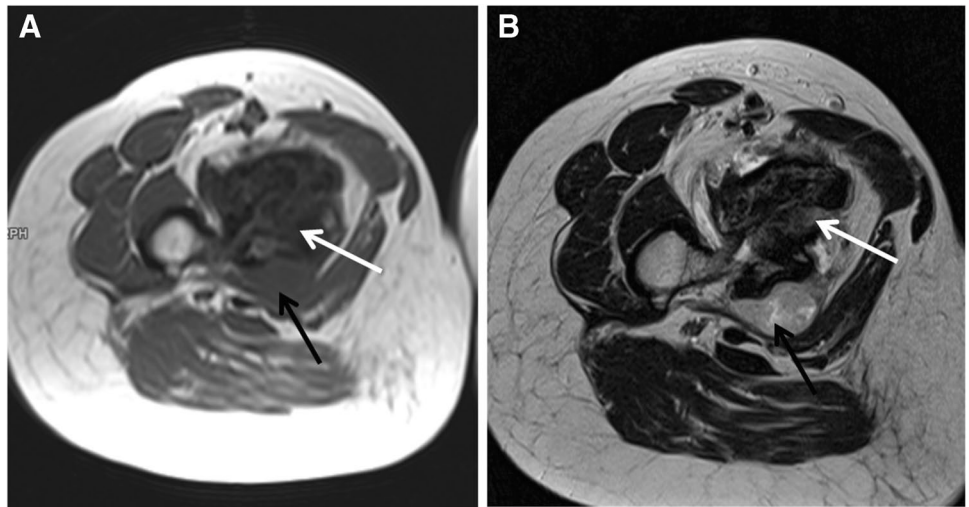


Fig. 3 A (Coronal T2FS) and B (Coronal Post contrast)

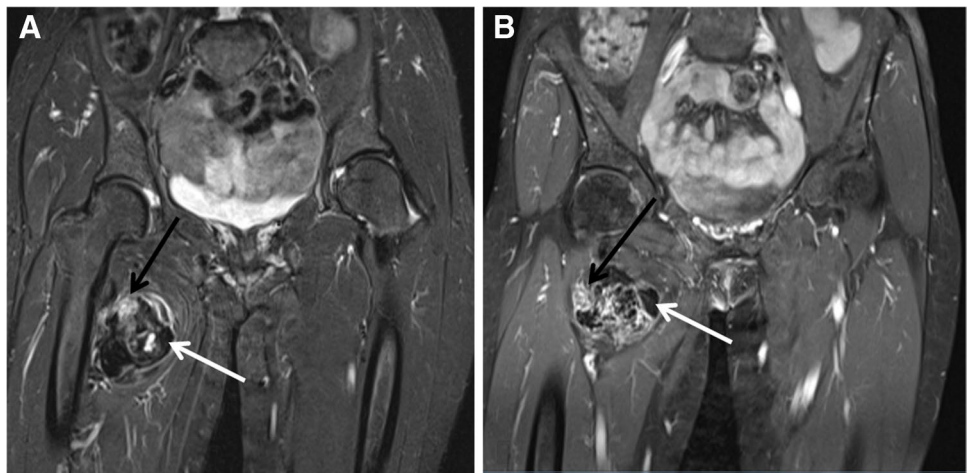


Fig. 4 **A** (Axial CT images in bone window) and **B** (Coronal CT images in bone window)

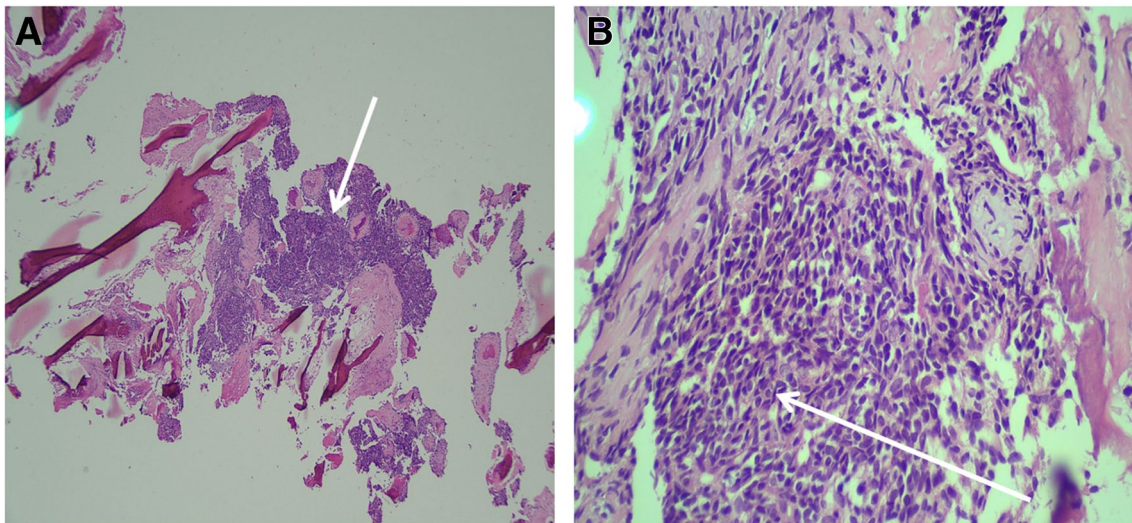
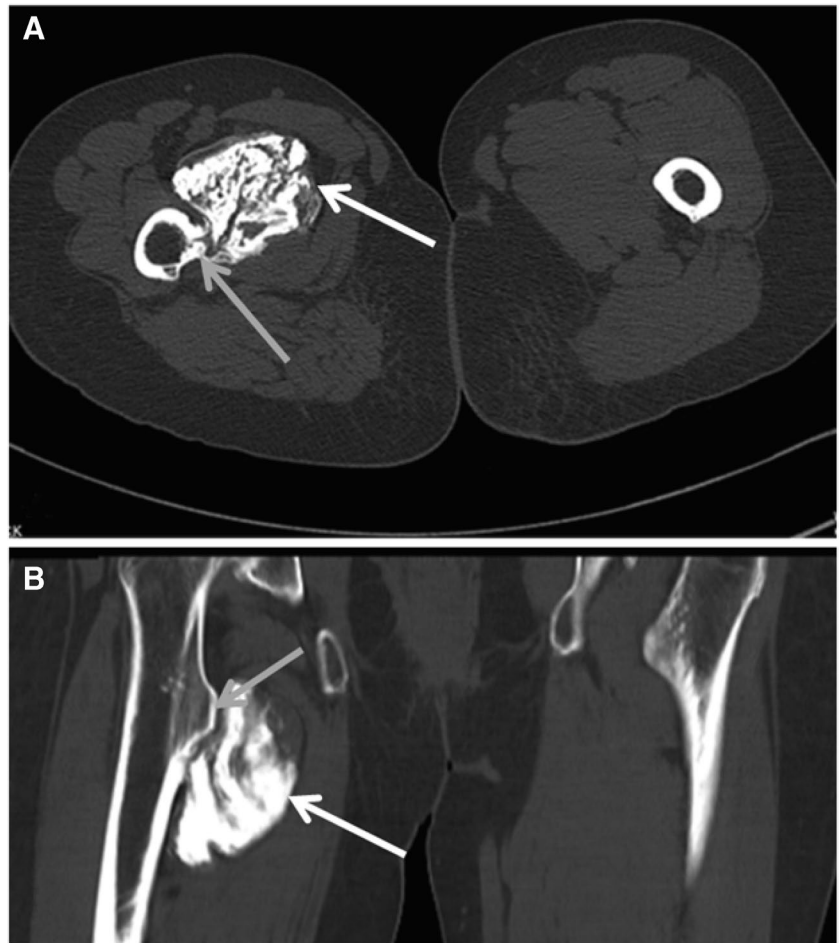


Fig. 5 **A** (HE 4X) and **B** (HE 20X)

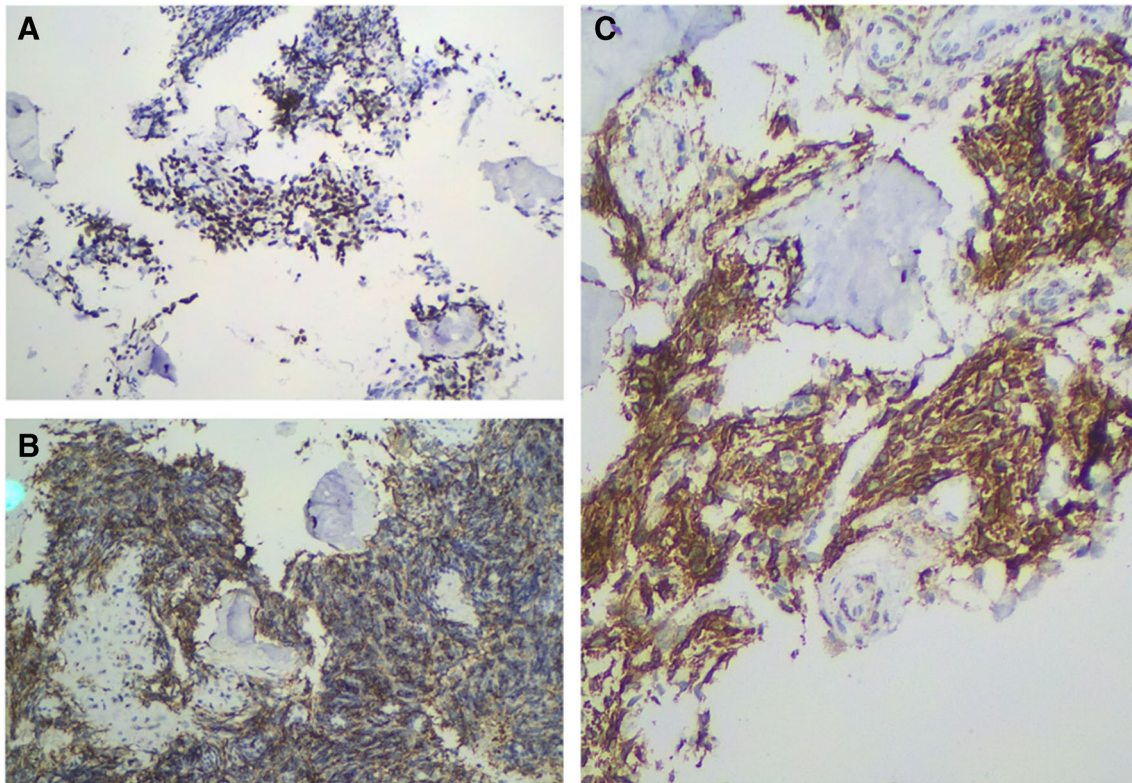


Fig. 6 IHC staining pattern TLE 1(A), MiC 2 (B) and Bcl-2Protein (C)

Declarations

Conflict of interest The authors declare that they have no conflict of interest.

Publisher's Note Springer Nature remains neutral with regard to jurisdictional claims in published maps and institutional affiliations.