



Chronic sciatica without motor deficit

Massimo Donalisio¹ · Michael Egea¹ · Vincent Dunet¹ · Patrick Omoumi¹ · Charbel Mourad¹

Received: 12 April 2023 / Revised: 14 September 2023 / Accepted: 25 September 2023 / Published online: 13 October 2023
© The Author(s), under exclusive licence to International Skeletal Society (ISS) 2023

An 84-year-old woman with prior history of L4-L5 laminectomy and L4 spinous process resection 25 years ago, presented for an acute exacerbation of her chronic right sciatica not responsive to analgesics and non-steroidal anti-inflammatory drugs. There was no motor deficit. After imaging workup (Figs. 1, 2 and 3), she underwent right L3-L4, L4-L5 and L5-S1 facet medial branch block without significant improvement.

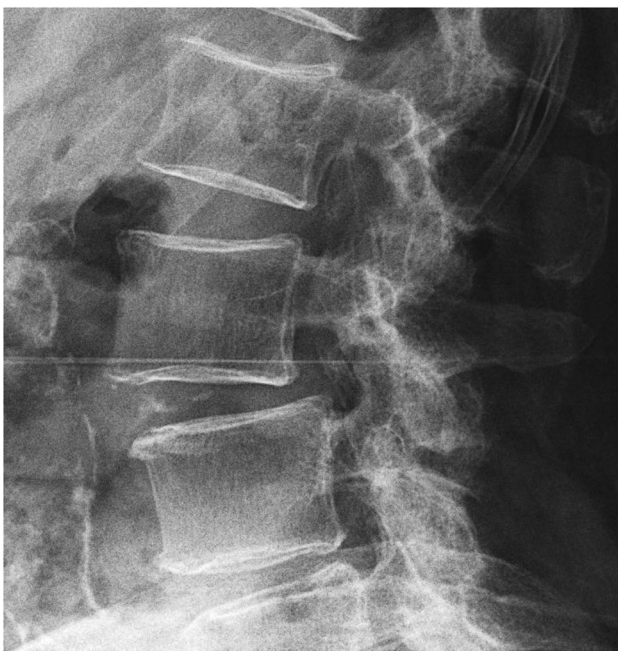


Fig. 1 Conventional radiography of the lumbar spine – lateral view at the level of L2-L4

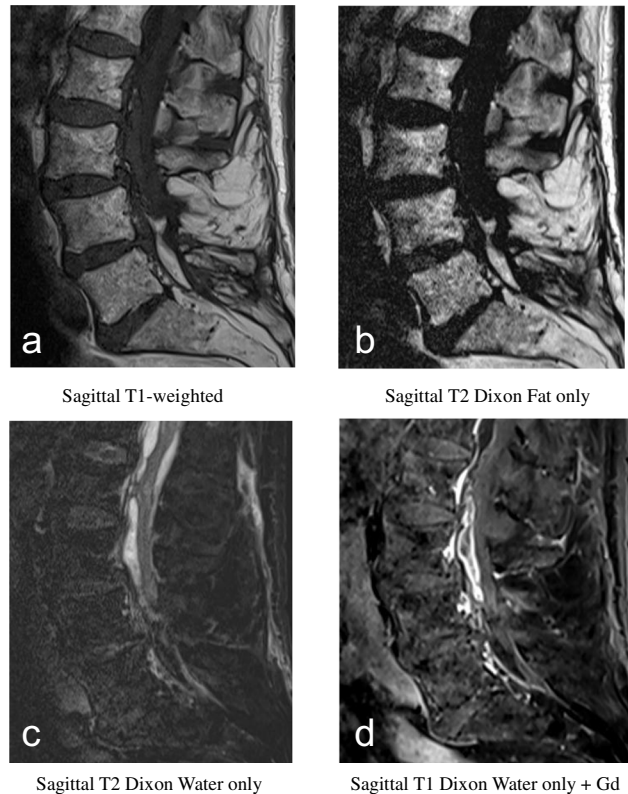


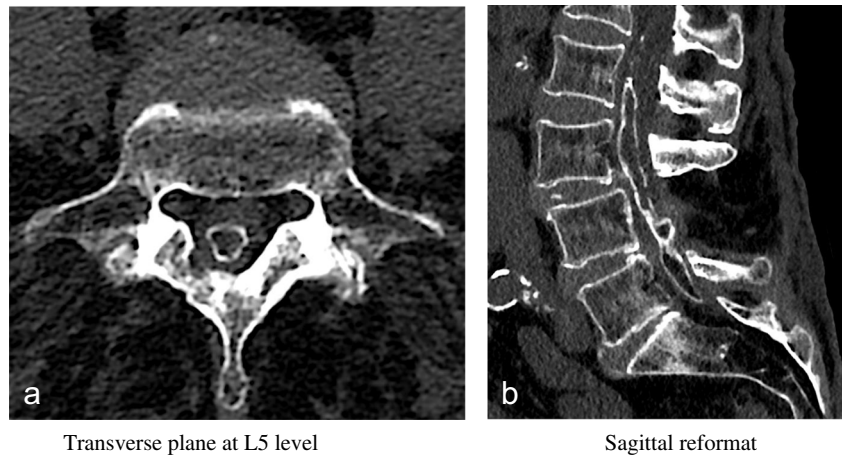
Fig. 2 MRI of the lumbar spine—sagittal plane

The diagnosis can be found at <https://doi.org/10.1007/s00256-023-04465-7>.

✉ Massimo Donalisio
massimo.donalisio@me.com

¹ Department of Radiology, Lausanne University Hospital and University of Lausanne, Rue du Bugnon 46, 1011 Lausanne, VD, Switzerland

Fig. 3 Unenhanced CT scan of the lumbar spine



Transverse plane at L5 level

Sagittal reformat

Declarations

Conflict of interest The authors declare that they have no conflict of interest.

Publisher's note Springer Nature remains neutral with regard to jurisdictional claims in published maps and institutional affiliations.