



Correction to: The 2D and 3D MR arthrographic description of aponeurotic expansion of supraspinatus tendon and biceps tendon anomaly in a large patient cohort

Derya Guclu¹ · Hayri Ogul¹ · Elif Nisa Unlu¹ · Kutsi Tuncer² · Mehmet Kose² · Mecit Kantarci³ · Suat Eren³

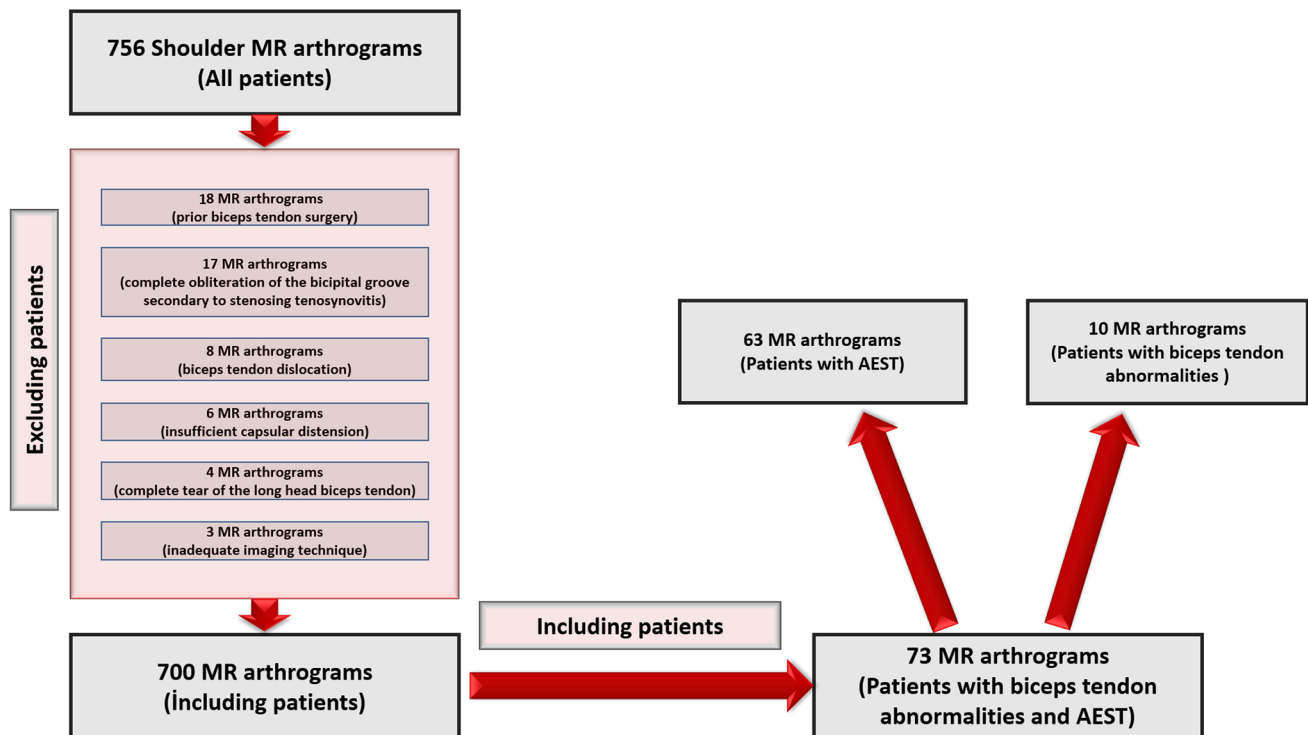
Published online: 16 August 2023

© The Author(s), under exclusive licence to International Skeletal Society (ISS) 2023

Correction to: Skeletal Radiology

<https://doi.org/10.1007/s00256-023-04409-1>

Figure 1 in the original paper is incorrect, the correct fig. 1 should be the below:



The original article has been corrected.

The original article can be found online at <https://doi.org/10.1007/s00256-023-04409-1>.

✉ Hayri Ogul
drhogul@gmail.com

¹ Department of Radiology, Medical Faculty, Duzce University, 81000 Duzce, Turkey

Publisher's note Springer Nature remains neutral with regard to jurisdictional claims in published maps and institutional affiliations.

² Department of Orthopedic Surgery, Medical Faculty, Altinbas University, Istanbul, Turkey

³ Department of Radiology, Medical Faculty, Ataturk University, Erzurum, Turkey