

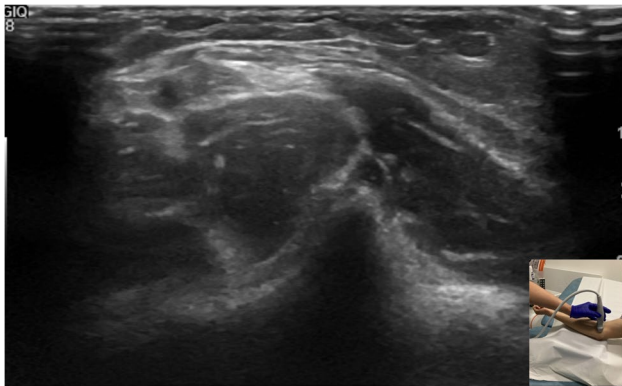


## Elbow pain and clicking

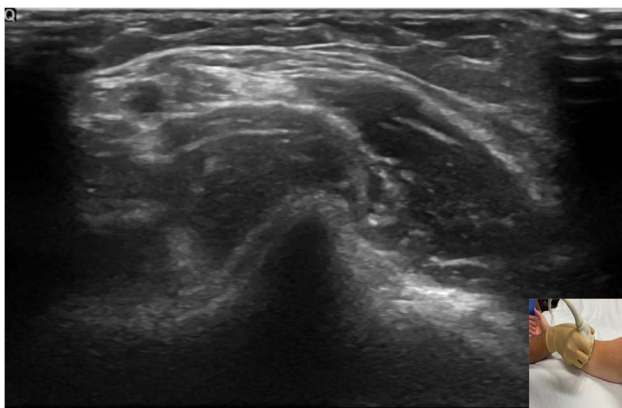
Jun-Li Tham<sup>1</sup> · Zeid Al-Ani<sup>1</sup>

Received: 13 February 2022 / Revised: 24 March 2022 / Accepted: 25 March 2022 / Published online: 29 March 2022  
© Crown 2022

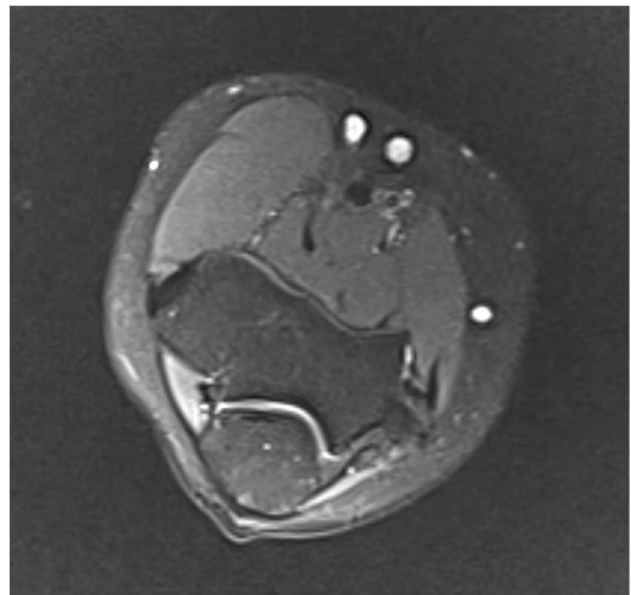
A 25-years-old right-handed female presented with a one-week history of right sided-elbow pain and numbness, with clicking at the anteromedial aspect of the elbow on forearm movement (Figs. 1, 2, 3).



**Fig. 1** Ultrasound image in transverse axis via anterior approach, with elbow in supination



**Fig. 2** Ultrasound image in transverse axis via anterior approach, with elbow in pronation



**Fig. 3** Axial T2 fat-suppressed MRI image of the elbow

**Supplementary Information** The online version contains supplementary material available at <https://doi.org/10.1007/s00256-022-04044-2>.

### Declarations

**Conflict of interest** The authors declare that they have no conflict of interest.

**Publisher's Note** Springer Nature remains neutral with regard to jurisdictional claims in published maps and institutional affiliations.

✉ Jun-Li Tham  
jun-li.tham@wvl.nhs.uk

<sup>1</sup> Radiology Department, Wrightington, Wigan and Leigh NHS foundation Trust, Royal Albert Edward Infirmary, Wigan Lane, Wigan WN1 2NN, UK