



Test Yourself Question: A 36-year-old male presenting with a painful swollen right thigh for several months—no previous history of trauma

Sherif Elsobky¹ · Ramanan Rajakulasingam²  · Monika Madrova³ · Daniel Lindsay³ · Asif Saifuddin²

Received: 17 September 2021 / Revised: 5 December 2021 / Accepted: 10 December 2021 / Published online: 23 December 2021
© Crown 2021

Figures 1, 2, 3 and 4

The diagnosis can be found at <https://doi.org/10.1007/s00256-021-03976-5>

✉ Ramanan Rajakulasingam
ramanan.rajakulasingam1@nhs.net

Sherif Elsobky
sherif.elsobky@nhs.net

Monika Madrova
monika.madrova@nhs.net

Daniel Lindsay
daniel.lindsay@nhs.net

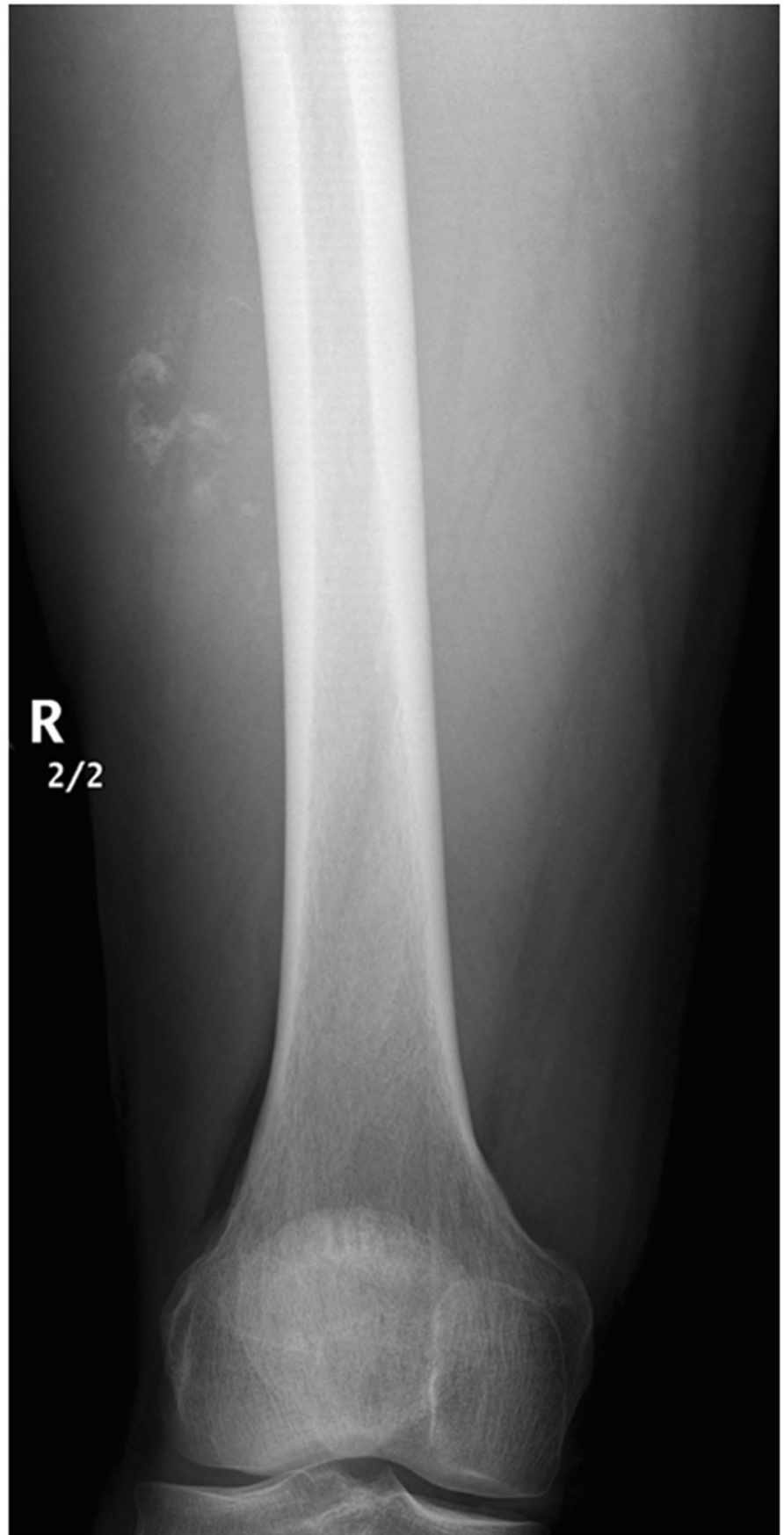
Asif Saifuddin
asif.saifuddin@nhs.net

¹ Department of Radiology, Royal Free NHS Foundation Trust, Pond Street, London NW3 2QG, UK

² Department of Radiology, Royal National Orthopaedic Hospital, Brockley Hill, Stanmore HA7 4LP, UK

³ Department of Histopathology, Royal National Orthopaedic Hospital, Brockley Hill, Stanmore HA7 4LP, UK

Fig. 1 AP radiograph of the right thigh



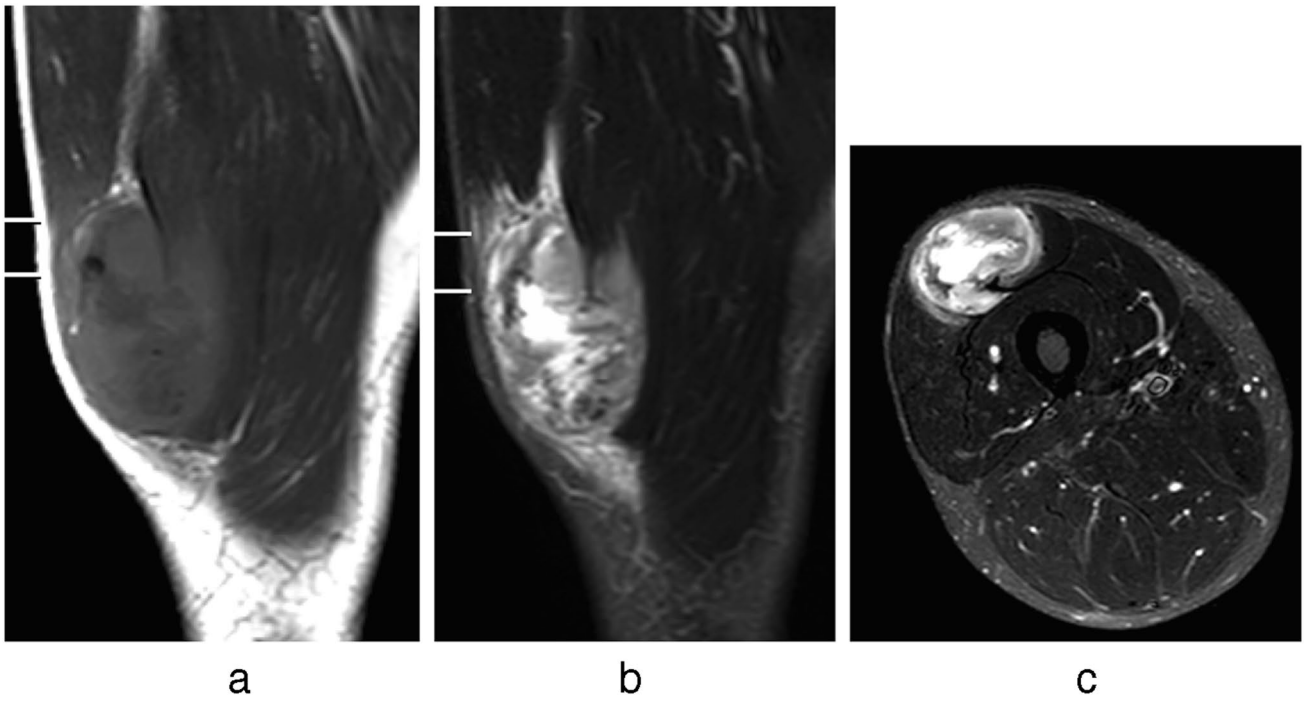


Fig. 2 a Coronal T1W TSE and b coronal and c axial STIR MR images of the right thigh

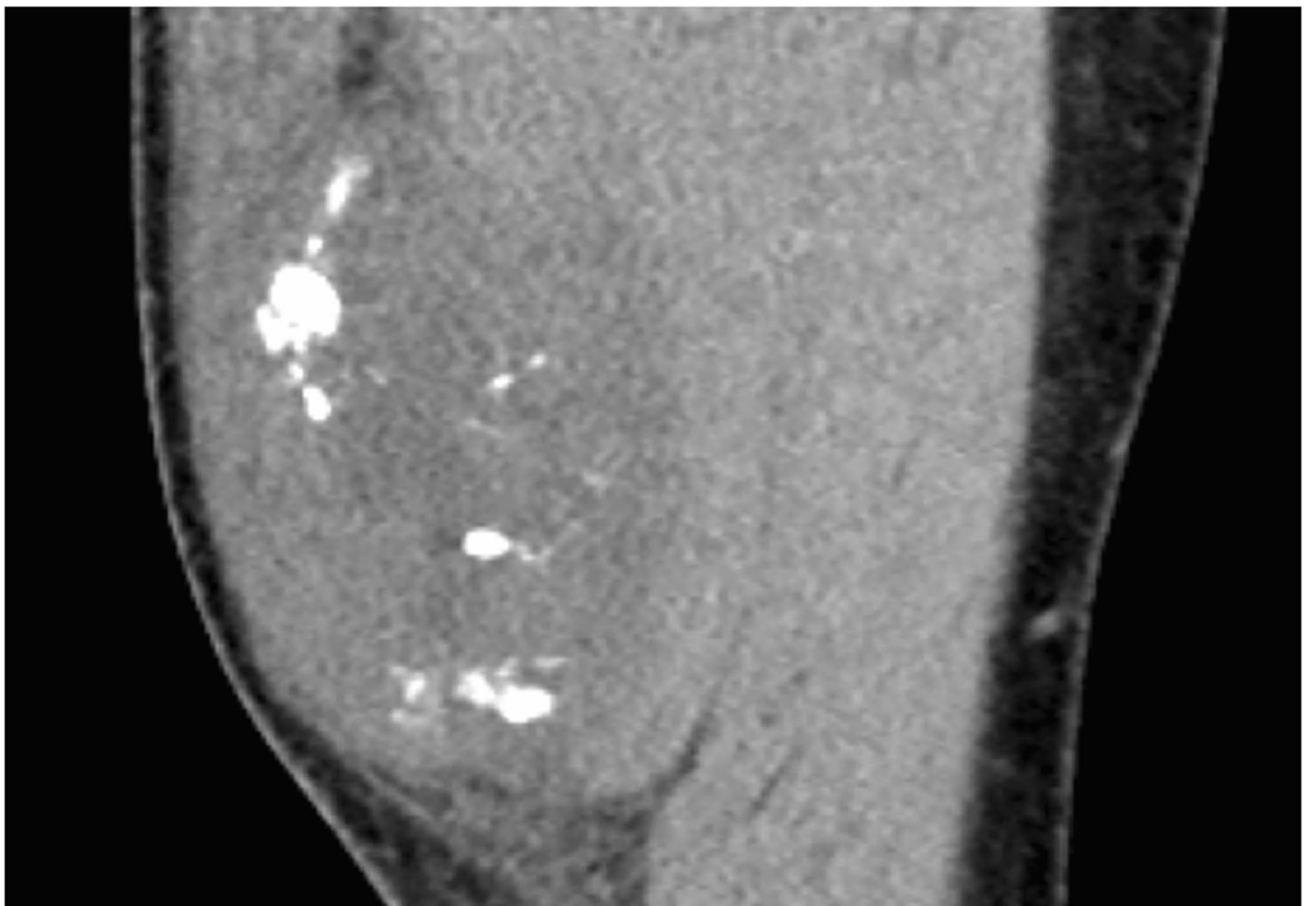


Fig. 3 Coronal CT MPR of the right thigh

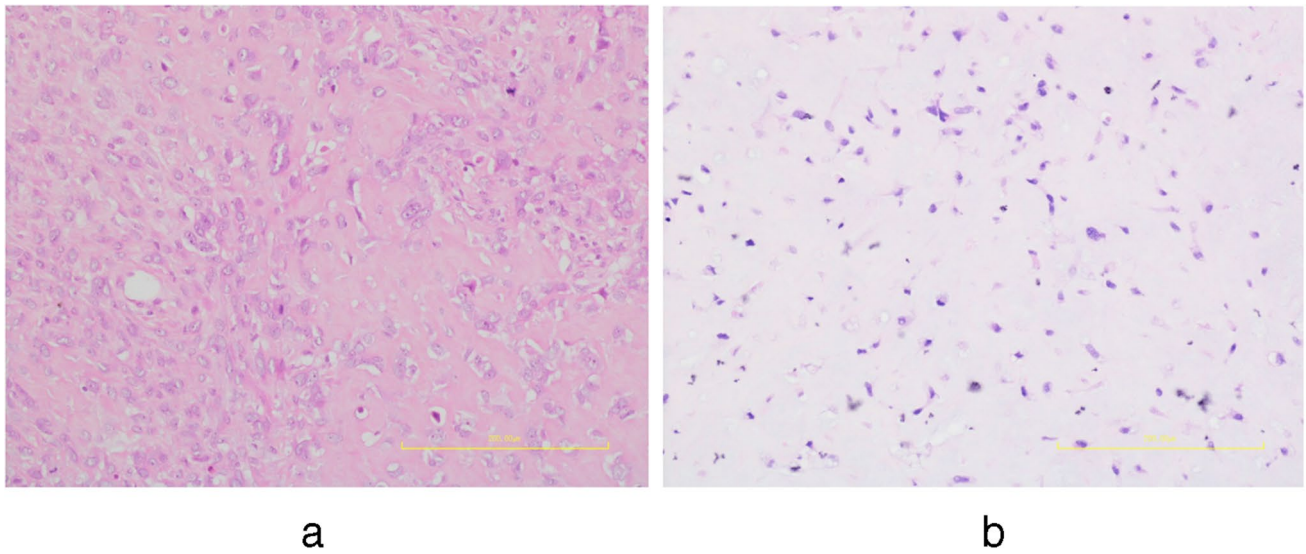


Fig. 4 Histology. H&E **a** $\times 20$ magnification and **b** $\times 210$ magnification

Declarations

Conflict of interest The authors declare no competing interests.

Publisher's note Springer Nature remains neutral with regard to jurisdictional claims in published maps and institutional affiliations.