



A 29-year-old male with a long history of atraumatic wrist pain

William Tilden¹ · Daniel Lindsay¹ · Emmanouil Astrinakis² · Maxim Horwitz² · Asif Saifuddin¹

Received: 27 November 2020 / Revised: 9 February 2021 / Accepted: 14 February 2021 / Published online: 26 February 2021
© ISS 2021

Test Yourself Question:

A 29-year-old male with a long history of atraumatic left wrist pain.

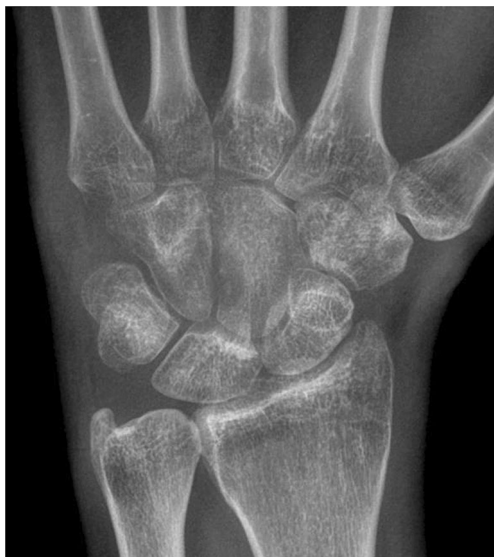

Fig. 1 Anteroposterior radiograph of the left wrist

The diagnosis can be found at <https://doi.org/10.1007/s00256-021-03743-6>

✉ William Tilden
wtilden5@gmail.com

¹ The Royal National Orthopaedic Hospital, Brockley Hill, Stanmore HA7 4LP, UK

² Chelsea and Westminster Hospital, London, UK

Fig. 2 **a** Coronal STIR, **b** sagittal STIR and **c** axial PDW FSE MR images of the left wrist

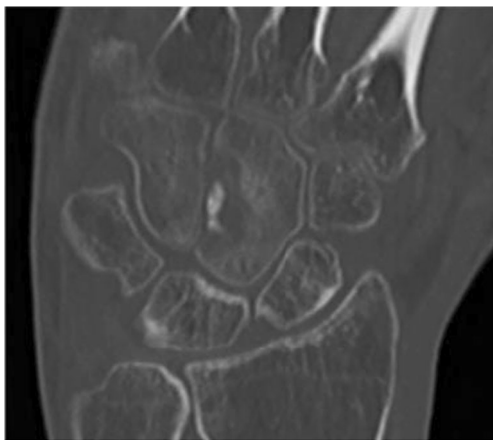
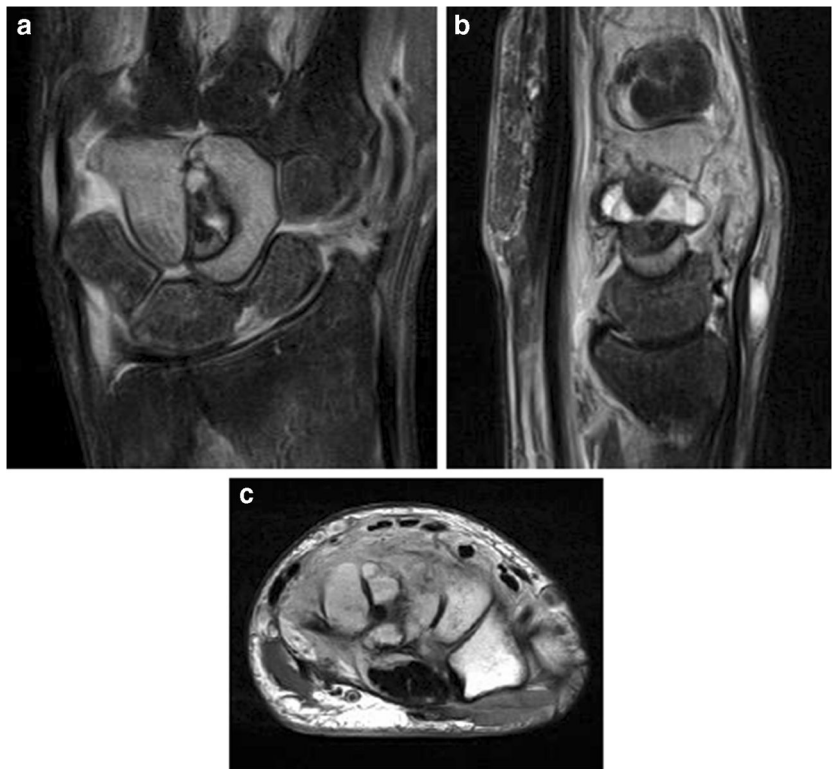

Fig. 3 Coronal CT MPR of the left wrist

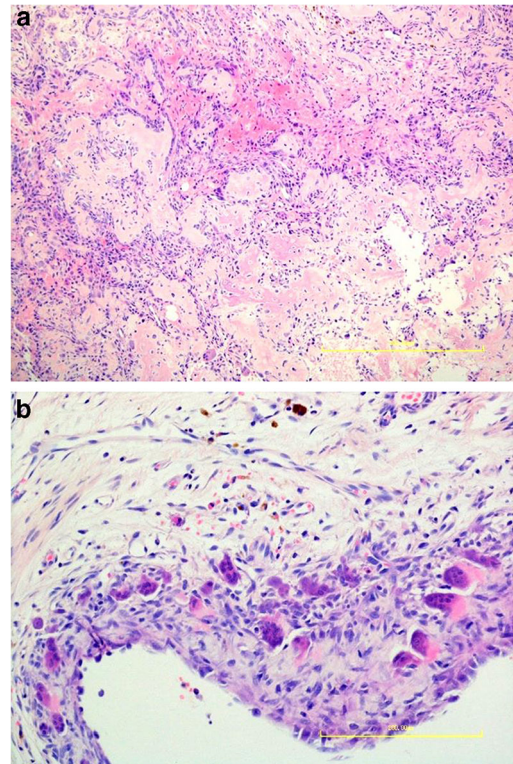


Fig. 4 H & E sections ($\times 10$ magnification)

Publisher's note Springer Nature remains neutral with regard to jurisdictional claims in published maps and institutional affiliations.