



## Test yourself question: right medial hip pain

E Smith<sup>1</sup> · R Rajakulasingam<sup>2</sup> · AM Davies<sup>1</sup> · SL James<sup>1</sup> · R Botchu<sup>1</sup>

Received: 23 October 2020 / Revised: 23 October 2020 / Accepted: 15 November 2020 / Published online: 24 November 2020  
© ISS 2020

### Question:

A 32-year-old male presented with right medial hip pain following an injury sustained doing martial arts.

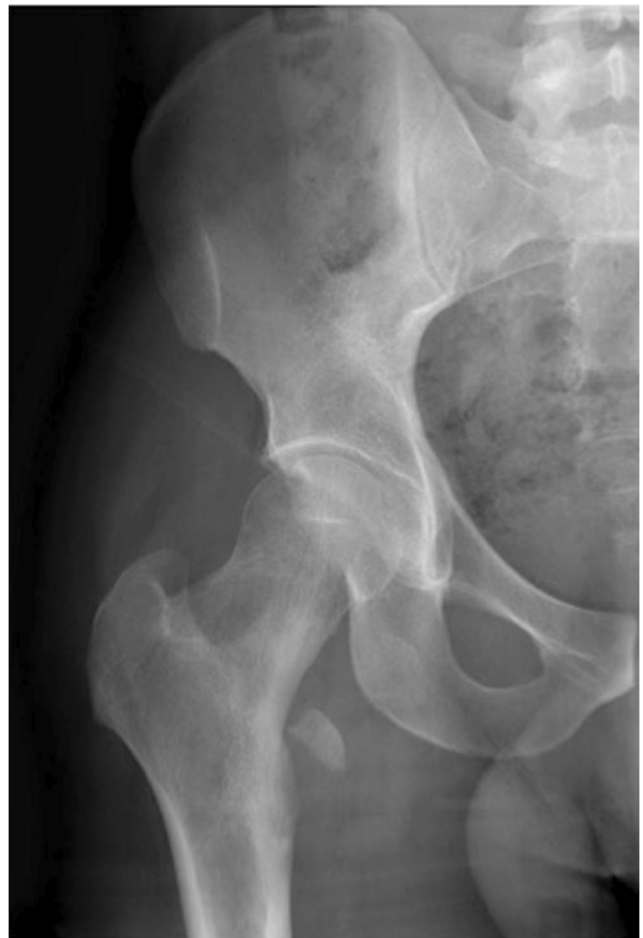

Fig. 1 AP (anteroposterior radiograph) of the right hip

---

The diagnosis can be found at doi: 10.1007/s00256-020-03679-3

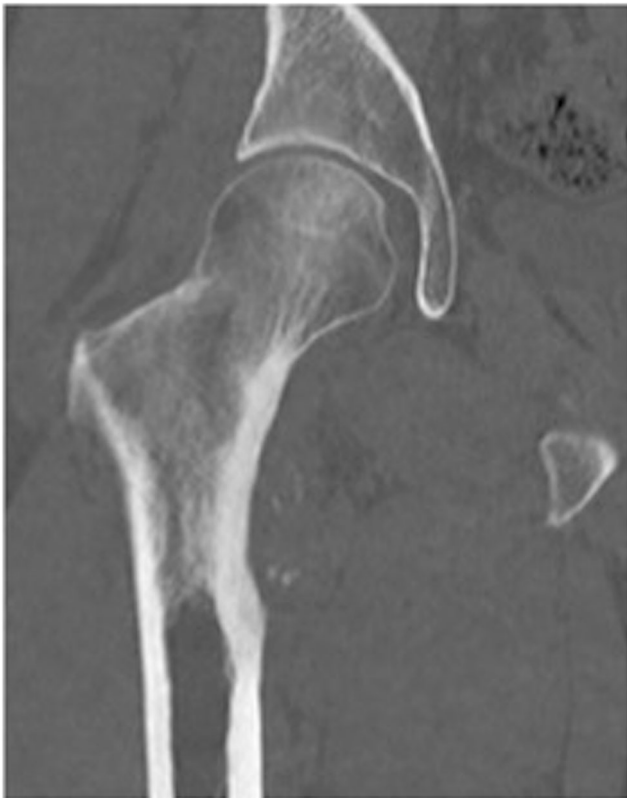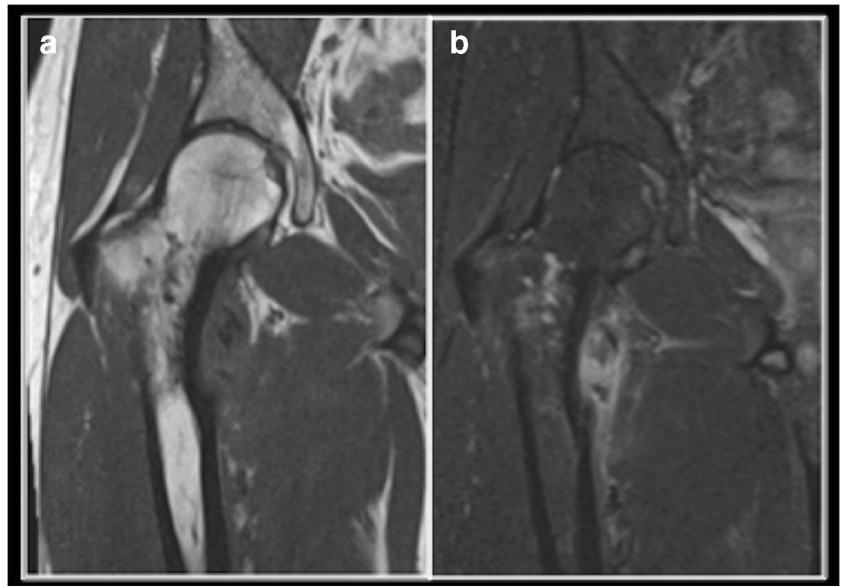
---

✉ R Botchu  
drbrajesh@yahoo.com

<sup>1</sup> Department of Musculoskeletal Imaging, Royal Orthopaedic Hospital, Birmingham, UK

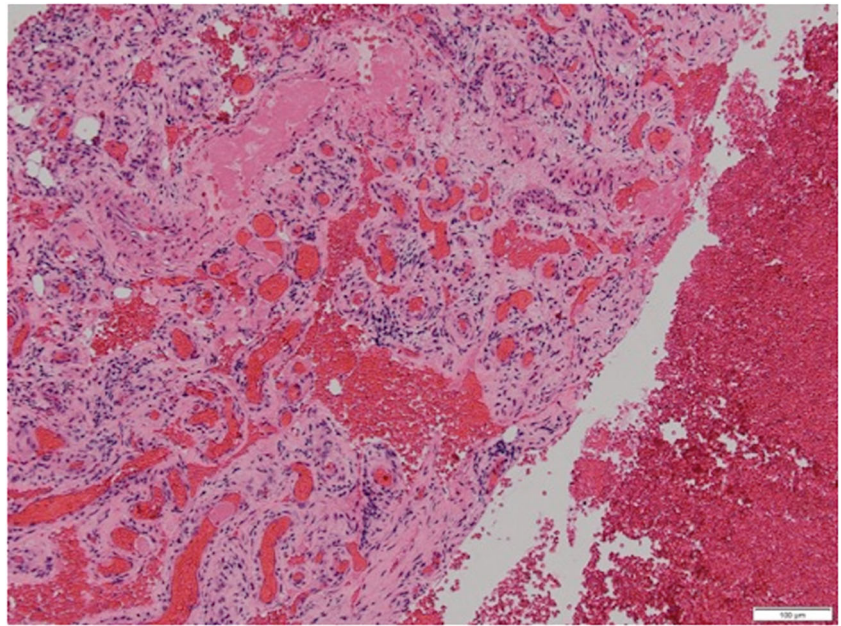
<sup>2</sup> Department of Musculoskeletal Imaging, Royal National Orthopaedic Hospital, Stanmore, UK

**Fig. 2** **a** Coronal T1W TSE and **b** coronal STIR MR images of the right hip



**Fig. 3** Coronal CT image of the right hip

**Fig. 4** Microphotograph (H&E × 20 magnification)



### Compliance with ethical standards

**Conflict of interest** The authors declare that they have no conflicts of interest.

**Publisher's note** Springer Nature remains neutral with regard to jurisdictional claims in published maps and institutional affiliations.