



Test yourself question: incidental left L5/S1 facet finding on MRI

R. Rajakulasingam¹ · D. Lindsay² · H. Anwar³ · A. Saifuddin¹ · T. Muthukumar¹

Received: 16 August 2020 / Revised: 27 September 2020 / Accepted: 30 September 2020 / Published online: 9 October 2020
© ISS 2020

Question

A 16-year-old boy with Scheuermann's kyphosis presented with an incidental finding at the left L5/S1 facet on MRI.

The diagnosis can be found at doi: 10.1007/s00256-020-03640-4

✉ R. Rajakulasingam
Ramanan.rajakulasingam1@nhs.net

D. Lindsay
daniel.lindsay1@nhs.net

H. Anwar
hanny.anwar@nhs.net

A. Saifuddin
Asif.saifuddin@nhs.net

T. Muthukumar
t.muthukumar@nhs.net

¹ Department of Radiology, Royal National Orthopaedic Hospital, Brockley Hill, Stanmore, Middlesex HA7 4LP, UK

² Department of Histopathology, Royal National Orthopaedic Hospital, Brockley Hill, Stanmore, Middlesex HA7 4LP, UK

³ Department of Orthopaedic surgery, Royal National Orthopaedic Hospital, Brockley Hill, Stanmore, Middlesex HA7 4LP, UK

Fig. 1 **a** Sagittal T1W TSE and **b** axial T2W FSE MR images of the lumbar spine

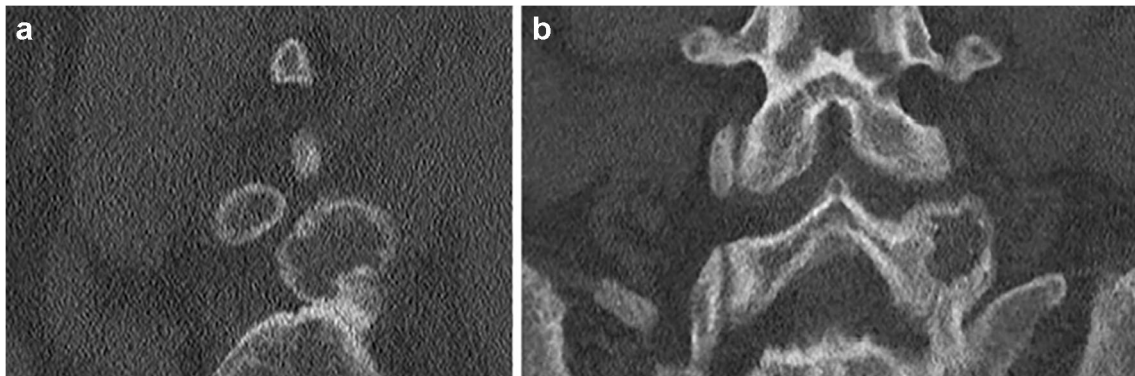
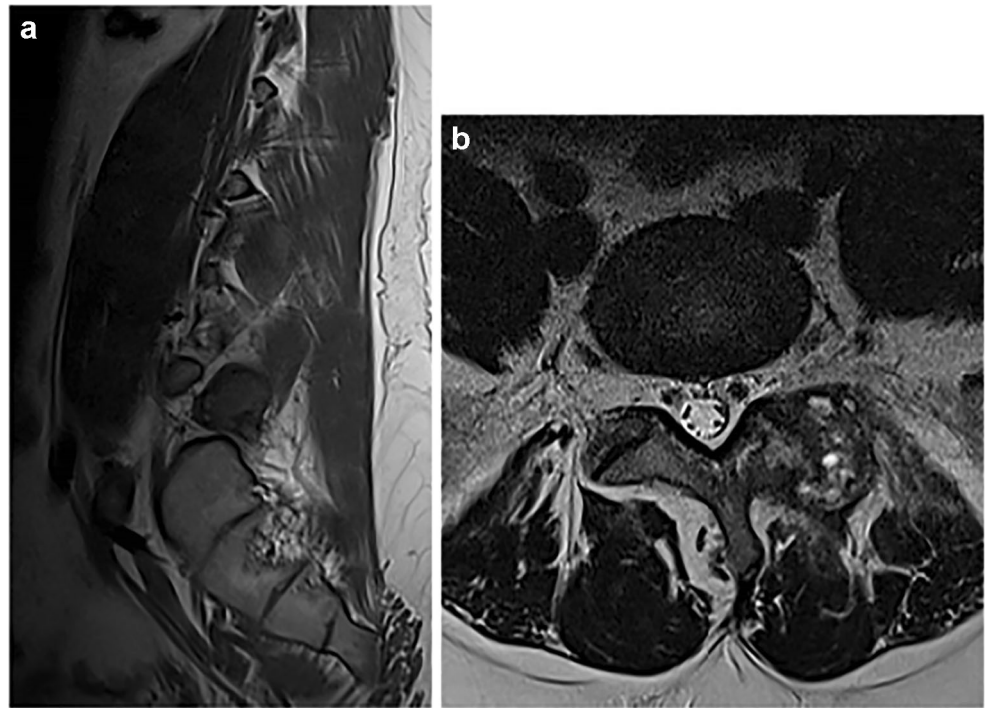


Fig. 2 **a** Sagittal and **b** coronal CT MPR images of the lower lumbar spine

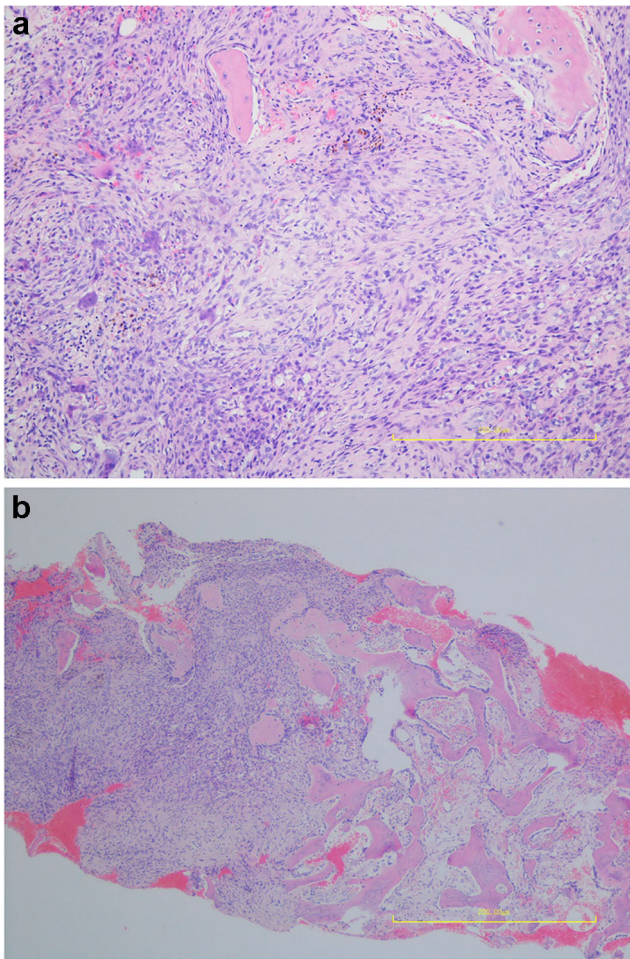


Fig. 3 Microphotographs **a** H&Ex10 and **b** H&Ex2

Compliance with ethical standards

Conflict of interest The authors declare that they have no conflicts of interest.

Publisher's note Springer Nature remains neutral with regard to jurisdictional claims in published maps and institutional affiliations.