



Test yourself: question—a 62-year-old lady with painful swelling of right hand index finger for the last 8 weeks

Sajid Butt¹ · Roberto Tirabosco² · Asif Saifuddin¹

Published online: 20 July 2020
© ISS 2020

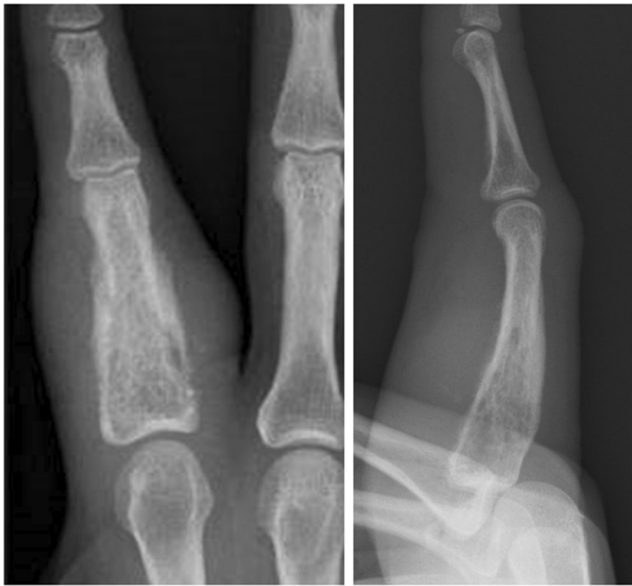

Fig. 1 AP and lateral radiographs of the right index finger

The diagnosis can be found at doi: <https://doi.org/10.1007/s00256-020-03553-2>

✉ Sajid Butt
Sajid.Butt@nhs.net

¹ Department of Radiology, Royal National Orthopaedic Hospital, Stanmore, UK

² Department of Histopathology, Royal National Orthopaedic Hospital, Stanmore, UK

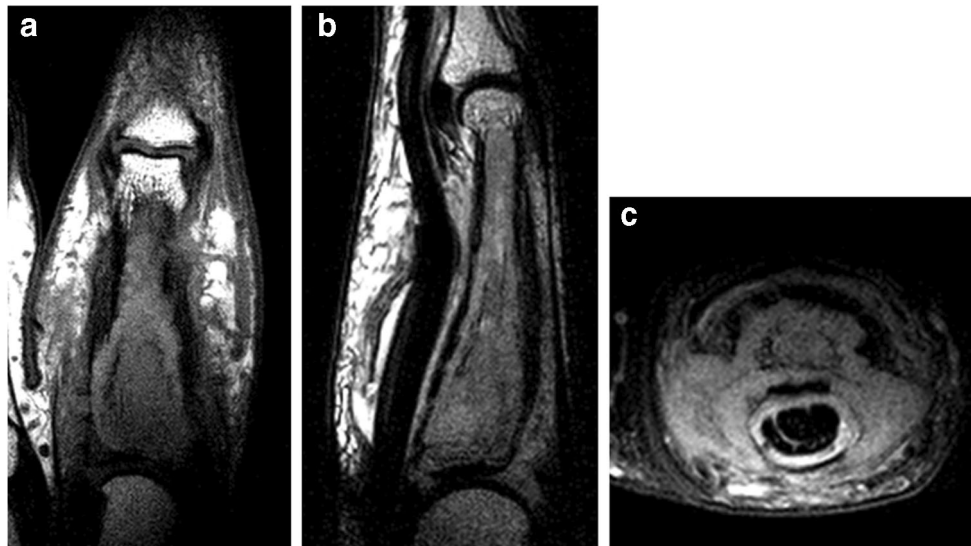


Fig. 2 (a) Coronal T1W TSE, (b) sagittal STIR, and (c) axial SPAIR MR images

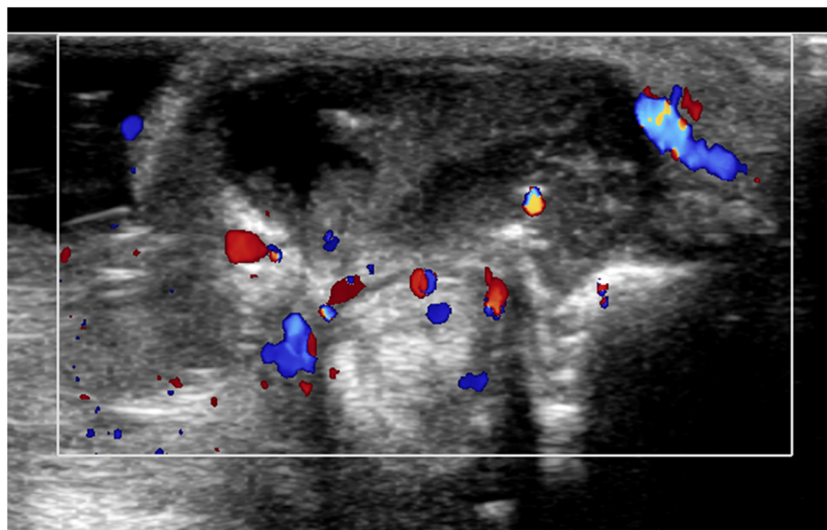


Fig. 3 Axial Doppler US image

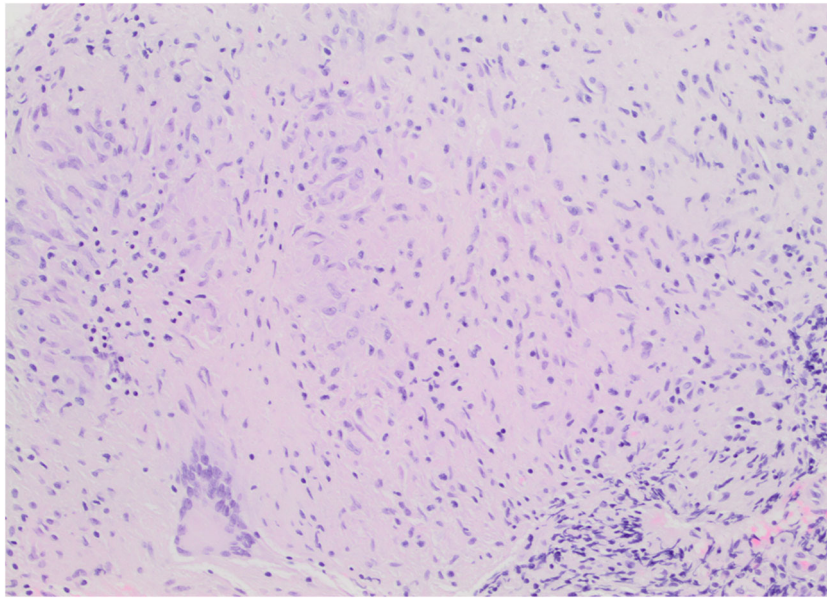


Fig. 4 Photomicrograph of H and E stain of biopsy specimen. ($\times 10$)

Publisher's note Springer Nature remains neutral with regard to jurisdictional claims in published maps and institutional affiliations.