



Bilateral round lucent iliac defects

Hieu Diep¹ · Christopher Wasyliw¹ · Andrew Cibulas¹ · Laura Bancroft¹

Published online: 20 July 2020
© ISS 2020

Test Yourself: Question

Bilateral Round Lucent Iliac Defects

Thirty-nine year old female with a history of Athrogyroposis Mutiplex Congenta, chronic bilateral hip dislocation, right hip arthroplasty and recent trauma. AP Pelvis radiograph (Fig. 1) and non-contrast CT of the Pelvis (Fig. 2) were performed to evaluate for fracture.

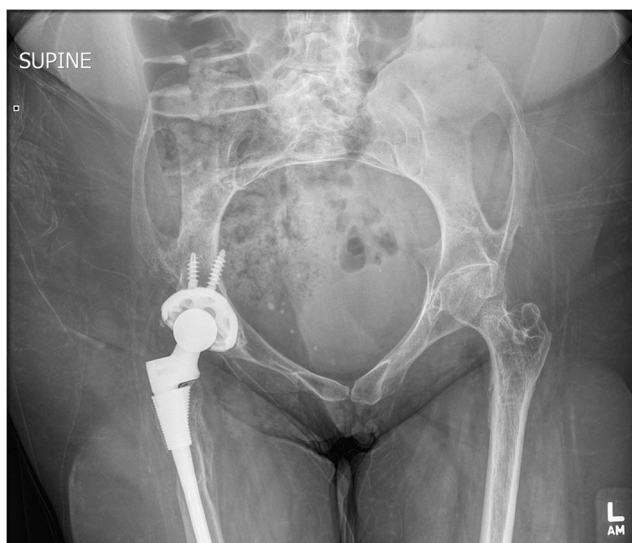

Fig. 1 AP radiograph of the pelvis

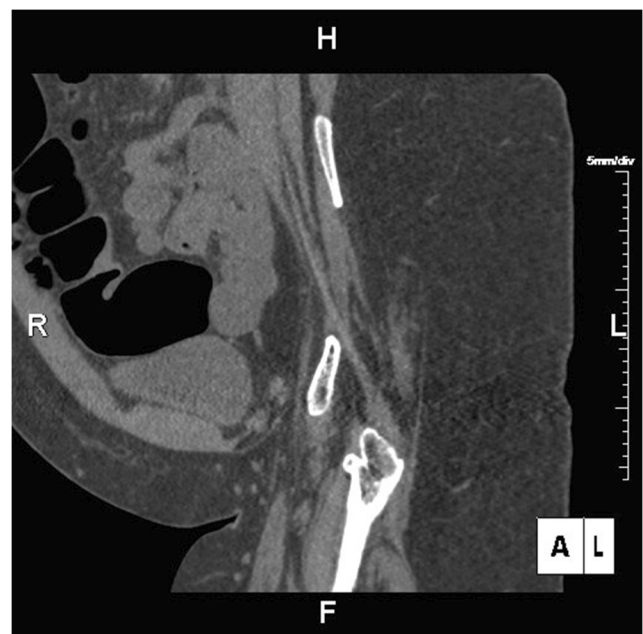


Fig. 2 Sagittal oblique reformatted image from the non-contrast CT of the pelvis

The diagnosis can be found at doi:10.1007/s00256-020-03500-1

✉ Hieu Diep
hieu.diep.md@adventhealth.com

¹ Advent Health, 601 E Rollins St, Orlando, FL 32803, USA