



Test yourself: question and answer question: painful knee swelling

Akarshan Monga¹ · Andrew Rosenberg² · Frank O’Dea³ · John Durham⁴ · Ty K. Subhawong⁵ 

Published online: 5 July 2019
© ISS 2019

Question: Painful Knee Swelling.

19 year old female with right knee pain for 7 years and increased knee swelling for 6 months (Figs. 1, 2, 3, 4, and 5).

The diagnosis can be found at <https://doi.org/10.1007/s00256-019-03274-1>

✉ Ty K. Subhawong
tsubhawong@miami.edu

- ¹ Nova Southeastern University- College of Osteopathic Medicine, Davie, FL, USA
- ² Department of Pathology, University of Miami Miller School of Medicine, 1400 NW 12th Avenue, Miami, FL 33136, USA
- ³ Health Sciences Centre, Memorial University of Newfoundland, 300 Prince Philip Drive, St. John’s, NL A1B 3V6, Canada
- ⁴ Northern Arizona Orthopaedics, 1485 N. Turquoise Drive, Flagstaff, AZ 86001, USA
- ⁵ Department of Radiology, University of Miami Miller School of Medicine/Jackson Memorial Hospital, 1611 NW 12th Ave., JMH WW 279, Miami, FL 33136, USA

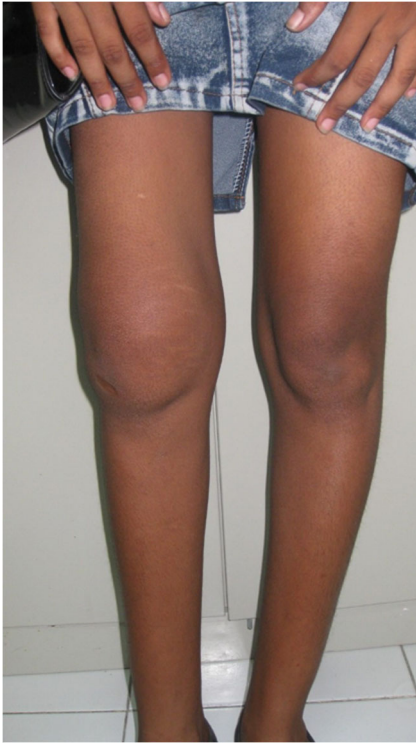

Fig. 1 Clinical photograph of both knees showing marked swelling of the right knee

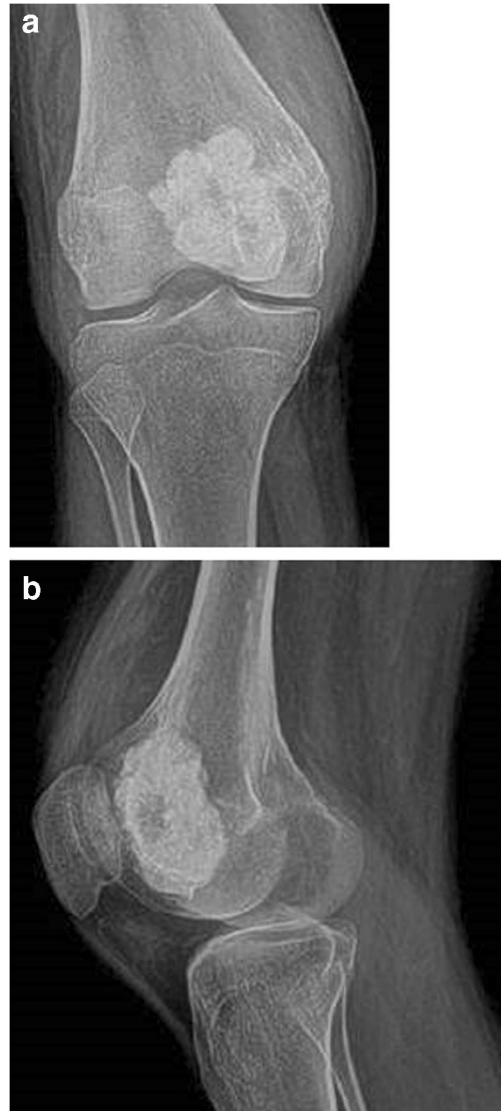

Fig. 2 **a** AP and **b** Lateral radiographs of the right knee

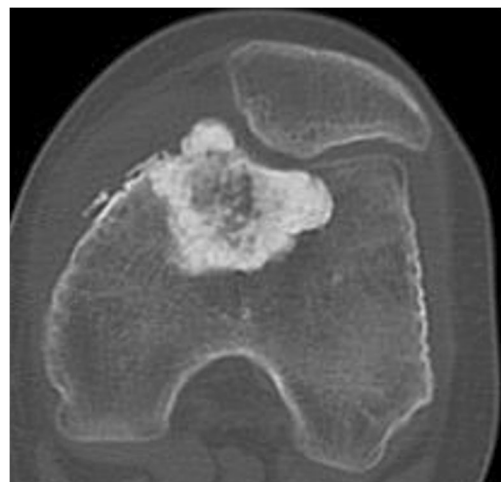


Fig. 3 Axial CT

Fig. 4 Hematoxylin and eosin staining of the curetted specimen from surgical biopsy

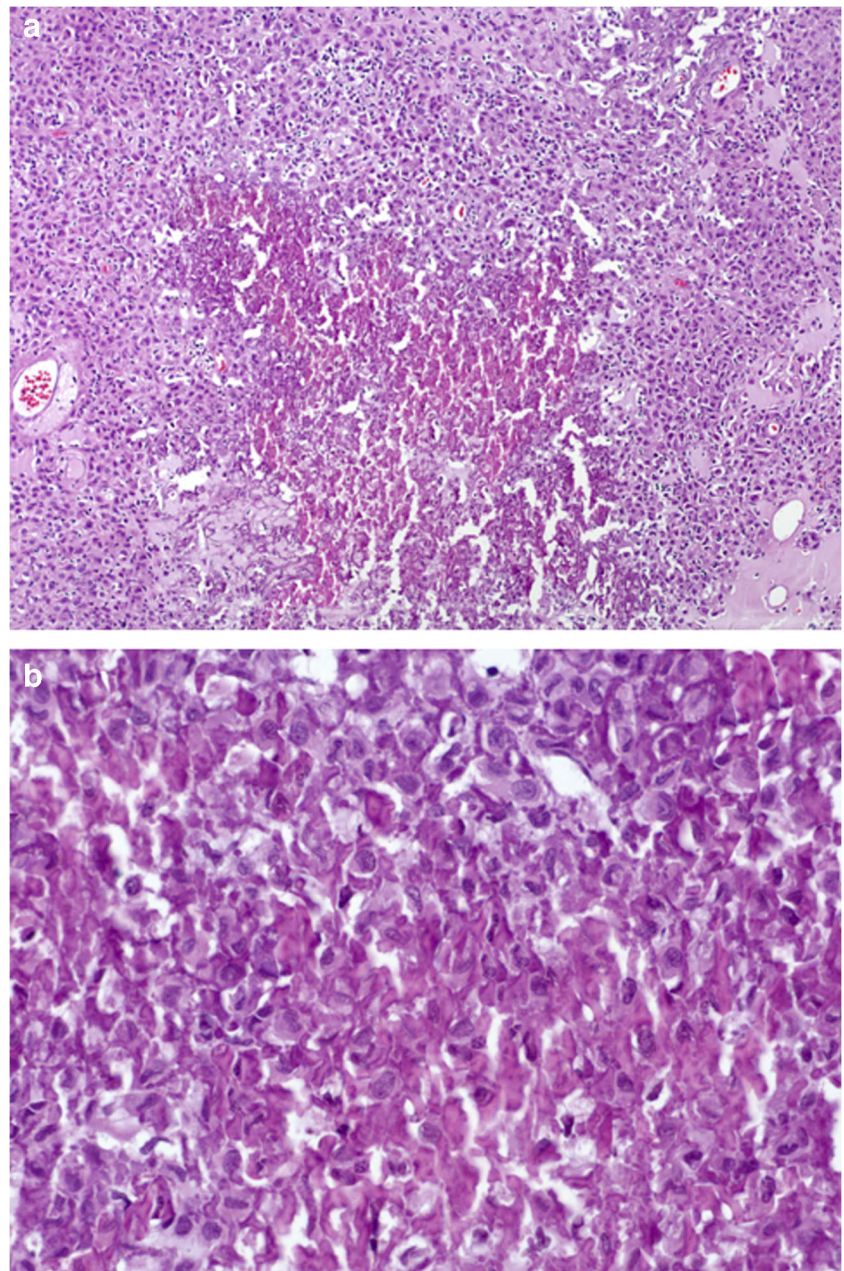

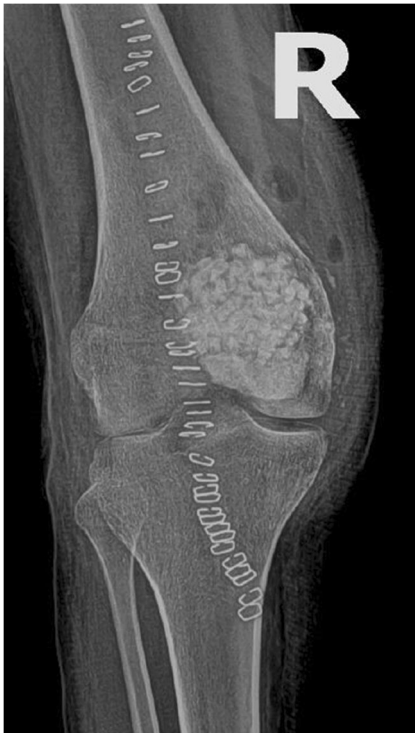


Fig. 5 AP radiograph of the right knee immediately post curetting and packing with bone graft substitute

Compliance with ethical standards

Conflict of interest The authors declare that they have no conflict of interest.

Publisher's note Springer Nature remains neutral with regard to jurisdictional claims in published maps and institutional affiliations.