


## Test yourself: painless hand mass

Sarah Fenerty<sup>1</sup>  · Stephen Ling<sup>1</sup> · Congli Wang<sup>2</sup> · Omer Awan<sup>1</sup> · Sayed Ali<sup>1</sup>

Published online: 29 November 2016  
© ISS 2016

**HISTORY:** A 34 year-old man presented to his primary care physician with a painless mass along the dorsum of the second metacarpal neck of 8–9 months duration. There was no history of trauma. (Figs. 1, 2 and 3)

---

The diagnosis can be found at doi: [10.1007/s00256-016-2544-y](https://doi.org/10.1007/s00256-016-2544-y)

---

✉ Sarah Fenerty  
sarah.fenerty@tuhs.temple.edu

Stephen Ling  
stephen.ling@tuhs.temple.edu

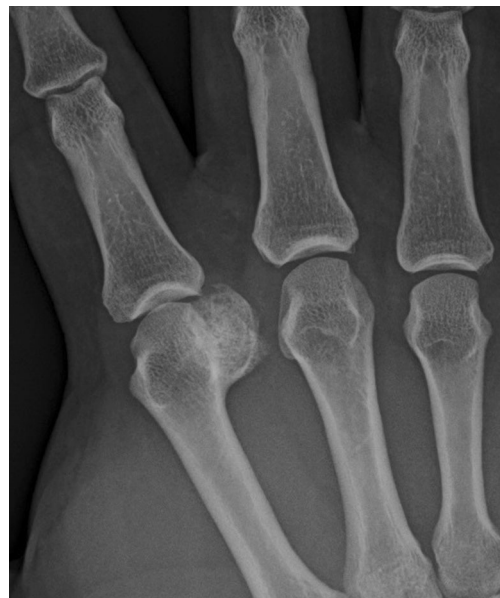Congli Wang  
congli.wang@tuhs.temple.edu

Omer Awan  
omer.awan@tuhs.temple.edu

Sayed Ali  
alisayan@tuhs.temple.edu

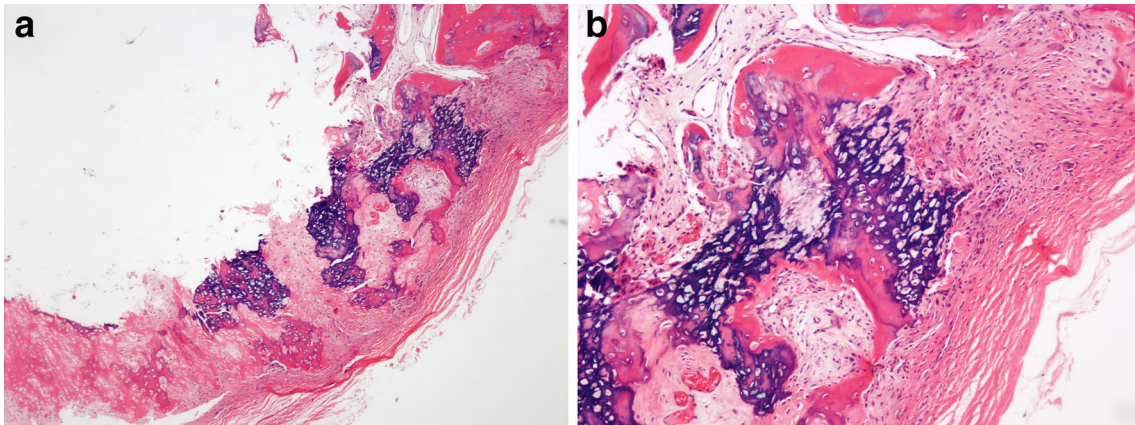
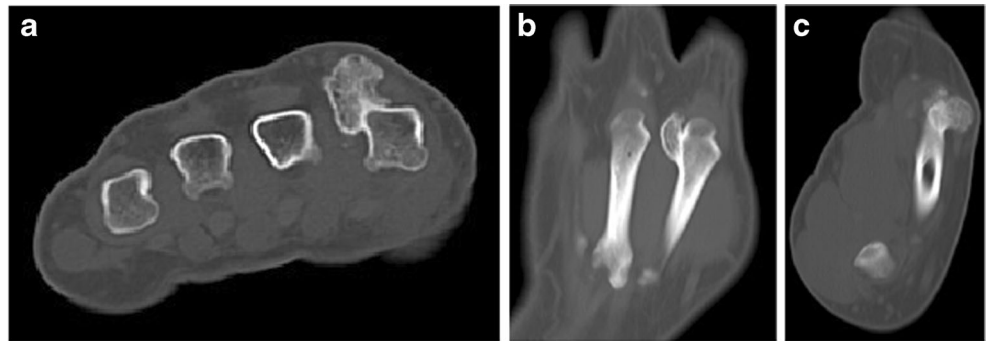
<sup>1</sup> Department of Radiology, Temple University Hospital, 3401 North Broad St., Philadelphia, PA 19140, USA

<sup>2</sup> Department of Pathology, Temple University Hospital, 3401 North Broad St., Philadelphia, PA 19140, USA



**Fig. 1** AP radiograph of the right 2nd-4th metacarpals and proximal phalanges

**Fig. 2** Axial (a), coronal (b), and sagittal (c) noncontrast CT of the right hand at bone windows



**Fig. 3** Histopathological photomicrographs (hematoxylin and eosin staining) at (a) 40x power and (b) 100x power

**Compliance with ethical standards**

**Funding information** No funding was received for this article.