

## Newborn with rhizomelia and difficulty breathing

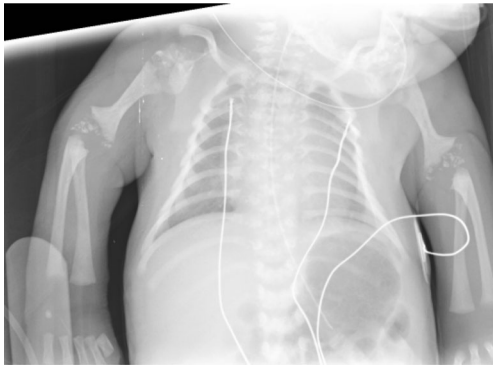
Evelina Maines<sup>1</sup> · Laura Baggio<sup>2</sup> · Giorgia Gugelmo<sup>1</sup> · Grazia Morandi<sup>2</sup> · Andrea Bordugo<sup>1</sup>

Published online: 25 November 2016  
© ISS 2016

### Question:

Full-term female neonate with rhizomelia and respiratory distress at birth. We performed a chest x-ray (Fig. 1) before

starting non-invasive ventilation and the diagnosis was immediately suspected. An x-ray of the entire skeleton reinforced the diagnostic suspicion (Fig. 2).



**Fig. 1** AP chest radiograph

The diagnosis can be found at doi:[10.1007/s00256-016-2537-x](https://doi.org/10.1007/s00256-016-2537-x)

✉ Evelina Maines  
evelina.maines@gmail.com

Laura Baggio  
baggio.laura7@gmail.com

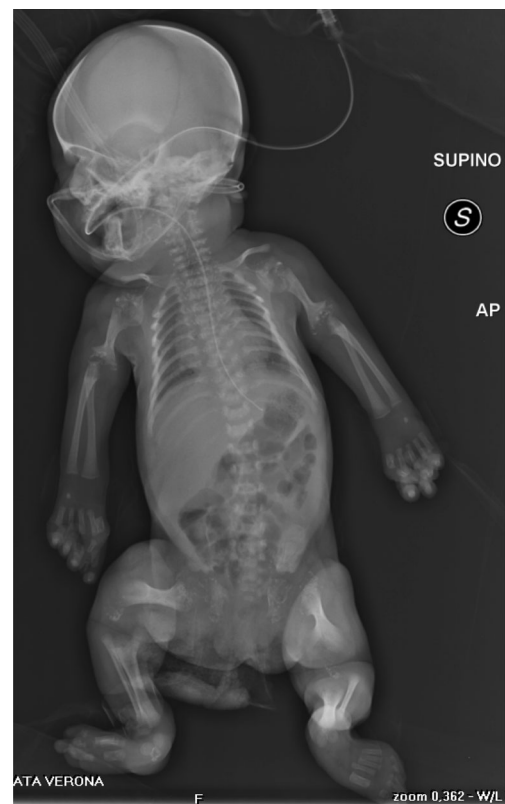Giorgia Gugelmo  
gugelmogiorgia@gmail.com

Grazia Morandi  
grazia.morandi@gmail.com

Andrea Bordugo  
andrea.bordugo@ospedaleuniverona.it

<sup>1</sup> Department of Pediatrics, Regional Centre for Newborn Screening, Diagnosis and Treatment of Inherited Metabolic Diseases and Congenital Endocrine Diseases, Azienda Ospedaliera Universitaria Integrata of Verona, Piazzale Ludovico Antonio Scuro, 10, 37134 Verona, Italy

<sup>2</sup> Pediatric Clinic, Department of Life and Reproduction Sciences, University of Verona, Verona, Italy



**Fig. 2** AP radiograph of the entire skeleton