

Test yourself: inability to squat

Hatice Tuba Sanal¹

Published online: 27 October 2016
© ISS 2016

QUESTION-Male patient in his twenties, referred to MRI with an asymmetry in his right buttock and difficulty in squatting (Figs 1, 2, 3, and 4).

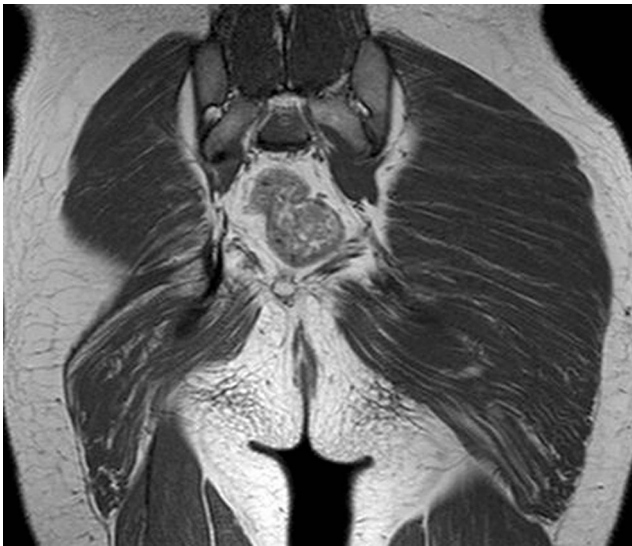

Fig. 1 Coronal T1-weighted image

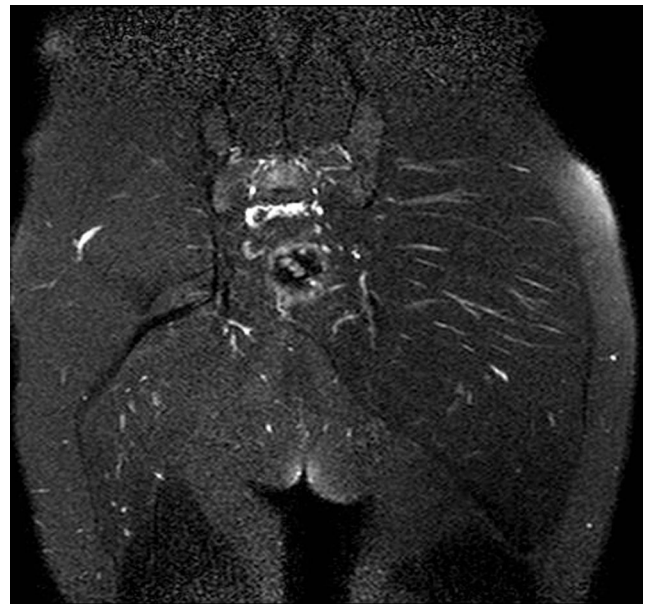

Fig. 2 Coronal fat saturated T2-weighted image

The diagnosis can be found at doi: [10.1007/s00256-016-2519-z](https://doi.org/10.1007/s00256-016-2519-z)

✉ Hatice Tuba Sanal
tubasanal@gmail.com

¹ Department of Radiology, Gulhane School of Medicine, Health Sciences University, Gn.Tevfik Saglam Cad., 06018 Kecioren, Ankara, Turkey

Fig. 3 Axial T1-weighted image

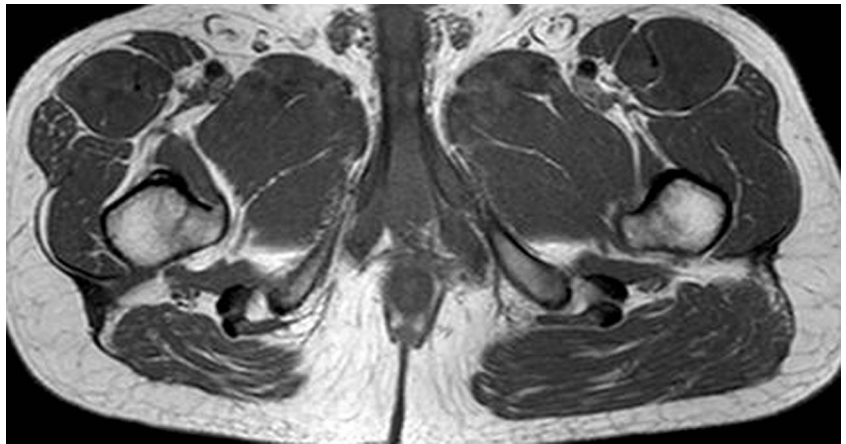


Fig. 4 Axial T1-weighted image

