

Painful ankle swelling

Annu Chopra · Andrew J. Grainger ·
Emma L. Rowbotham

Published online: 2 December 2014
© ISS 2014

Question

A normally fit and well 33 year old elite athlete, with acute onset of pain and swelling around the region of the Achilles tendon whilst running, was referred for an MRI by his physiotherapist (See Figs. 1 and 2).

The diagnosis can be found at doi: 10.1007/s00256-014-2073-5

A. Chopra (✉)
Sheffield Teaching Hospitals NHS Foundation Trust, Northern
General Hospital, Herries Road, Sheffield S5 7AU, UK
e-mail: Annu.chopra@sth.nhs.uk

A. J. Grainger · E. L. Rowbotham
Leeds Teaching Hospitals NHS Foundation Trust, Chapel Allerton
Hospital, Leeds LS7 4SA, UK

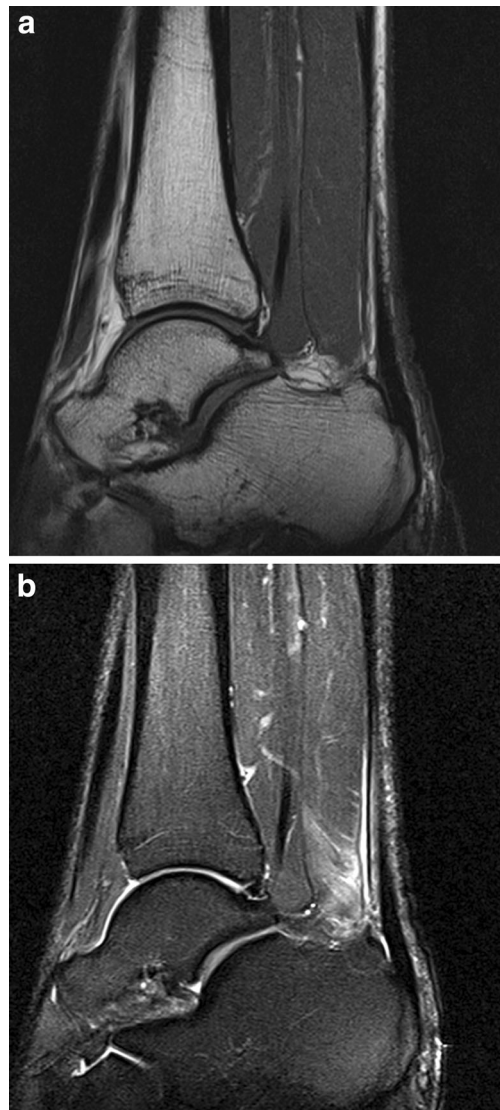


Fig. 1 a. T1 Sagittal right ankle. b. T2 Fat sat sagittal right ankle

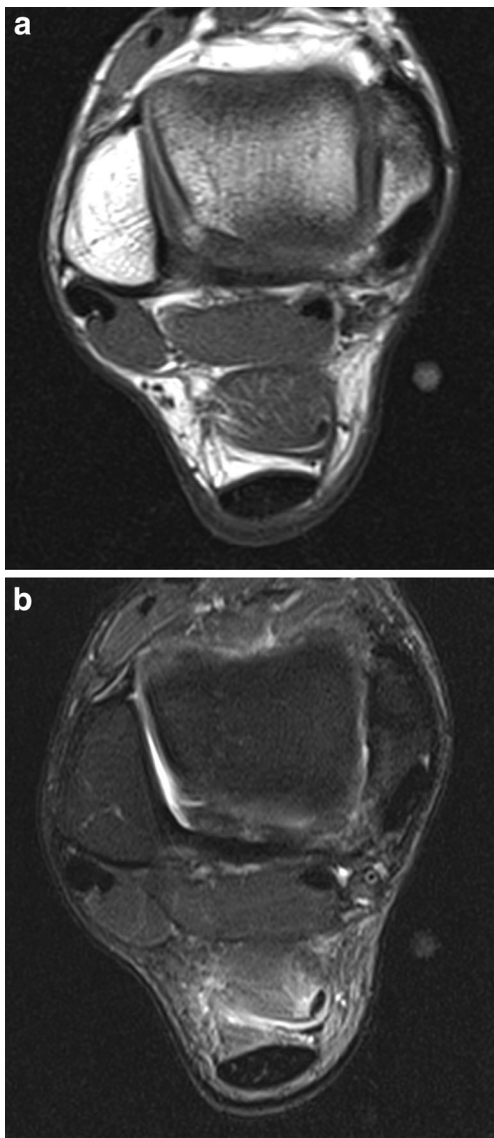


Fig. 2 a. T1 Axial right ankle. b. T2 Fat sat axial right ankle