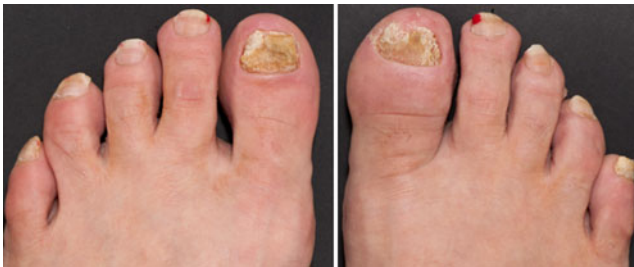

## Psoriatic onycho pachydermo periostitis (POPP)

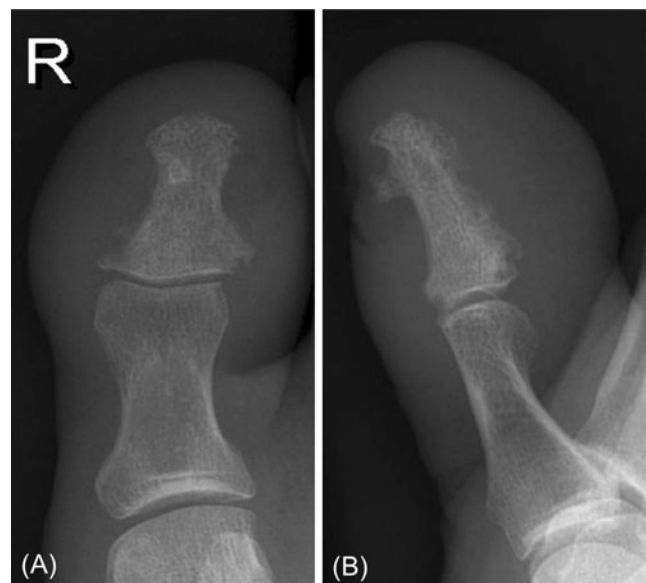Sarath Bethapudi · Jill Halstead · Zoe Ash ·  
Dennis McGonagle · Andrew J. Grainger

Published online: 11 July 2013  
© European Union 2013

A 55-year-old female patient with a history of palmoplantar pustular psoriasis presented with a 12-month history of nail dystrophy that was followed by swelling and erythema of the right great toe for 6 months. She was otherwise well with normal baseline blood tests and chest X-ray. No improvement was evident with multiple courses of antibiotics.



**Fig. 1** Photographs of the right and left toes



**Fig. 2** Radiographs. **a** Frontal and **b** lateral

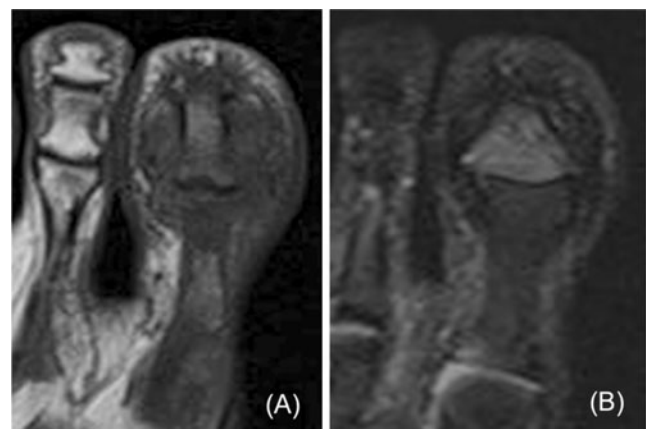
The diagnosis can be found at doi: 10.1007/s00256-013-1682-8

S. Bethapudi · A. J. Grainger  
Department of MSK Radiology,  
Leeds Teaching Hospitals, Leeds, UK

J. Halstead · Z. Ash · D. McGonagle · A. J. Grainger  
NIHR Leeds Musculoskeletal Biomedical Research Unit,  
Leeds Teaching Hospitals, Leeds, UK

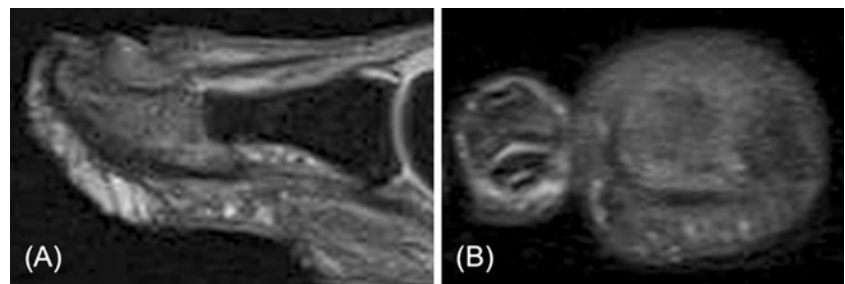
J. Halstead · Z. Ash · D. McGonagle  
Leeds Institute of Rheumatic and Musculoskeletal Medicine,  
University of Leeds, Leeds, UK

S. Bethapudi (✉)  
Leeds Teaching Hospitals NHS Trust, Chapel Allerton Hospital,  
Chapelton Road, Leeds LS7 4SA, West Yorkshire, UK  
e-mail: bethapudi@gmail.com



**Fig. 3** **a** Coronal T1W and **b** coronal T2W fat-suppressed MRI

**Fig. 4** **a** Sagittal and **b** axial proton density MRI



Photographs of both left and right toes are shown in Fig. 1. As part of the diagnostic evaluation she had radiographs (Fig. 2) and a subsequent MRI scan (Figs. 3, 4).

**Disclosures** Dr Andrew Grainger, Prof Dennis McGonagle and Dr Zoe Ash receive funding from the National Institute of Health Research, Leeds Musculoskeletal Biomedical Research Unit. Jill Halstead receives funding from Arthritis Research, UK.