

Bumps over cheeks

Hatice Tuba Sanal · Kemal Hasanov · Nebi Caferov · Lina Chen

Published online: 26 June 2013
© ISS 2013

Question

Twenty one year old draftee under evaluation of medical qualification. A panoramic radiograph (Fig. 1) and CT scan of his skull (Fig. 2) was performed.

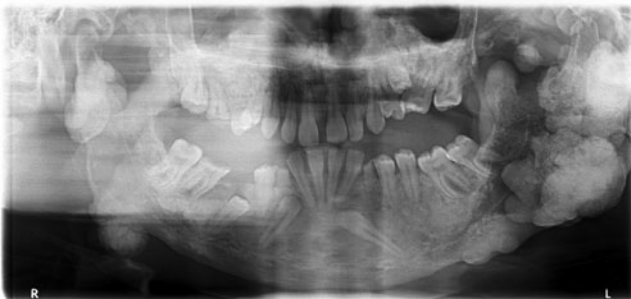

Fig. 1 Panoramic radiograph

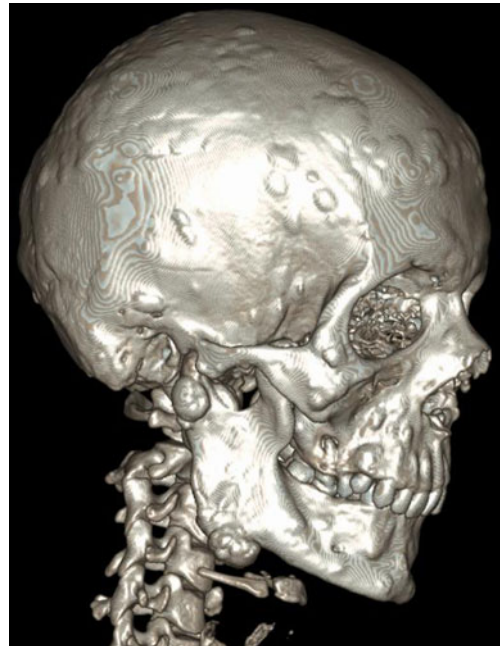


Fig. 2 3D surface shaded image of skull

Conflict of interest The authors declare that they have no conflict of interest.

The diagnosis can be found at doi: [10.1007/s00256-013-1679-3](https://doi.org/10.1007/s00256-013-1679-3).

H. T. Sanal (✉) · K. Hasanov · N. Caferov
Department of Radiology, Gulhane Military Medical Academy,
Medical Faculty, 06018 Kecioren, Ankara, Turkey
e-mail: tubasanal@gmail.com

L. Chen
University of Maryland School of Medicine, 22 South Greene
Street, Baltimore, MD 21201, USA