

Lateral heel pain

Diphile Iradukunda · Kelly Chu · Haron Obaid

Published online: 23 March 2013
© ISS 2013

History

A 53-year-old female presented to the emergency room with a few-weeks' duration of pain and swelling of the lateral aspect of the right foot. She had no history of trauma or recent infections.

Below are the images. Figure 1 Coronal plane; Fig. 2 Sagittal plane; Fig. 3 Axial plane

What is the diagnosis?

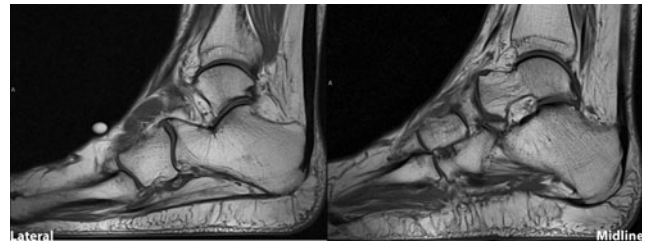

Fig. 2 Sagittal right foot view

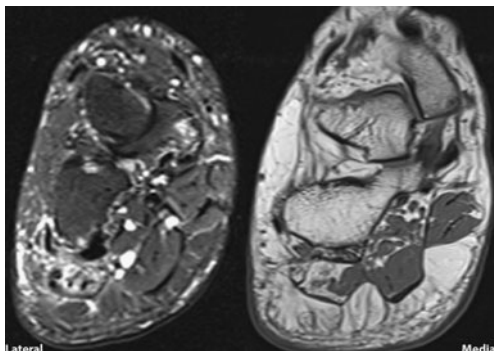


Fig. 1 Coronal and coronal STIR right foot view

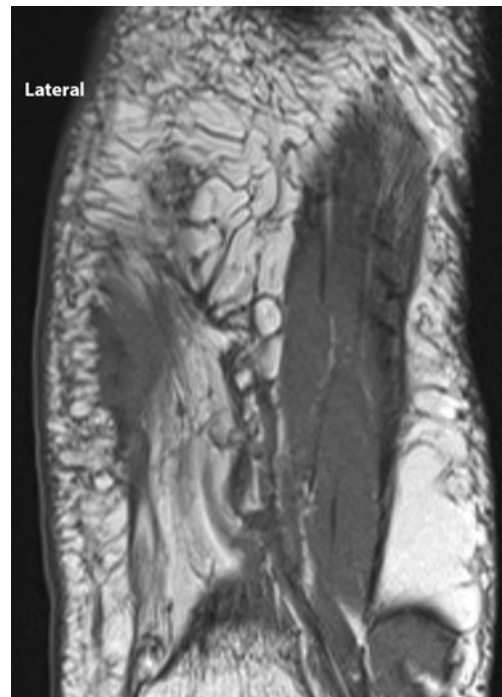


Fig. 3 Axial right foot view

The diagnosis can be found at doi: 10.1007/s00256-013-1599-2

D. Iradukunda (✉)
Department of Radiology, University of Saskatchewan, 241
Thomson Avenue, Regina, SK, Canada S4N 5P9
e-mail: dii367@mail.usask.ca

K. Chu · H. Obaid
Department of Radiology, Royal University Hospital,
103 Hospital Drive, Saskatoon, SK S7N 0W8, Canada

Conflicts of interest None.