

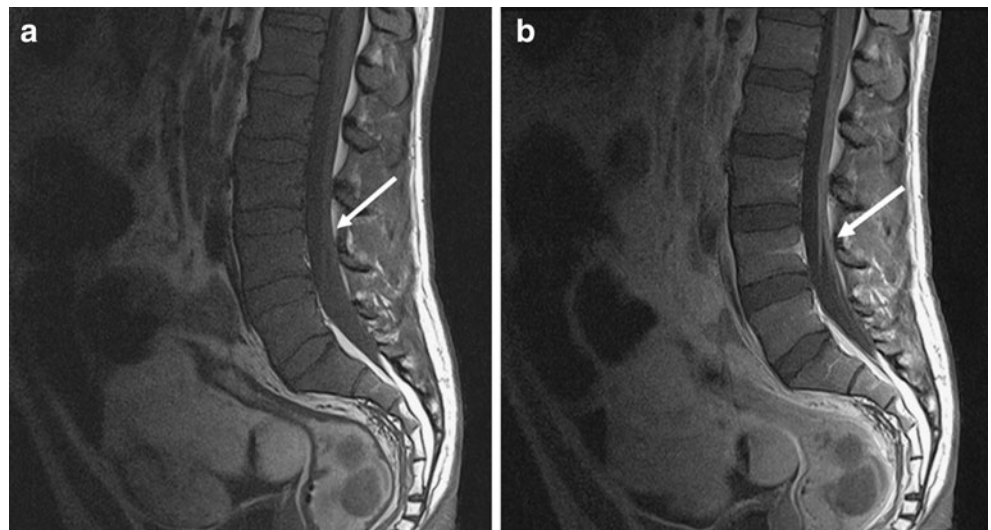
Weakness after foreign travel in a 40-year-old man

Gabrielle C. Colleran · Martin J. Shelly ·
Michael R. Moynagh · Eoin C. Kavanagh

Published online: 2 March 2010
© ISS 2010

A 40-year-old man presented with increasing lethargy, malaise, fever and sweating, which were associated with tingling and altered sensation beginning in his distal extremities, toes and fingers, before spreading proximally, ultimately resulting in an inability to bear weight. These symptoms followed a mild flu-like illness and recent foreign travel (Fig. 1).

Fig. 1 **a** Sagittal T1-weighted MRI of the lumbar spine. The *arrow* points to the lumbar nerve roots. **b** T1-weighted MRI of the lumbar spine following administration of gadolinium



The diagnosis can be found at doi:10.1007/s00256-010-0906-4

G. C. Colleran (✉) · M. J. Shelly · M. R. Moynagh · E. C. Kavanagh
Department of Radiology, Mater Misericordiae University
Hospital,
Eccles Street,
Dublin 7, Ireland
e-mail: collerangabrielle@hotmail.com