

An asymptomatic young woman with abnormal manubrium sterni

Dae Hee Han · Myeong Im Ahn · Jung Im Jung ·
Seog Hee Park

Published online: 30 July 2009
© ISS 2009

History

A 23-year-old woman recently diagnosed with non-Hodgkin lymphoma underwent computed tomography (CT) of the chest as part of the initial staging work-up (Fig. 1).

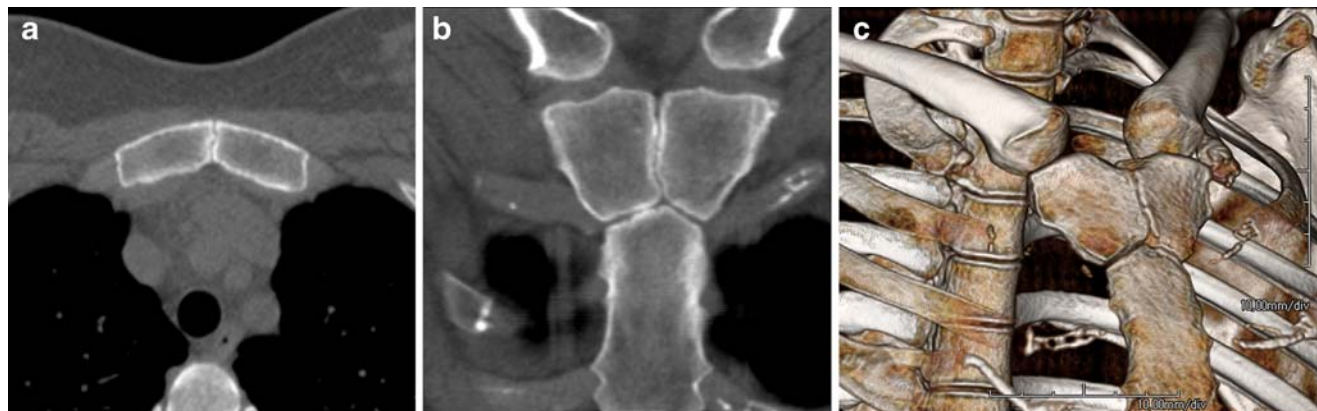


Fig. 1 **a** Axial CT scan through the manubrium; **b** oblique coronal CT reconstruction; **c** volume-rendering CT image with right anterior oblique projection

The diagnosis can be found at doi: 10.1007/s00256-009-0753-3.

D. H. Han · M. I. Ahn (✉) · J. I. Jung · S. H. Park
Department of Radiology, Seoul St. Mary's Hospital,
College of Medicine, The Catholic University of Korea,
505 Banpo-dong, Seocho-gu,
Seoul 137-701, Korea
e-mail: ami@catholic.ac.kr

D. H. Han
e-mail: lepolder@gmail.com

J. I. Jung
e-mail: jijung@catholic.ac.kr

S. H. Park
e-mail: parksh@catholic.ac.kr