

Roxanne Chan
David H. Kim
Peter J. Millett
Barbara N. Weissman

Calcifying tendinitis of the rotator cuff with cortical bone erosion

Published online: 7 December 2004
© ISS 2004

The online version of the original article can be found at <http://dx.doi.org/10.1007/s00256-004-0770-1>

R. Chan · D. H. Kim · P. J. Millett · B. N. Weissman
Brigham and Women's Hospital,
Harvard Medical School,
Boston, Massachusetts, USA

B. N. Weissman (✉)
Department of Radiology, Musculoskeletal Division,
Brigham and Women's Hospital,
75 Francis Street, Boston, MA 02115, USA
e-mail: BWeissman@Partners.org
Tel.: +1-617-7326295

Skeletal Radiol (2004) 33:596–600

Figures 3 and 4 and their legends were unfortunately omitted in the course of printing. They are reproduced here:

Fig. 3 Coronal **A** and axial **B** 3-mm CT images demonstrate calcification in the humeral head and erosion of the humeral head cortex. Extraosseous calcification has distribution of a “comet tail” suggesting distribution in the shape of a tendon (*arrow*). There is no soft tissue mass

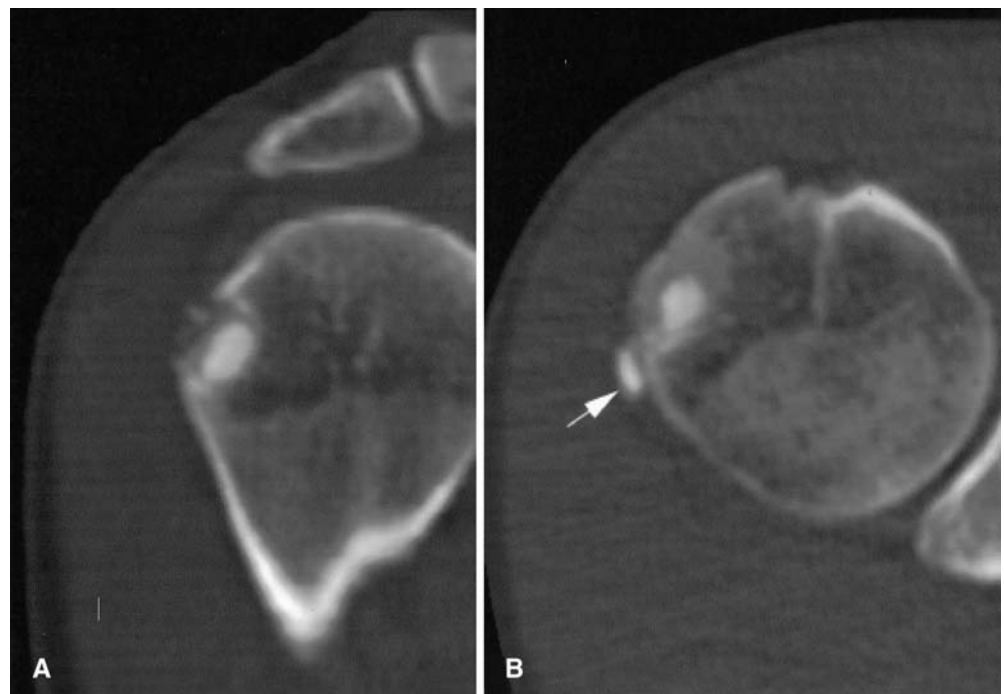


Fig. 4 Hematoxylin and eosin stain ($\times 100$) demonstrating typical deposits of calcific tendinitis within soft tissue and invading into bone. **B** Von Kossa stain ($\times 200$) highlights calcific deposits (*black*) in soft tissue

