

M. Renard
J. Simonet
P. Bencteux
P. Raynaud
N. Biga
J. Thiébot

Intermittent dislocation of the flexor hallucis longus tendon

Published online: 2 September 2003
© ISS 2003

The online version of the original article
can be found at <http://dx.doi.org/10.1007/s00256-002-0582-0>

M. Renard (✉) · J. Simonet · P. Bencteux
P. Raynaud · J. Thiébot
Department of Radiology,
University Hospital-Charles Nicolle,
1 rue de Germont, 76031 Rouen cedex,
France,
e-mail: Jacques.Thiebot@chu-rouen.fr

N. Biga
Department of Orthopaedic Surgery,
University Hospital-Charles Nicolle,
1 rue de Germont, 76031 Rouen cedex,
France,

Skeletal Radiol (2003) 32:78–81

In the above article the legend to Fig. 1 C should read as follows:

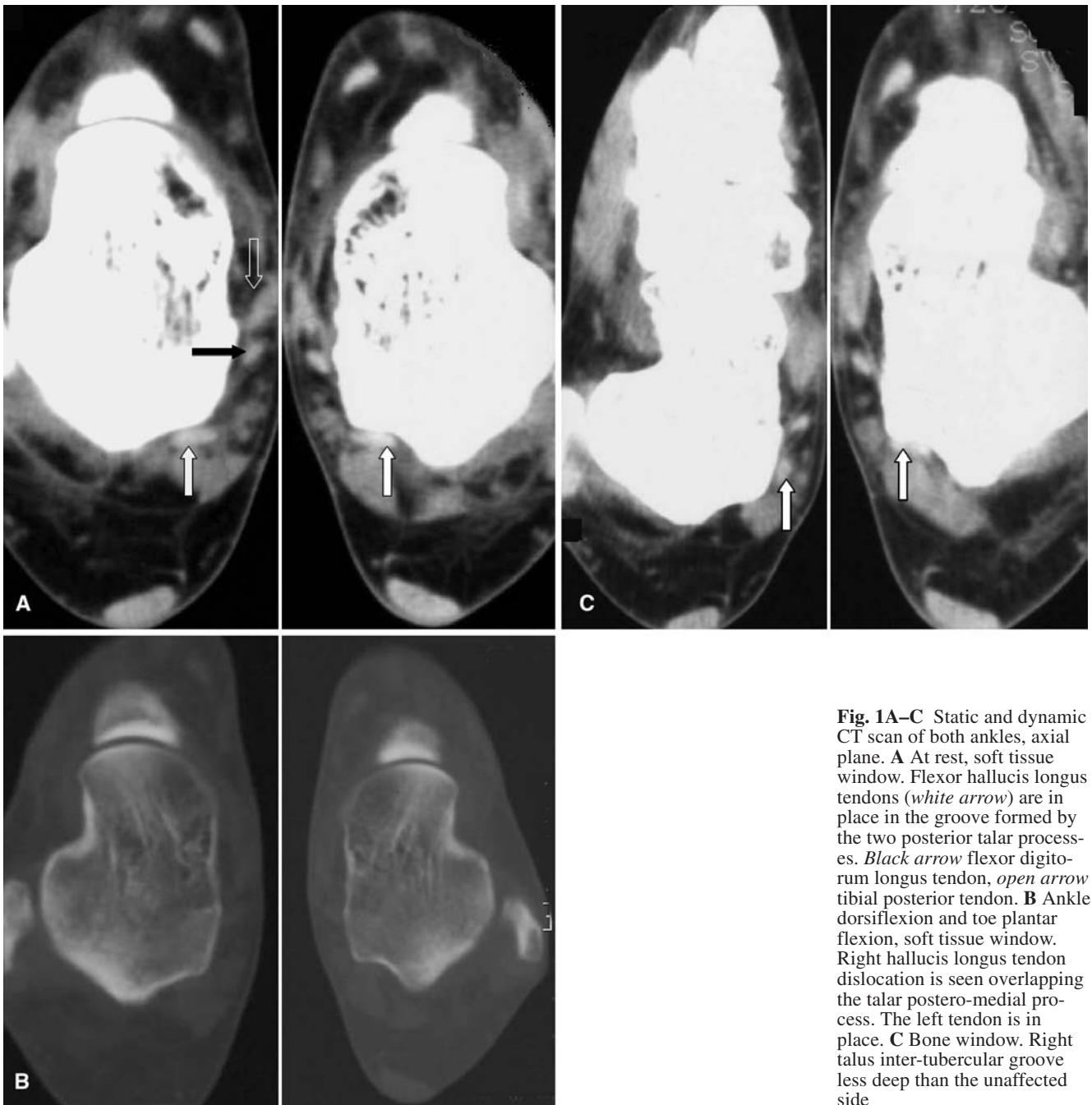


Fig. 1A–C Static and dynamic CT scan of both ankles, axial plane. **A** At rest, soft tissue window. Flexor hallucis longus tendons (*white arrow*) are in place in the groove formed by the two posterior talar processes. *Black arrow* flexor digitorum longus tendon, *open arrow* tibial posterior tendon. **B** Ankle dorsiflexion and toe plantar flexion, soft tissue window. Right hallux longus tendon dislocation is seen overlapping the talar postero-medial process. The left tendon is in place. **C** Bone window. Right talus inter-tubercular groove less deep than the unaffected side