

K. Nedeltchev  
L. Remonda  
D.-D. Do  
C. Brekenfeld  
C. Ozdoba  
M. Arnold  
H. P. Mattle  
G. Schroth

## Acute stenting and thromboaspiration in basilar artery occlusions due to embolism from the dominating vertebral artery

Published online: 20 November 2004  
© Springer-Verlag 2004

**Neuroradiology (2004)  
46:686–691**

In the original online publication of this article, Fig. 2d was unfortunately omitted. Fig. 2d documents the thrombembolic material which was aspirated out of the occluded basilar artery using the Tracker 38 catheter.

The online version of the original article can be found at <http://dx.doi.org/10.1007/s00234-004-1217-z>

K. Nedeltchev · L. Remonda  
C. Brekenfeld · C. Ozdoba  
G. Schroth (✉)  
Institute of Diagnostic and Interventional  
Neuroradiology, University of Bern,  
Inselspital, Freiburgstrasse 4,  
3010 Bern, Switzerland  
E-mail: Gerhard.Schroth@insel.ch  
Tel.: +41-31-6322654  
Fax: +41-31-6324872

D.-D. Do  
Institute of Angiology, University of Bern,  
Inselspital, Bern, Switzerland

M. Arnold · H. P. Mattle  
Department of Neurology,  
University of Bern, Inselspital,  
Bern, Switzerland

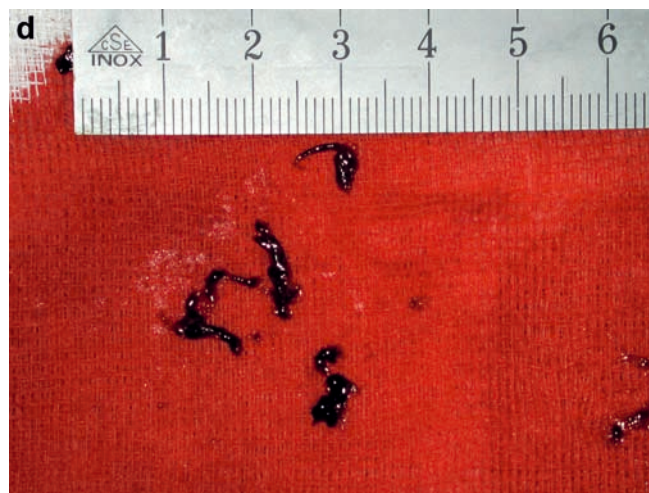


Fig. 2d